


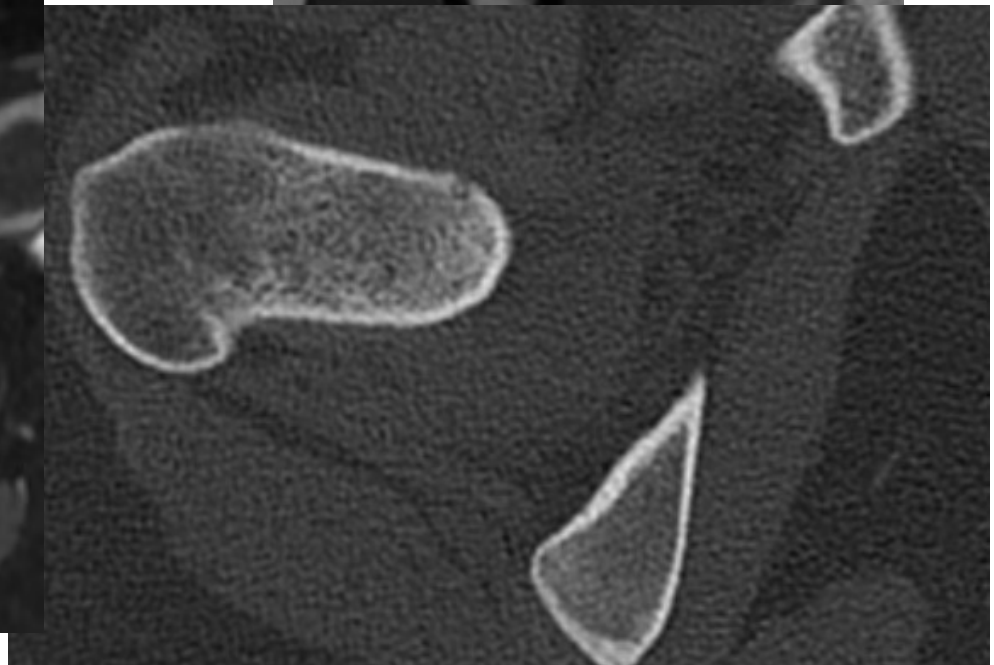
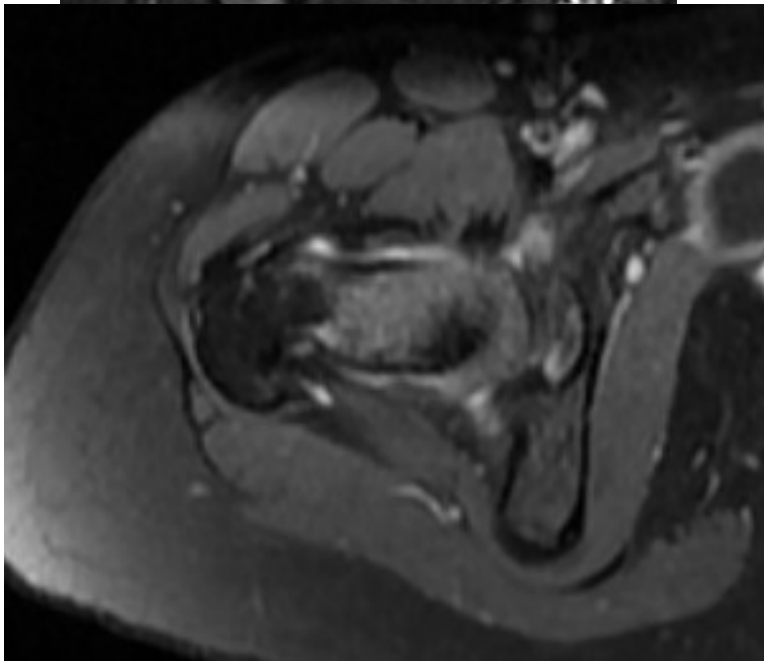
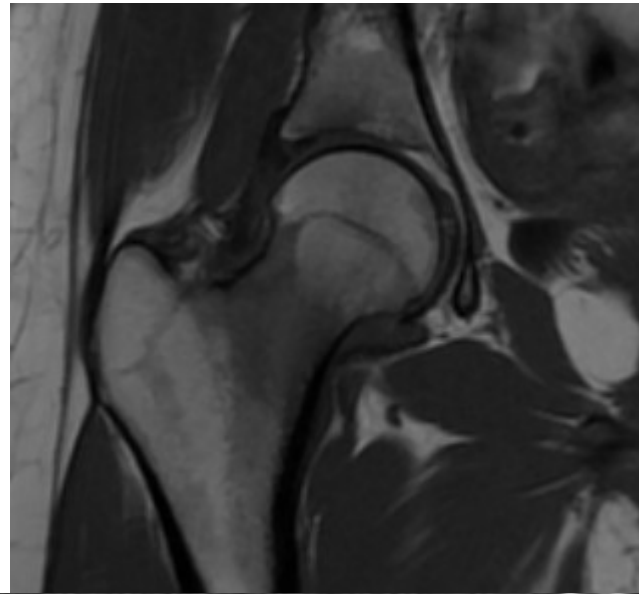
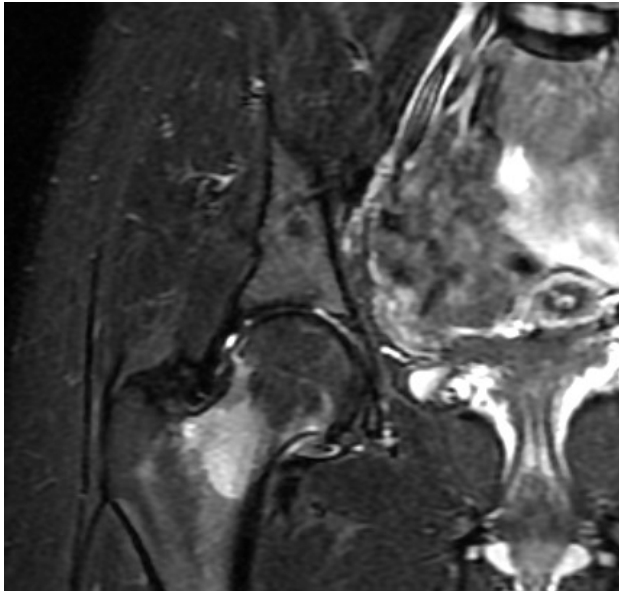


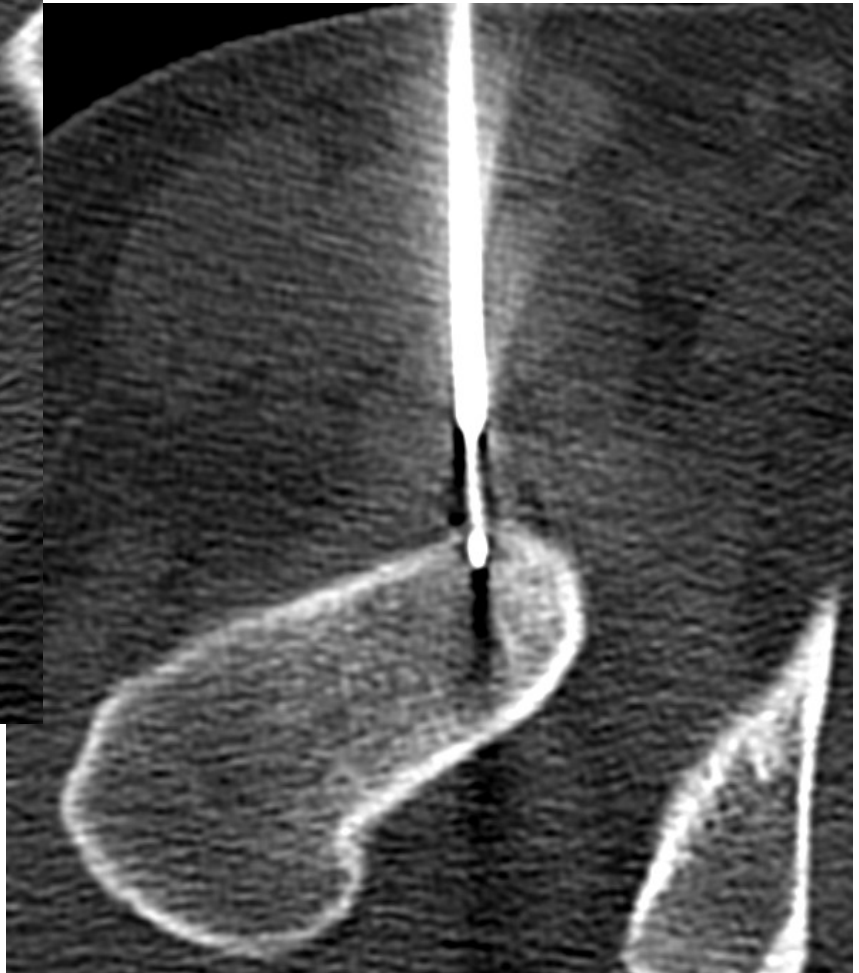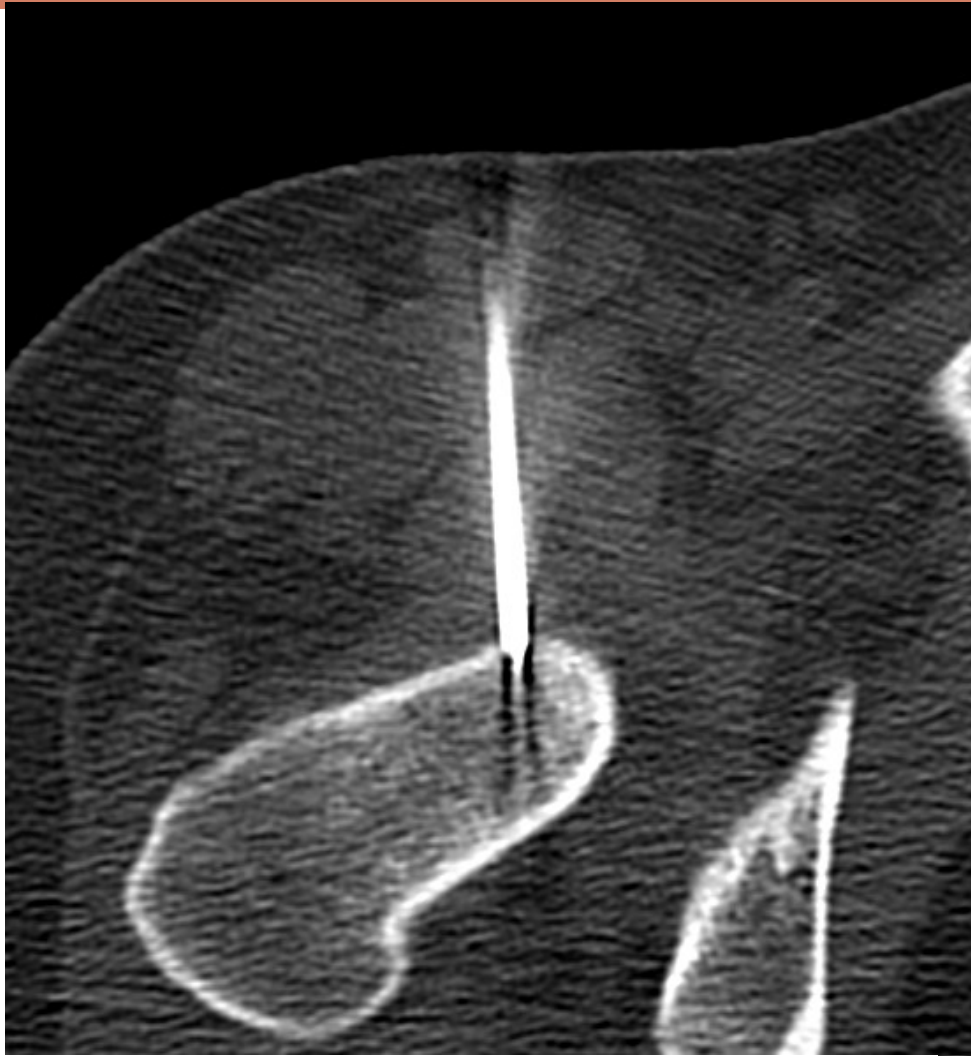IMAGERIE DE SUIVI DES TRAITEMENTS PERCUTANÉS

Cas Clinique

Dr Cuinet, Dr Kalendarian, Pr Pilleul, Dr Mastier, Dr Bouhamama, T.
Brunel

- 
- Jeune fille de 16 ans
 - Pas d'antécédents
 - Douleur de la racine de cuisse droite depuis 1 an
 - Accès nocturne, douleurs insomniantes
 - Calmées par l'aspirine

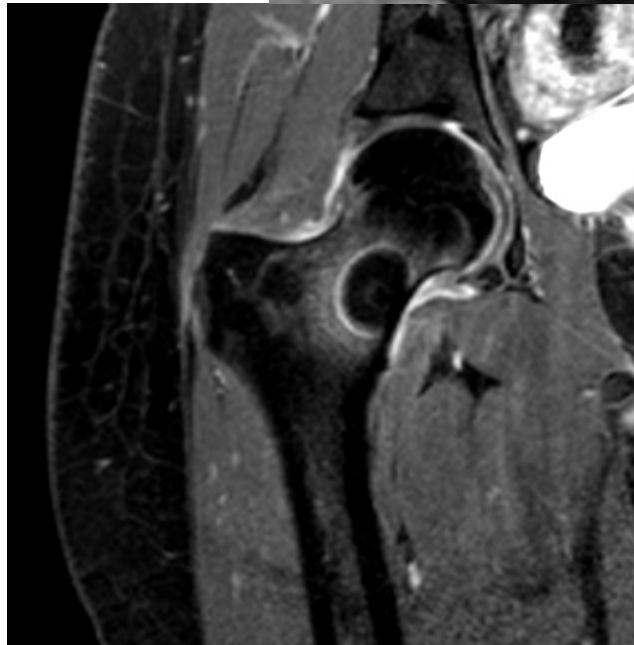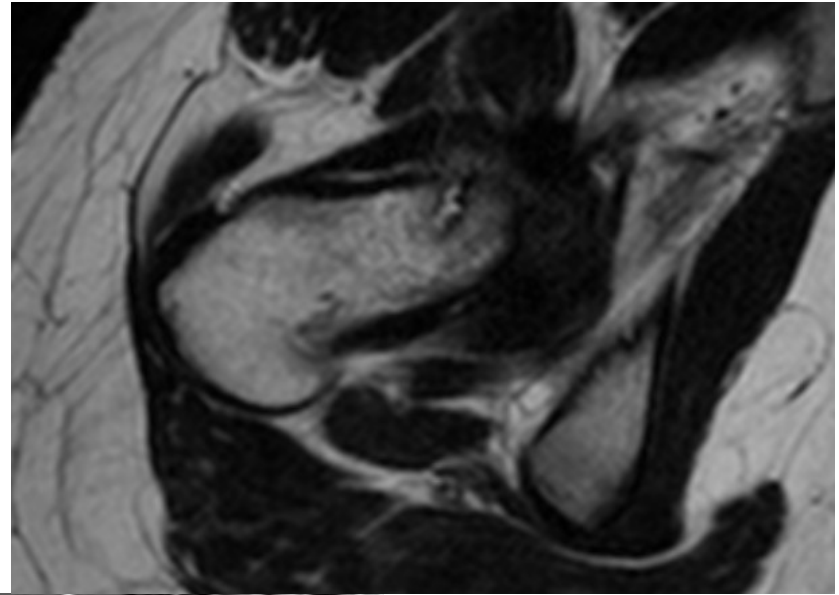
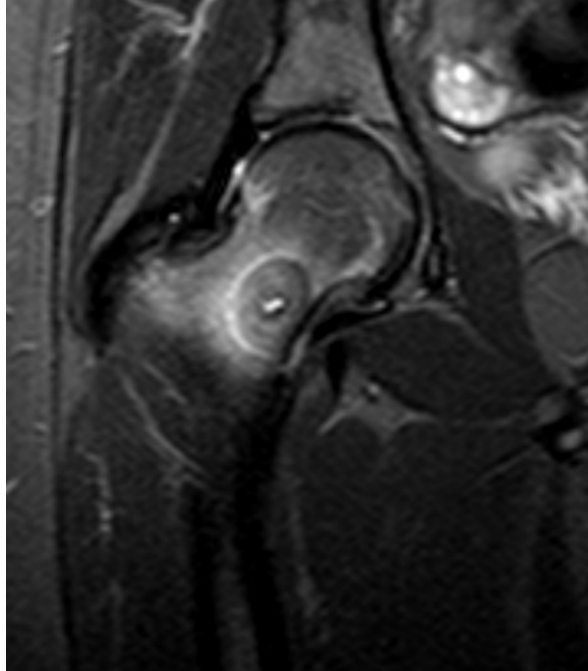






A 1 mois

- Disparition des douleurs insomniantes
- Cruralgies bilatérales
- Douleurs lombaires
- IRM de contrôle

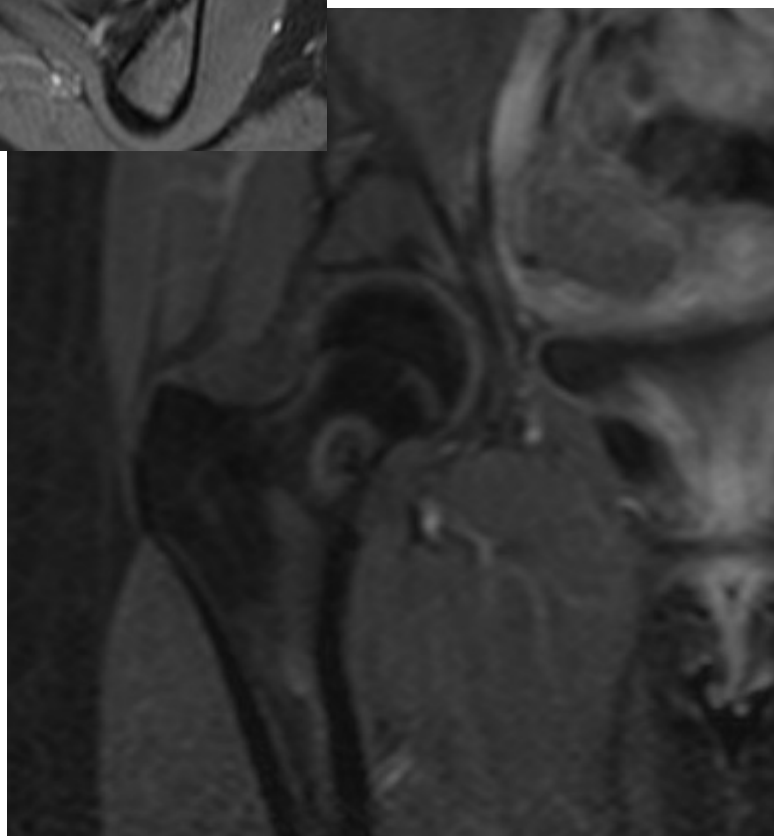
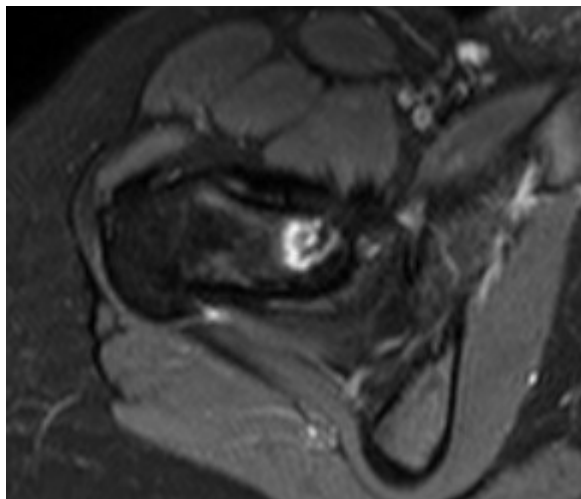
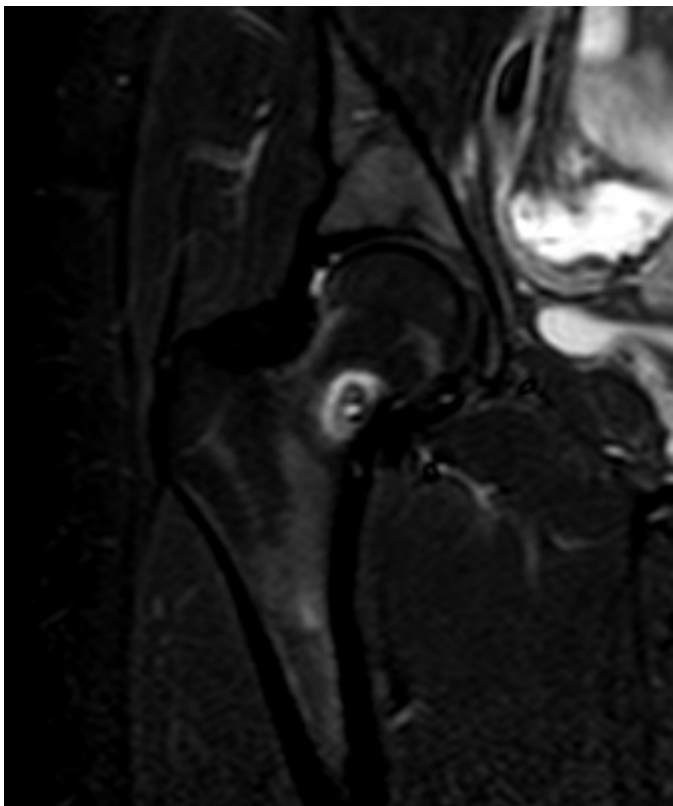




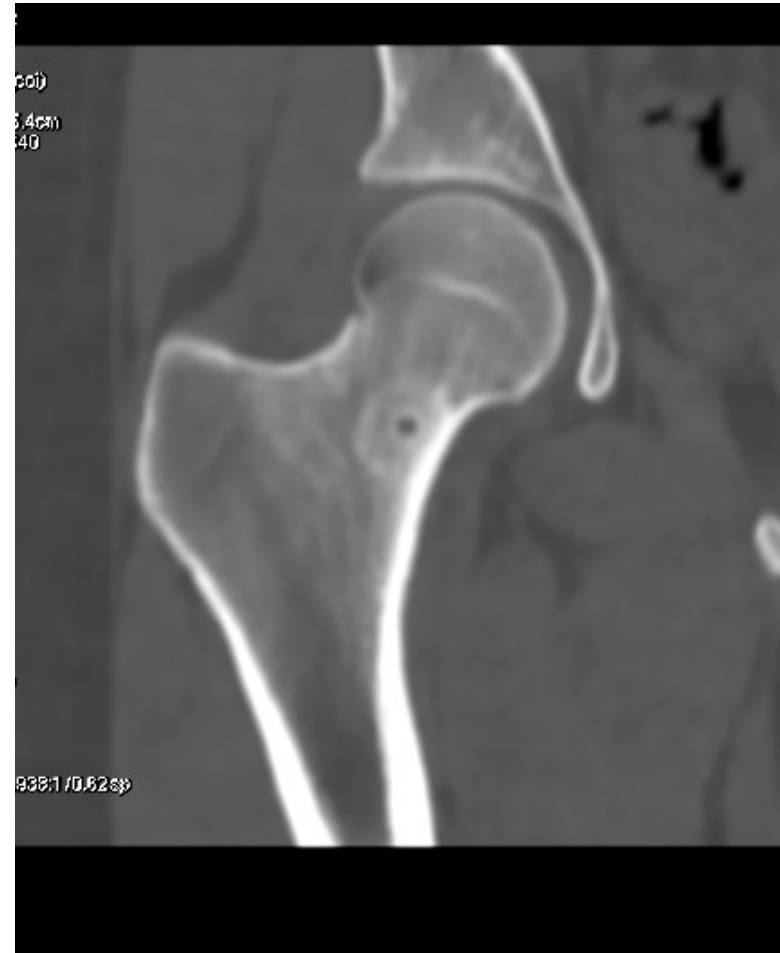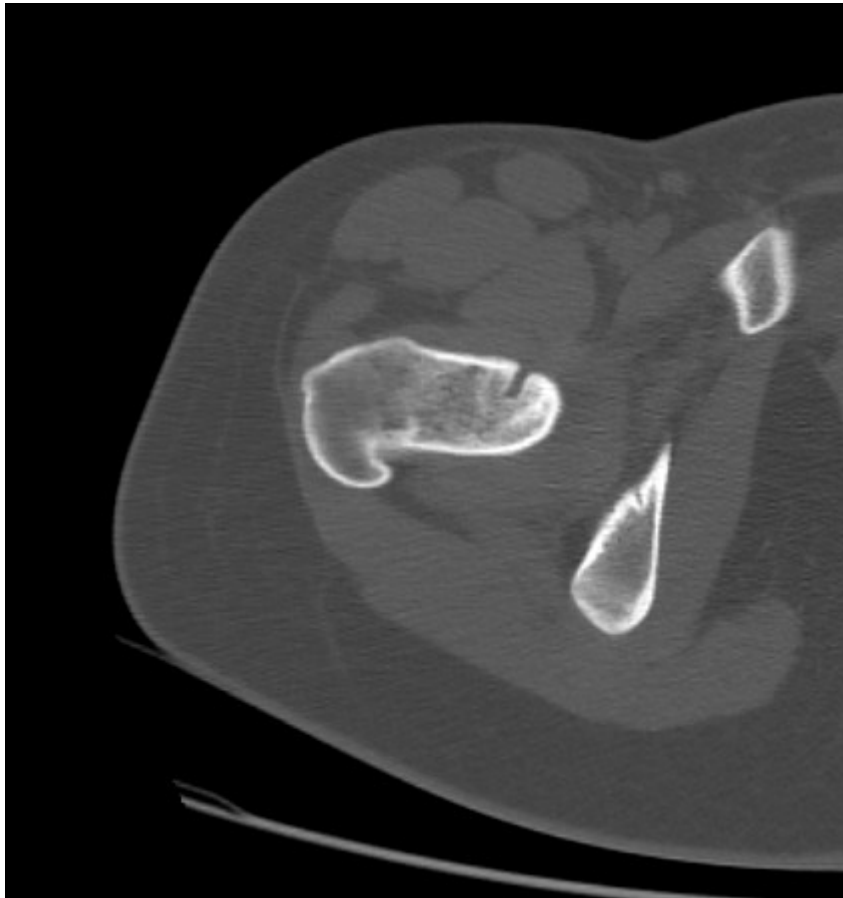
A un an

- Douleur bilatérale mécanique des hanches
- Lombalgies
- Pas de douleurs nocturnes


IRM



TDM



Angio IRM



Angio IRM

