

Bassin et Hanches

Philippe Tanji

Cas n° 1

- Robin F..... , 24 ans
- Contrat avec l'armée :
Chasseur Alpin
- Activité sportive de
loisir : course à pied

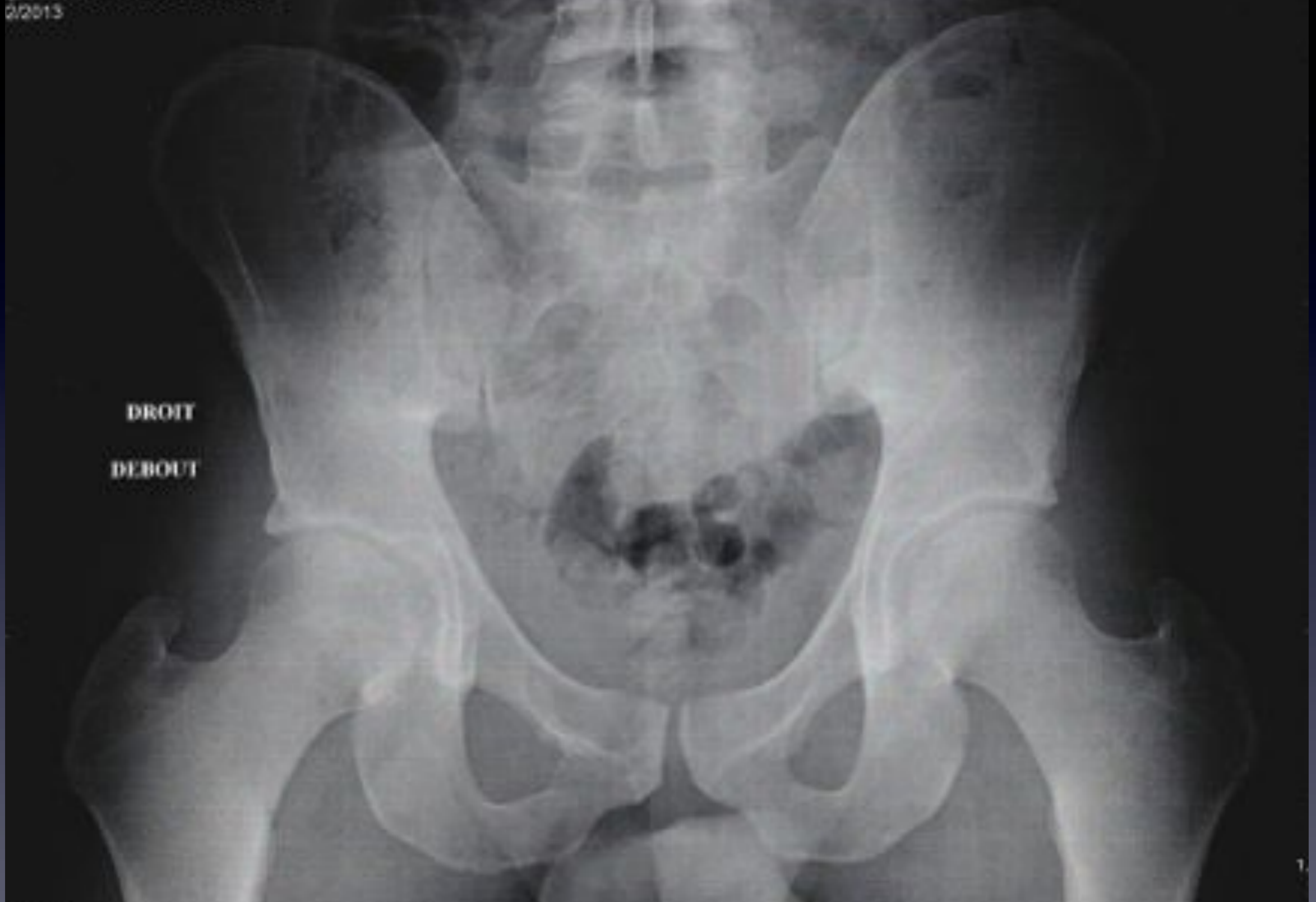- Première consultation : Mars 2013

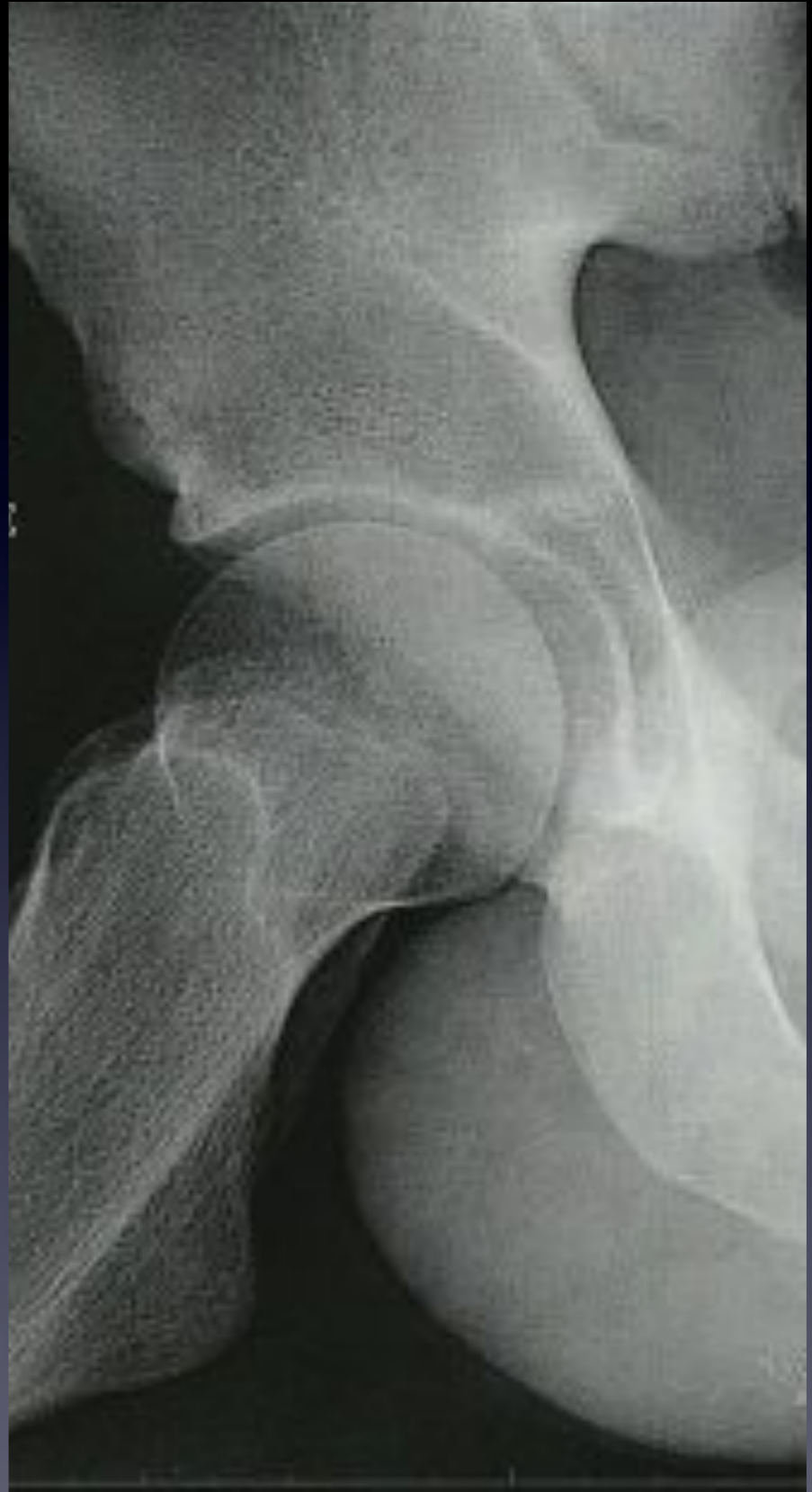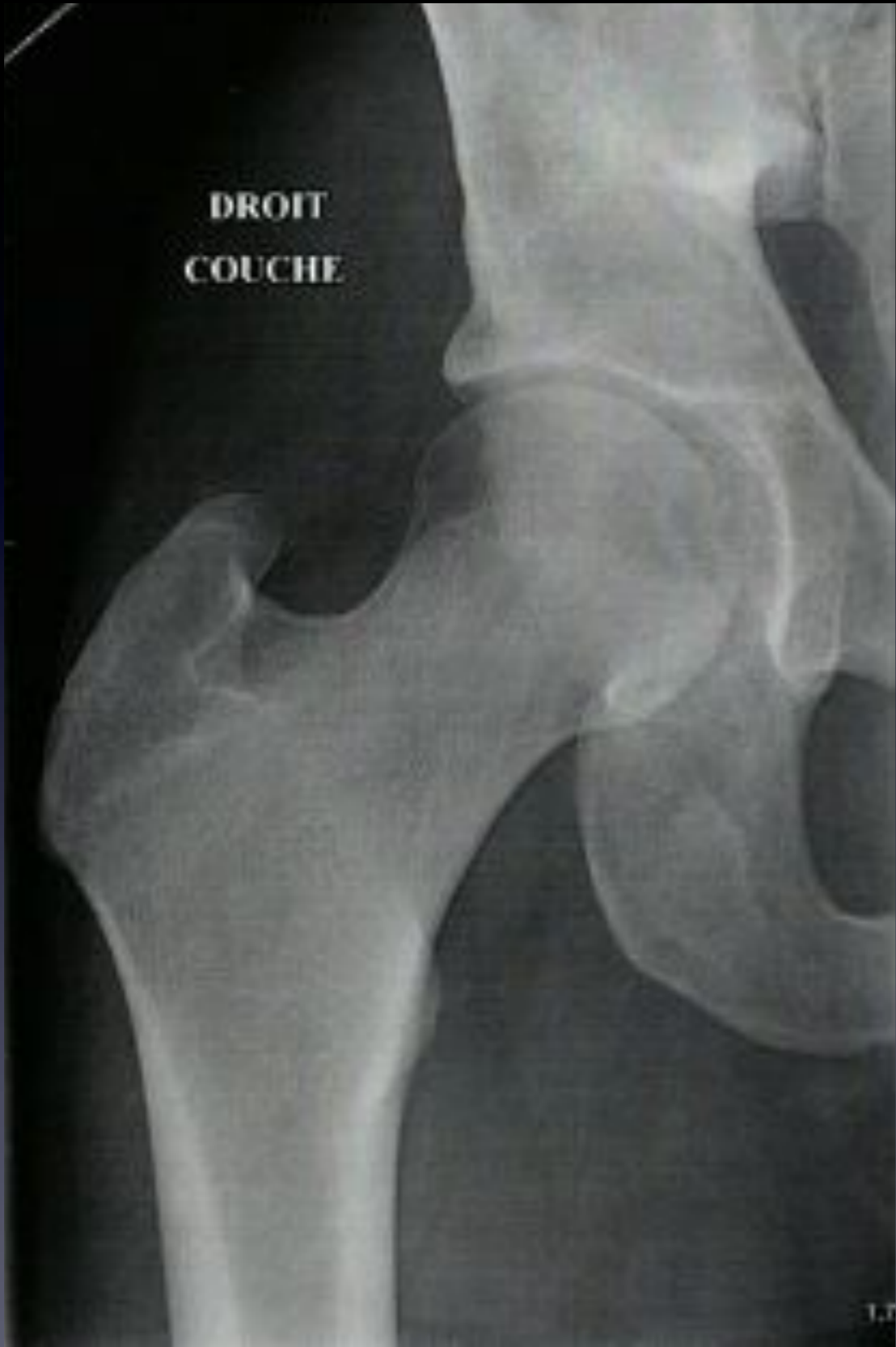- Douleur du pli de l'aîne droit depuis début Janvier 2013 , survenant à l'appui, sans notion traumatique, sans contexte d'hyperactivité
- Boiterie à la marche et limitation du périmètre de marche
- Gêne lombaire droite

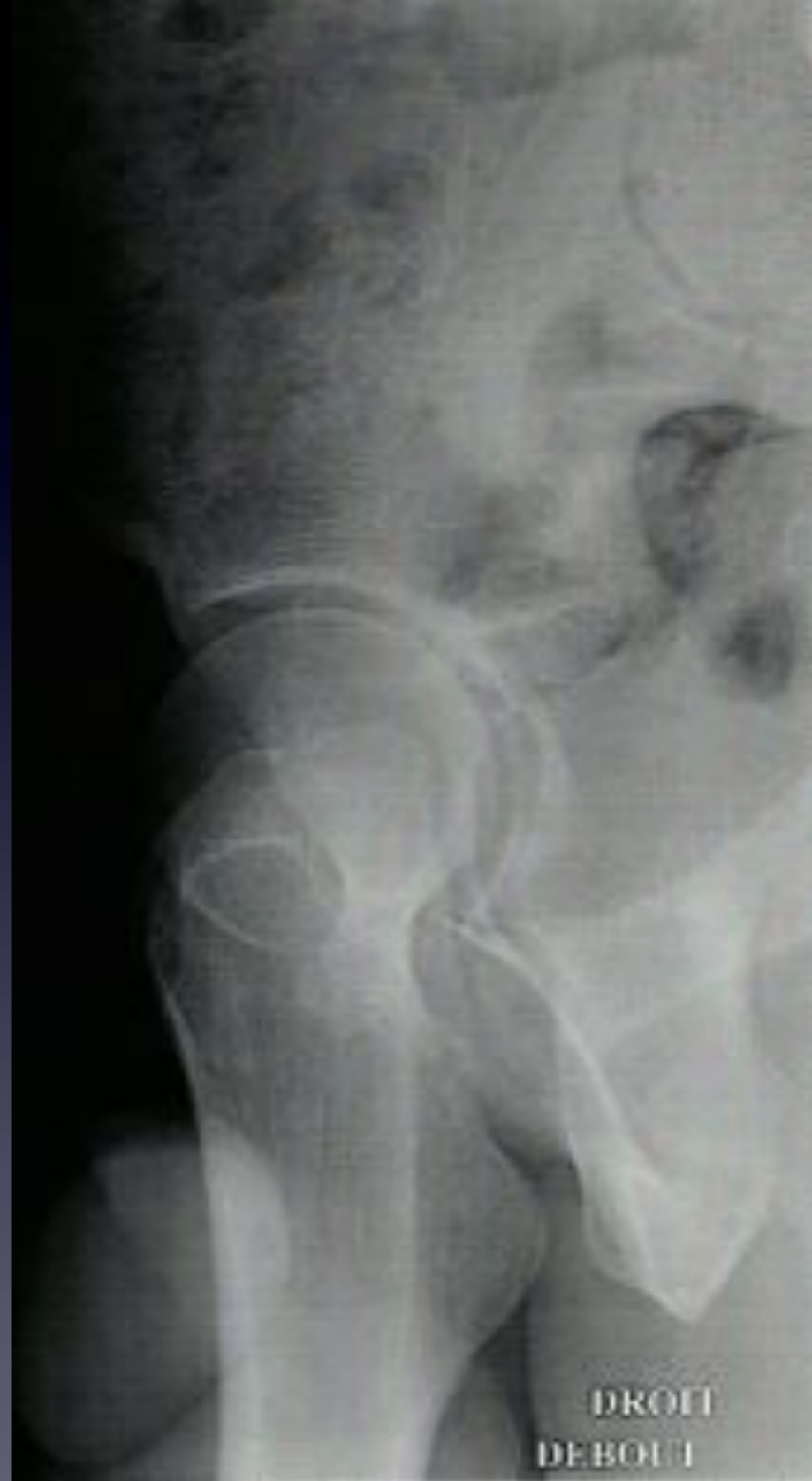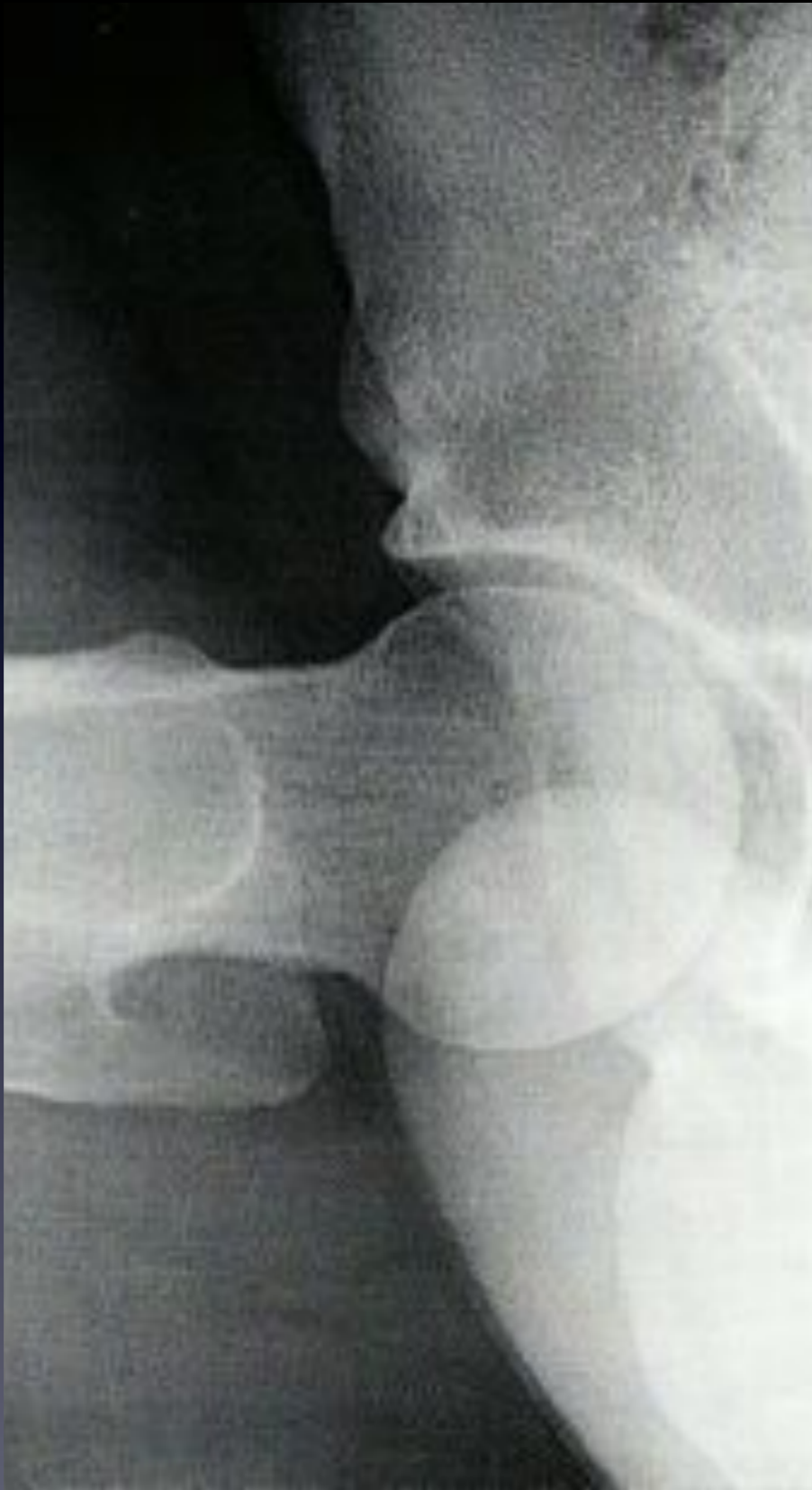- Examen clinique
 - Bassin équilibré
 - Amyotrophie modérée du quadriceps droit
 - Mobilité de hanche
 - ✓ FIE : 0 - 120 °
 - ✓ RI / RE 45°
 - ✓ Abd / Add 45 -60°
 - ✓ Adduction douloureuse

Radiographies Mars 2013

02013

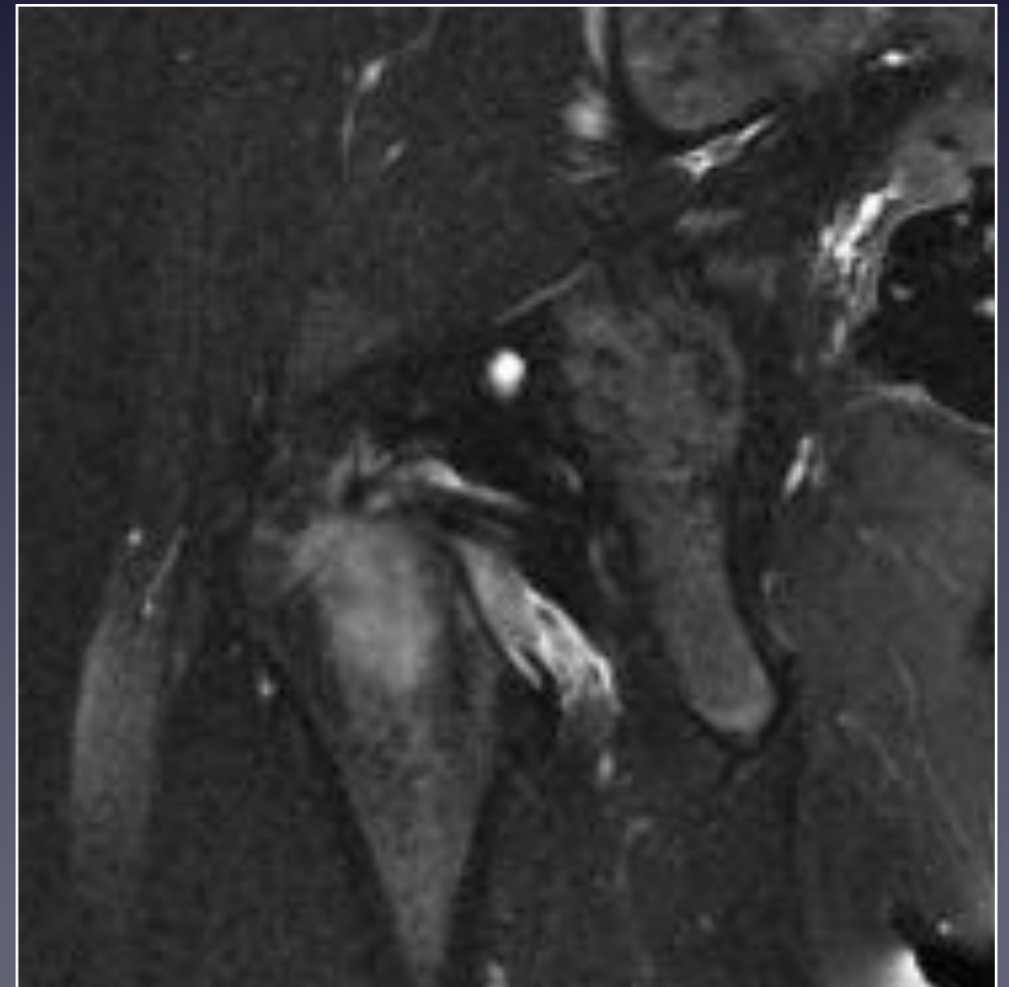
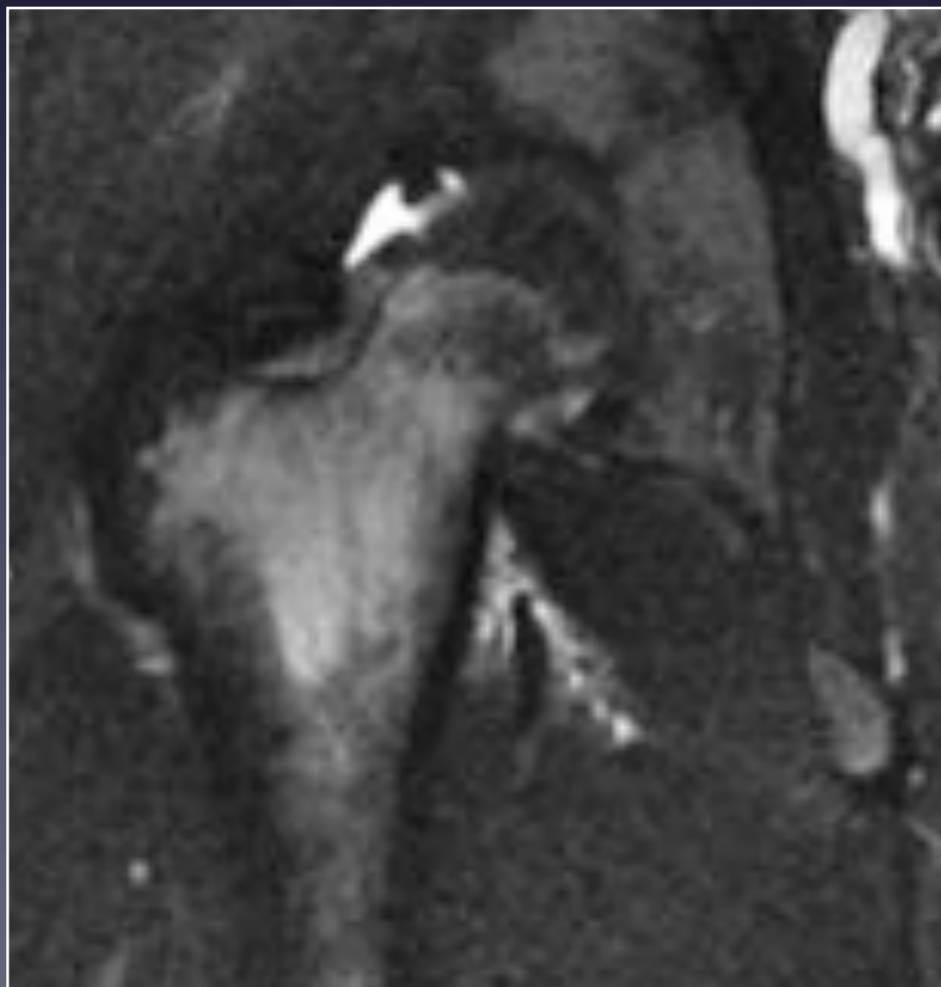
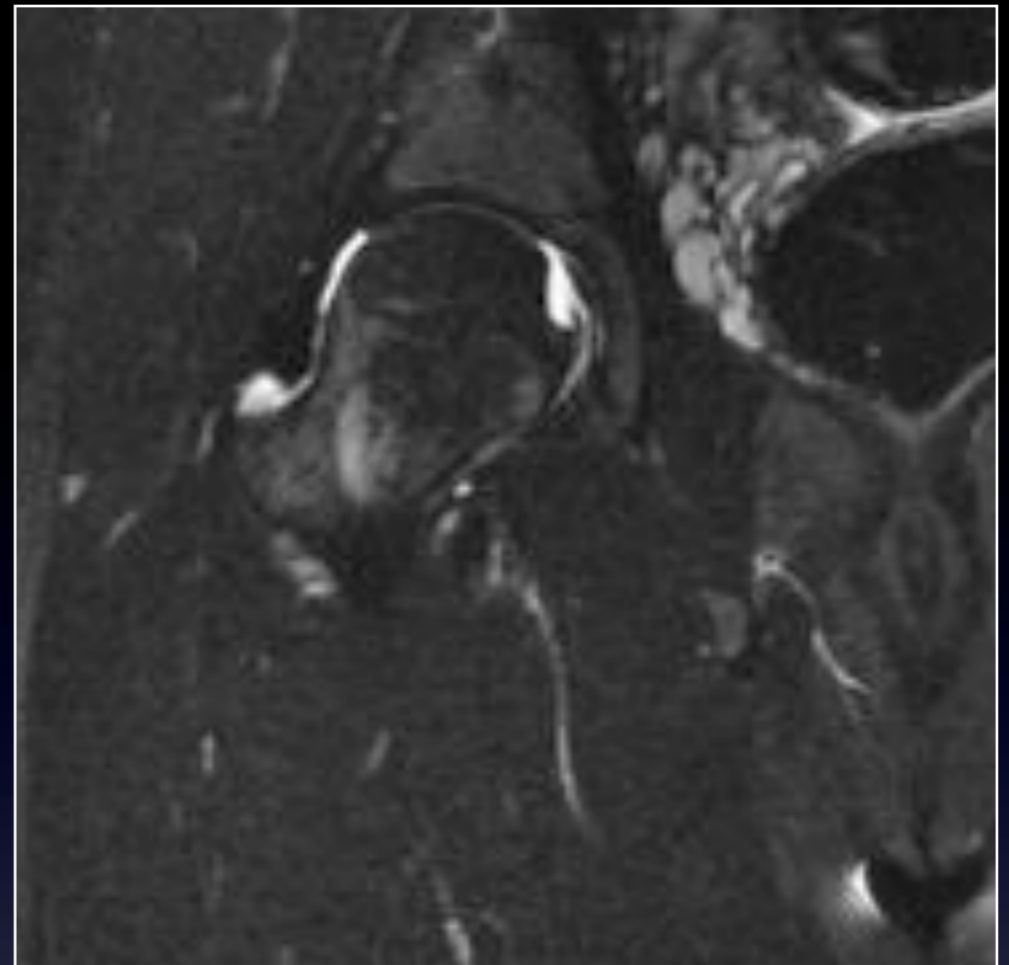
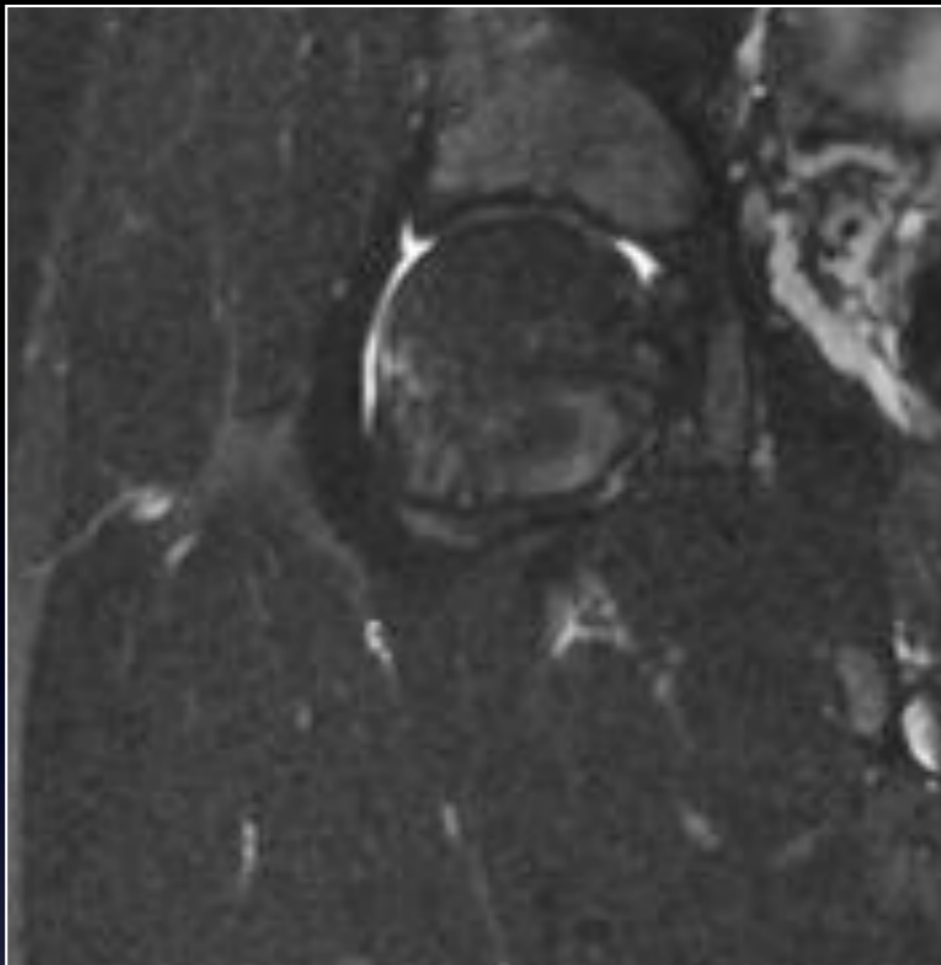




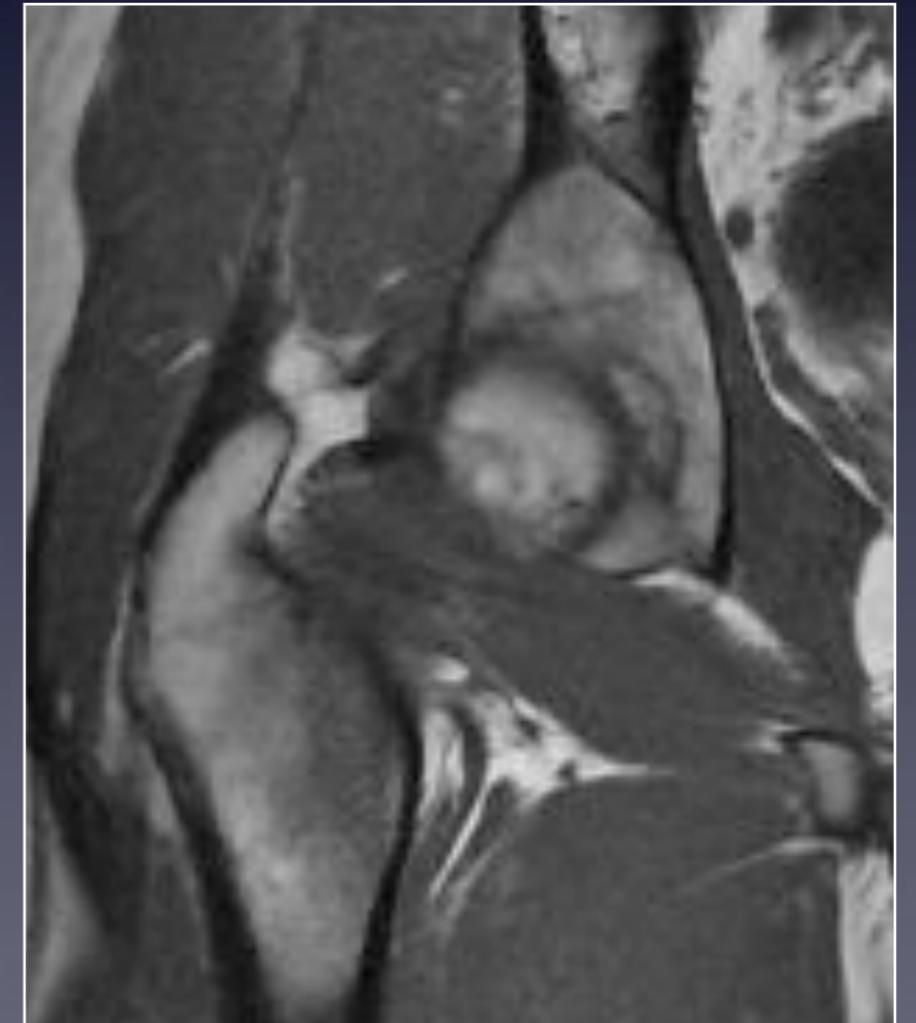
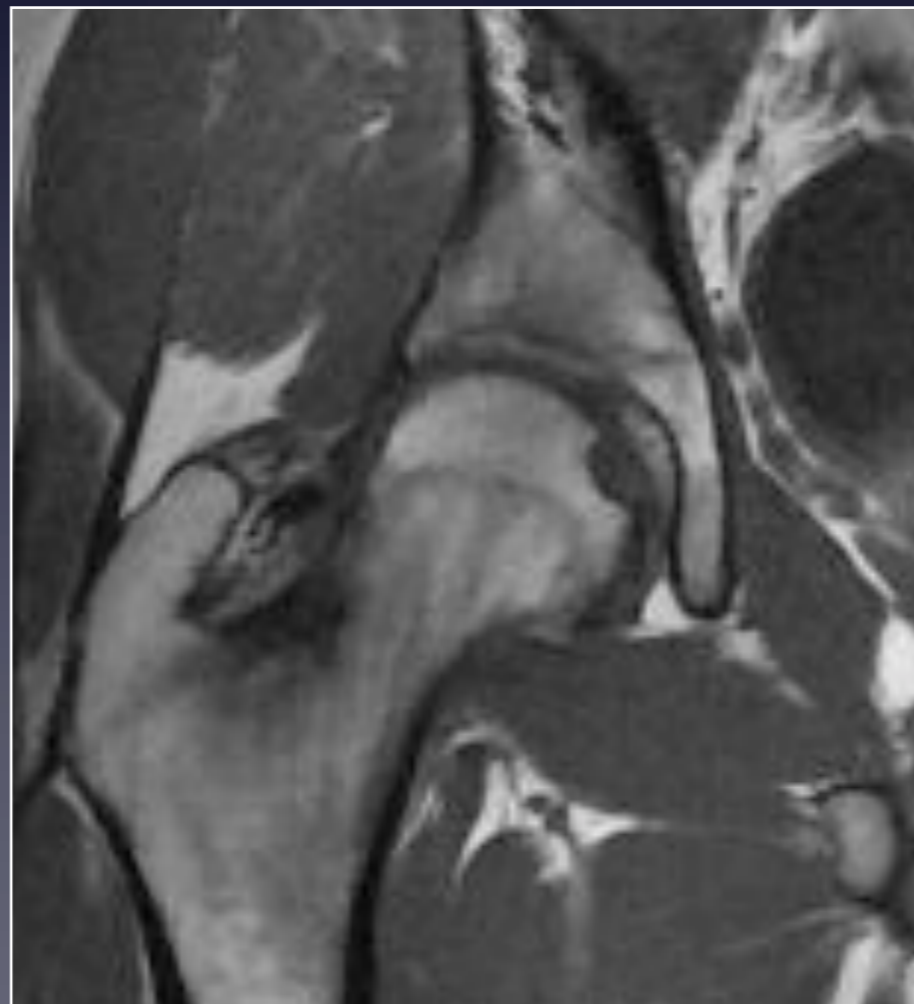
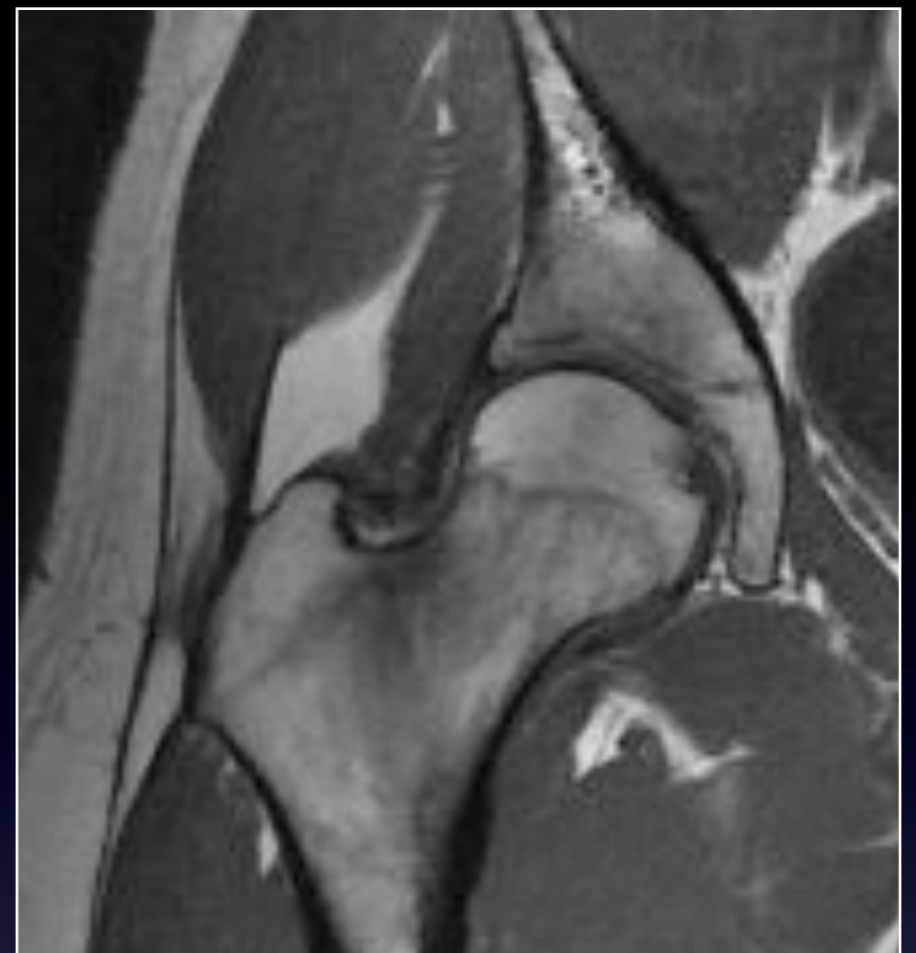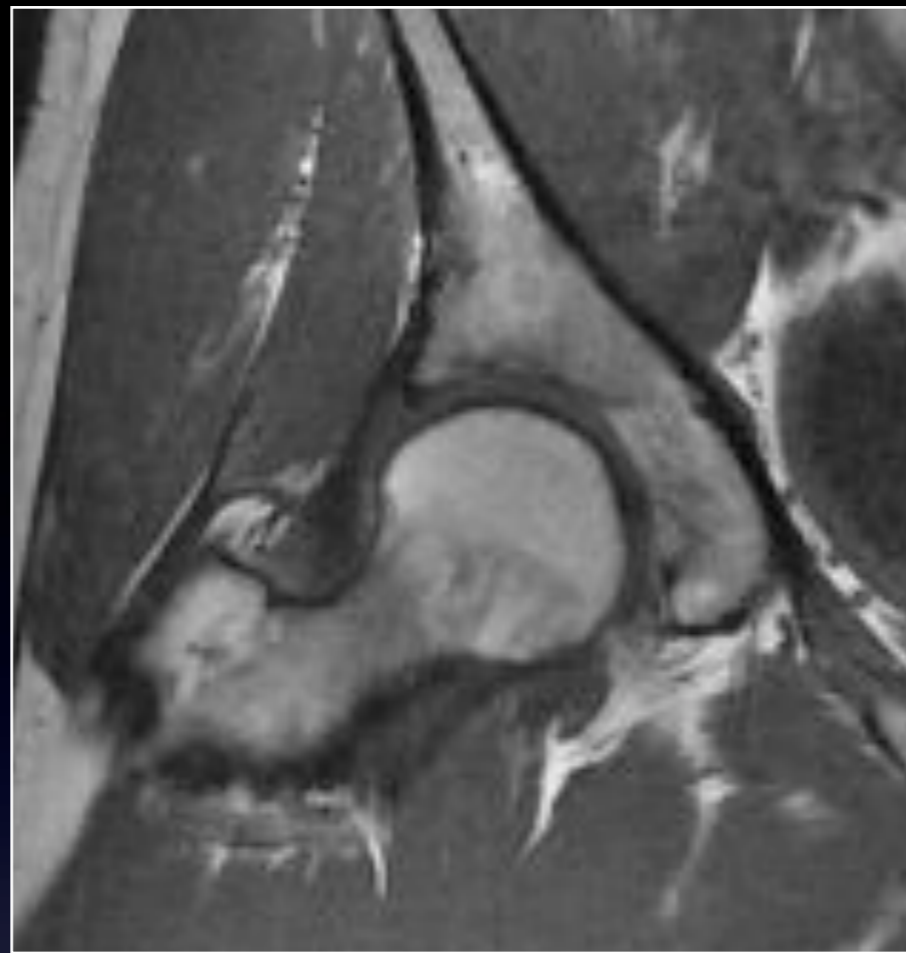


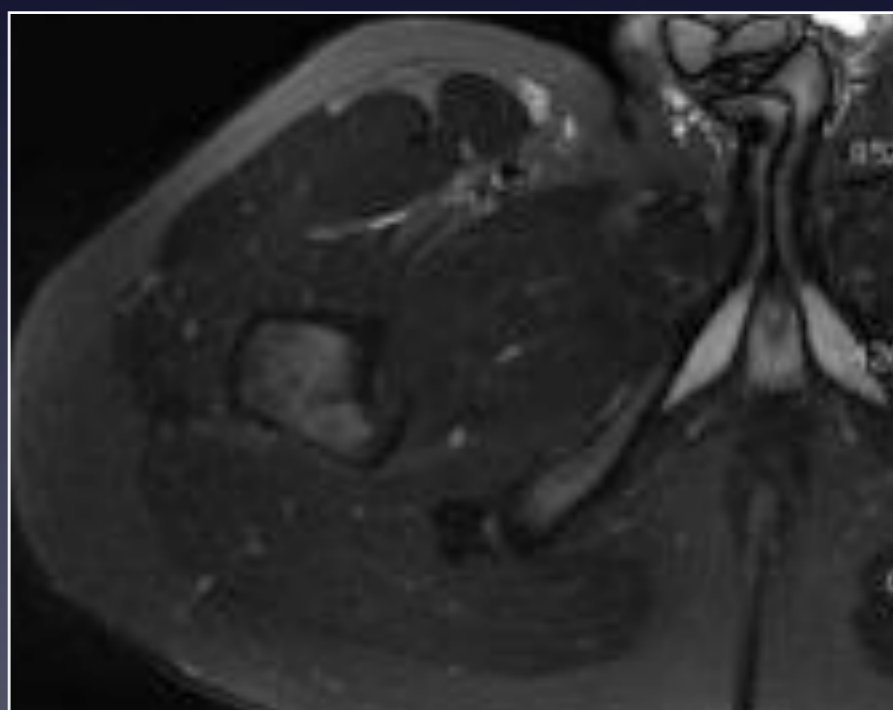
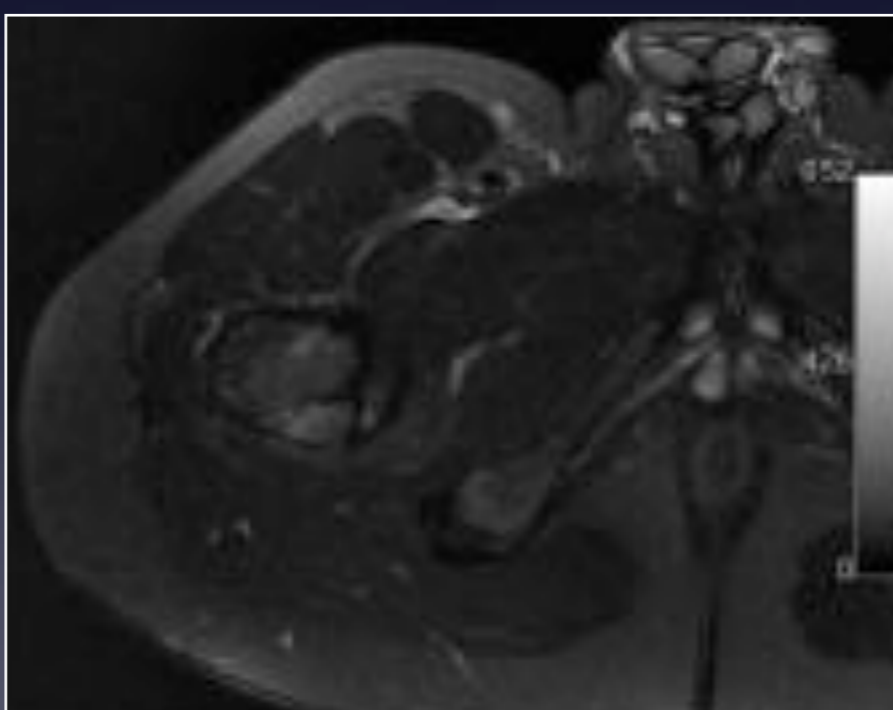
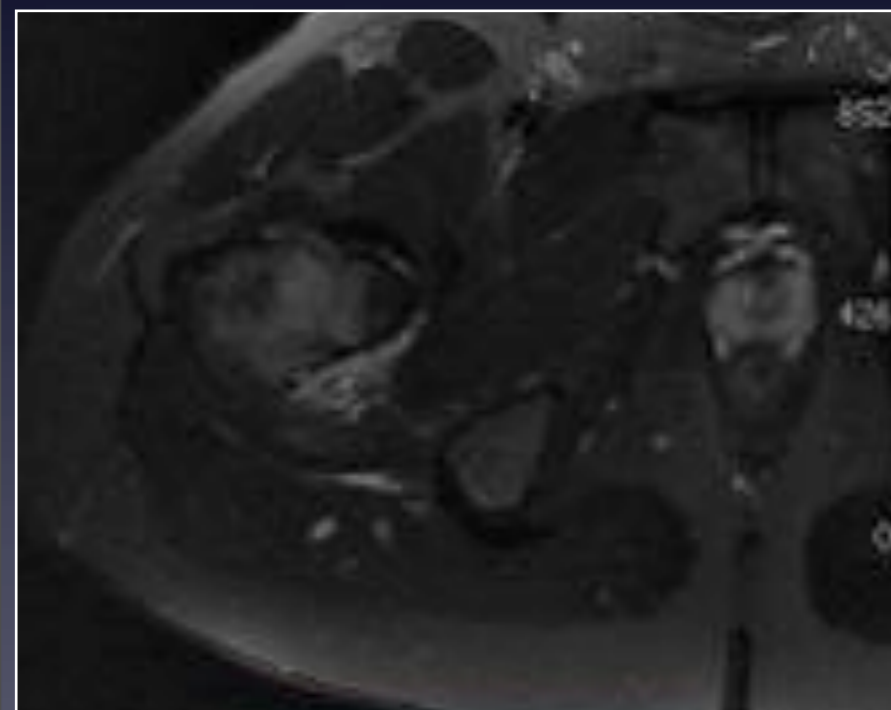
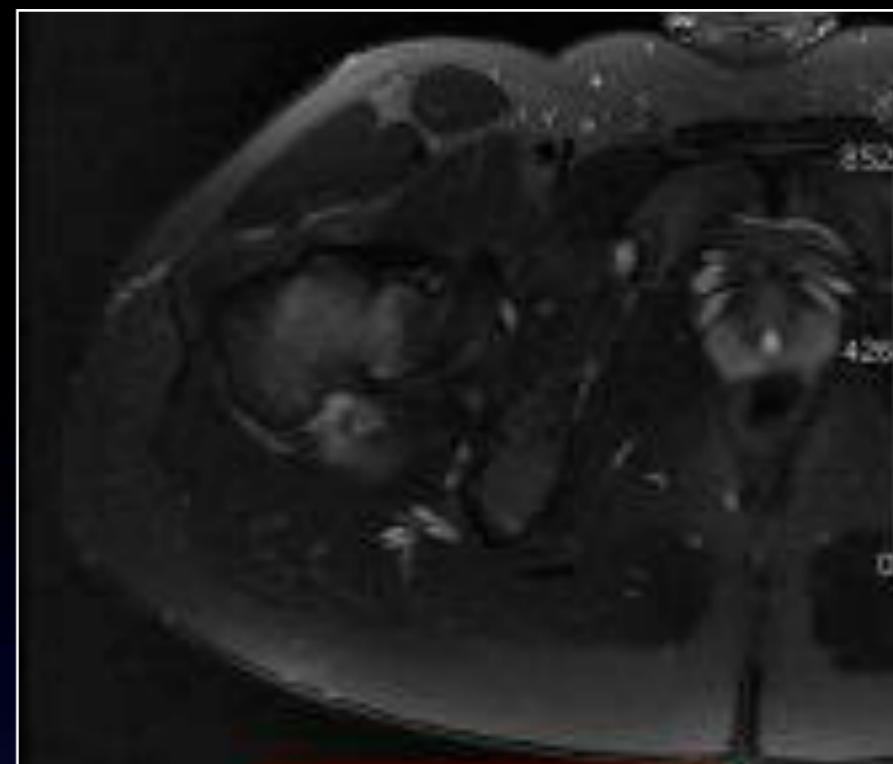
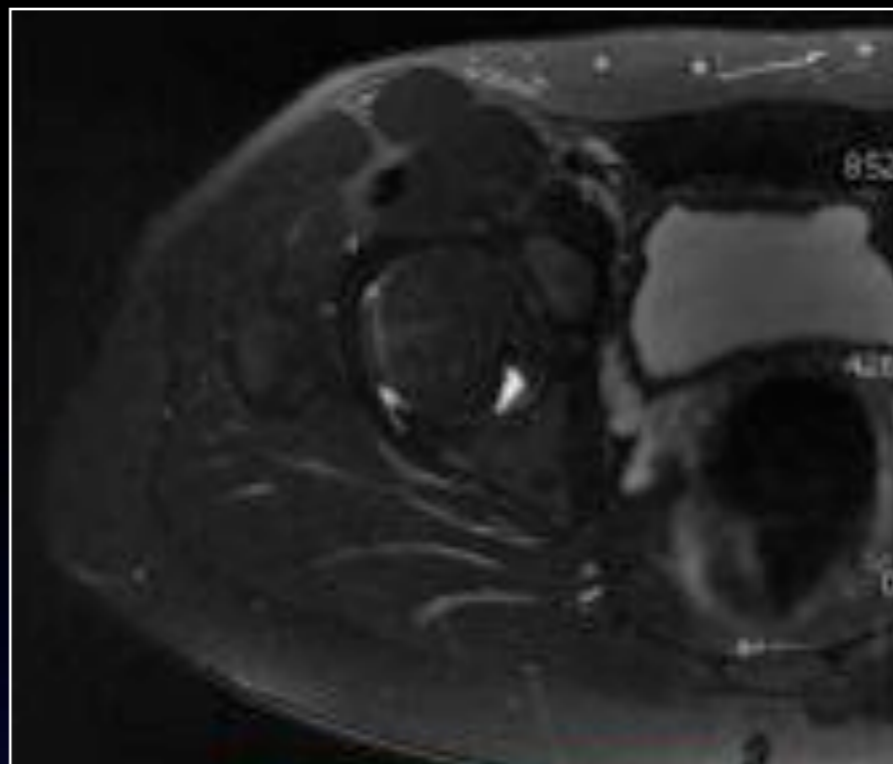
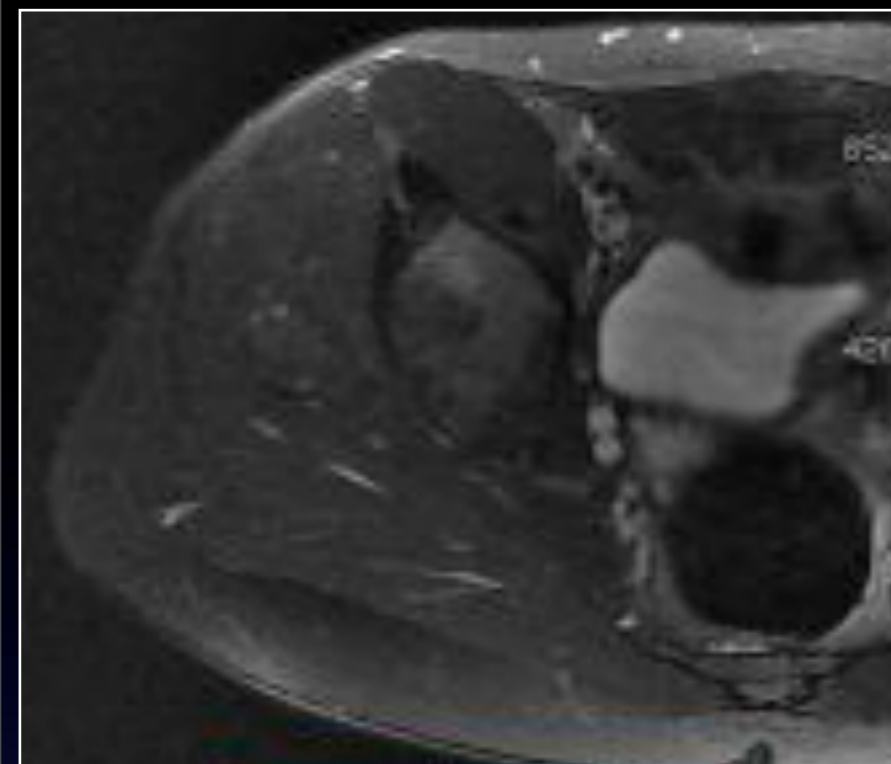
IRM Mars 2013

Coronal T2 Fat Sat

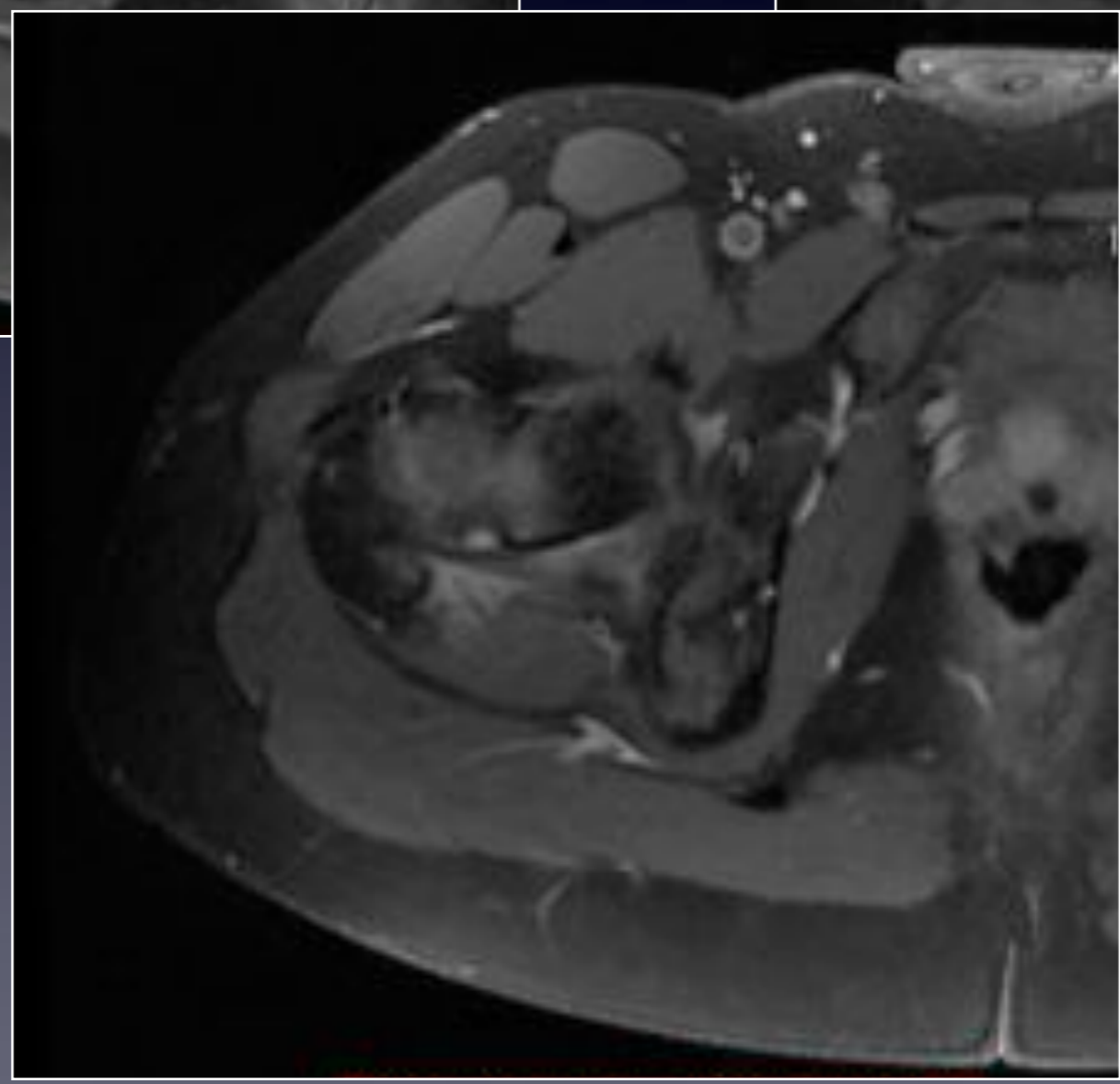
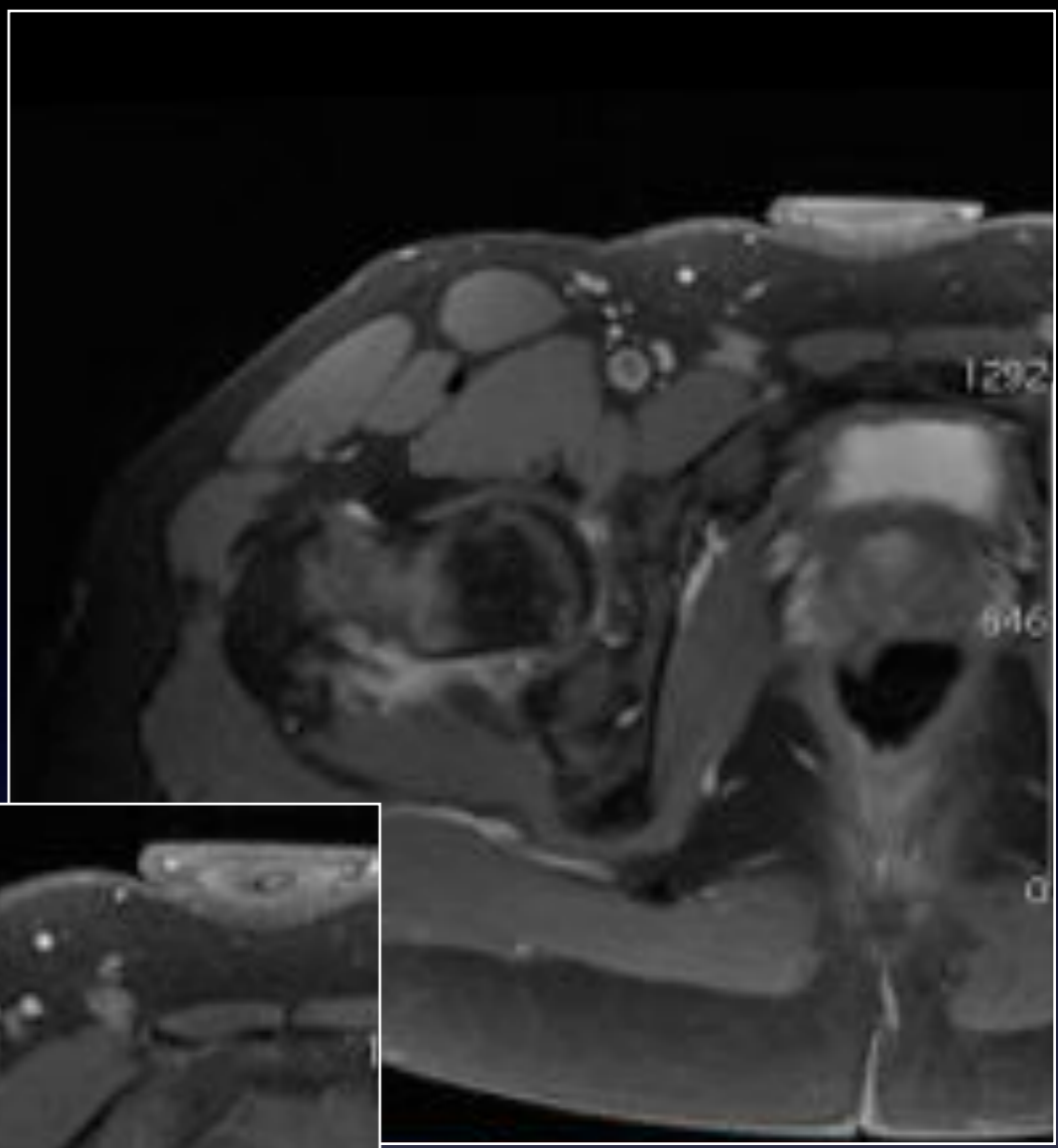
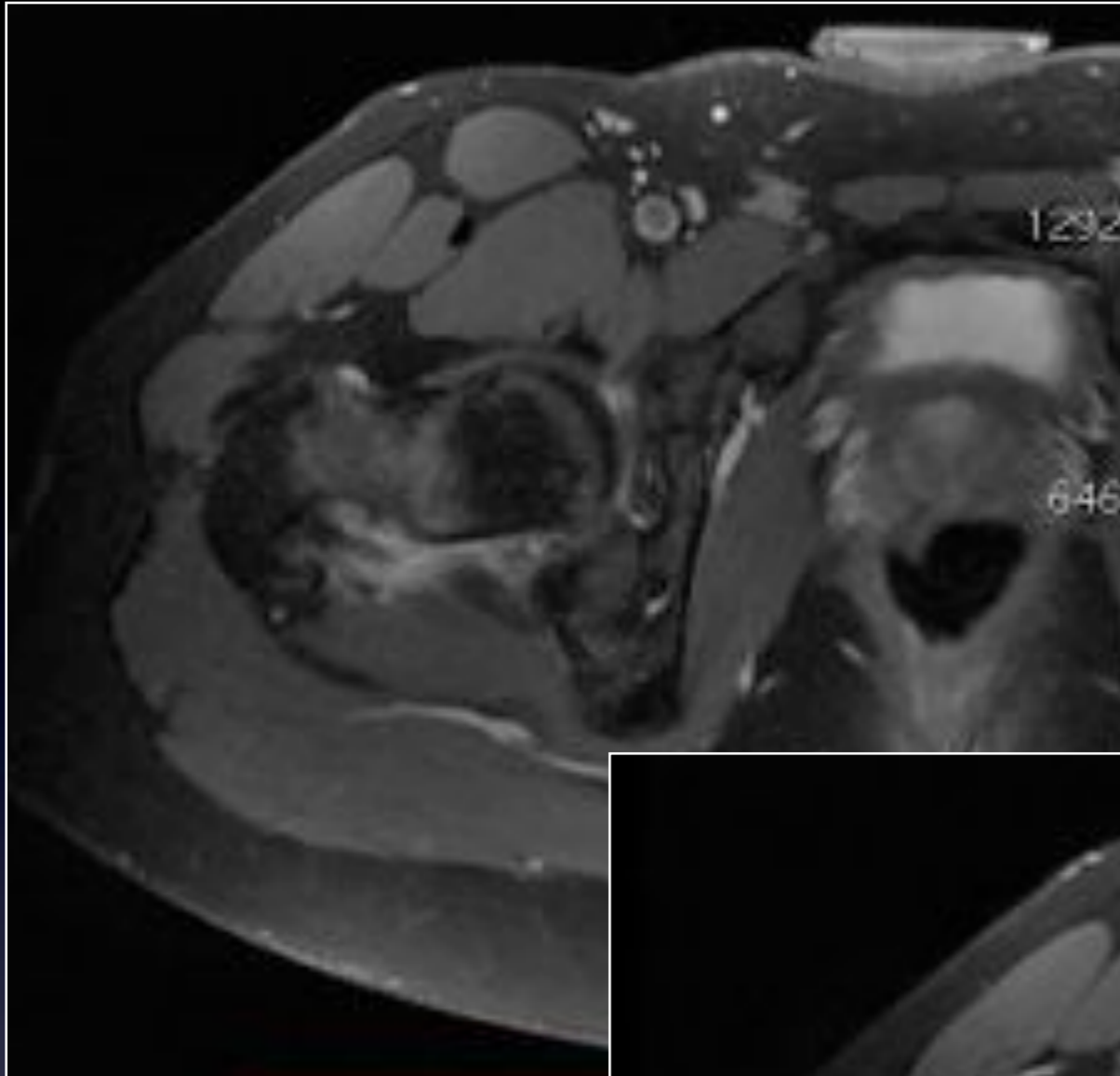


Coronal T1





Axial T2 Fat Sat

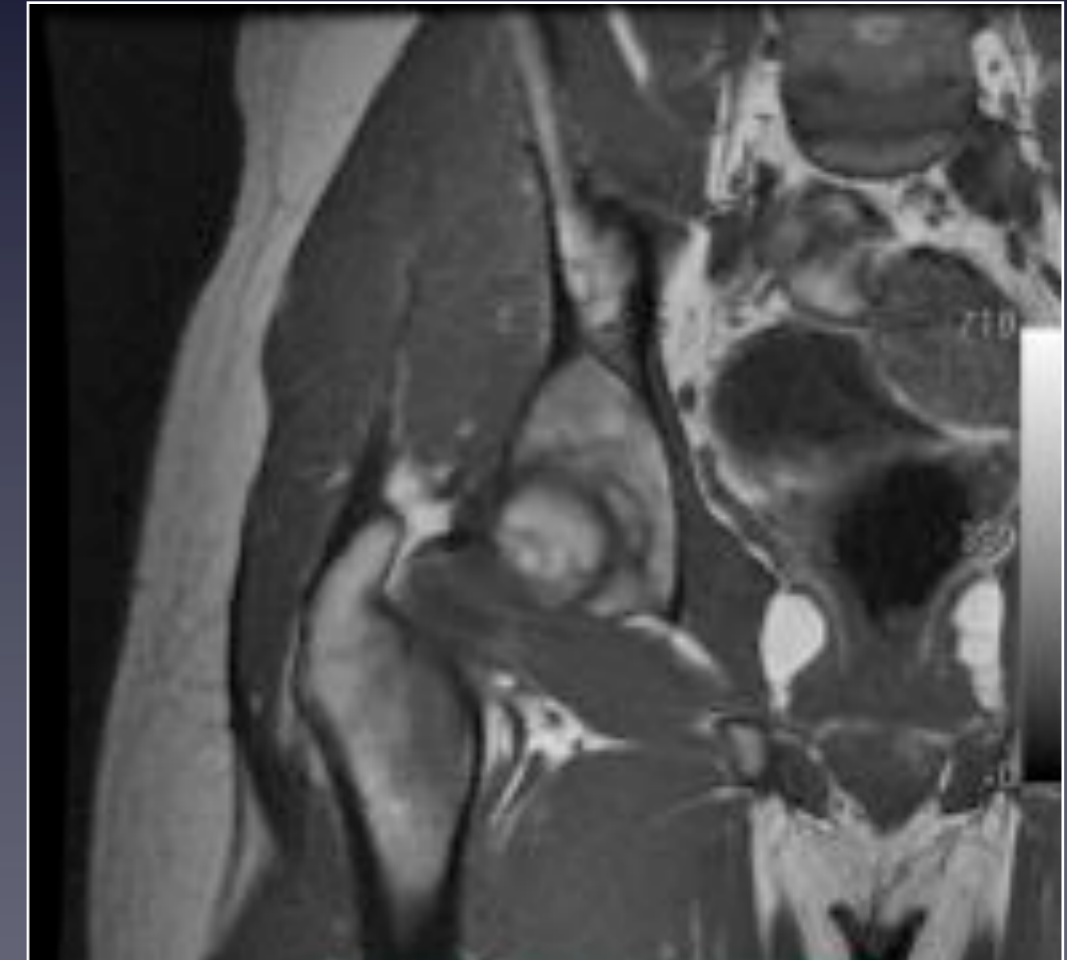
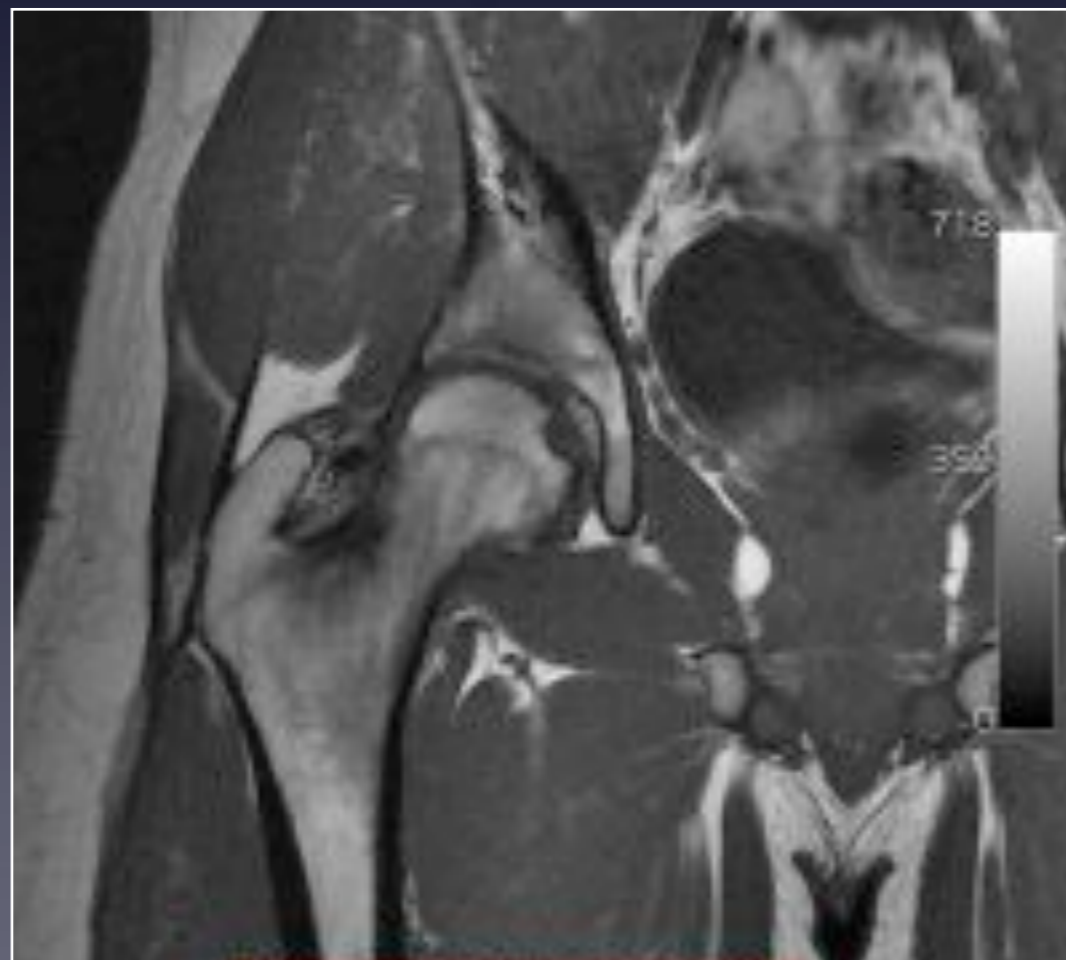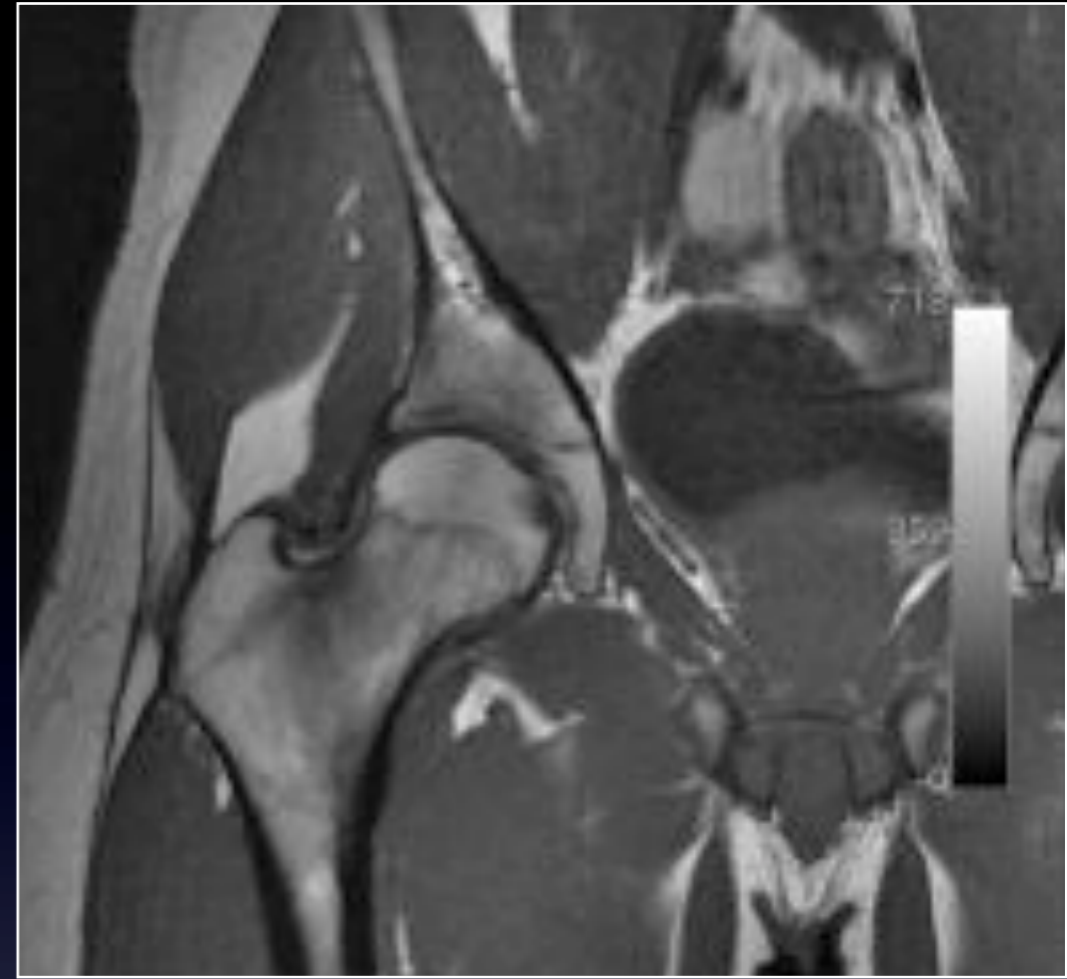

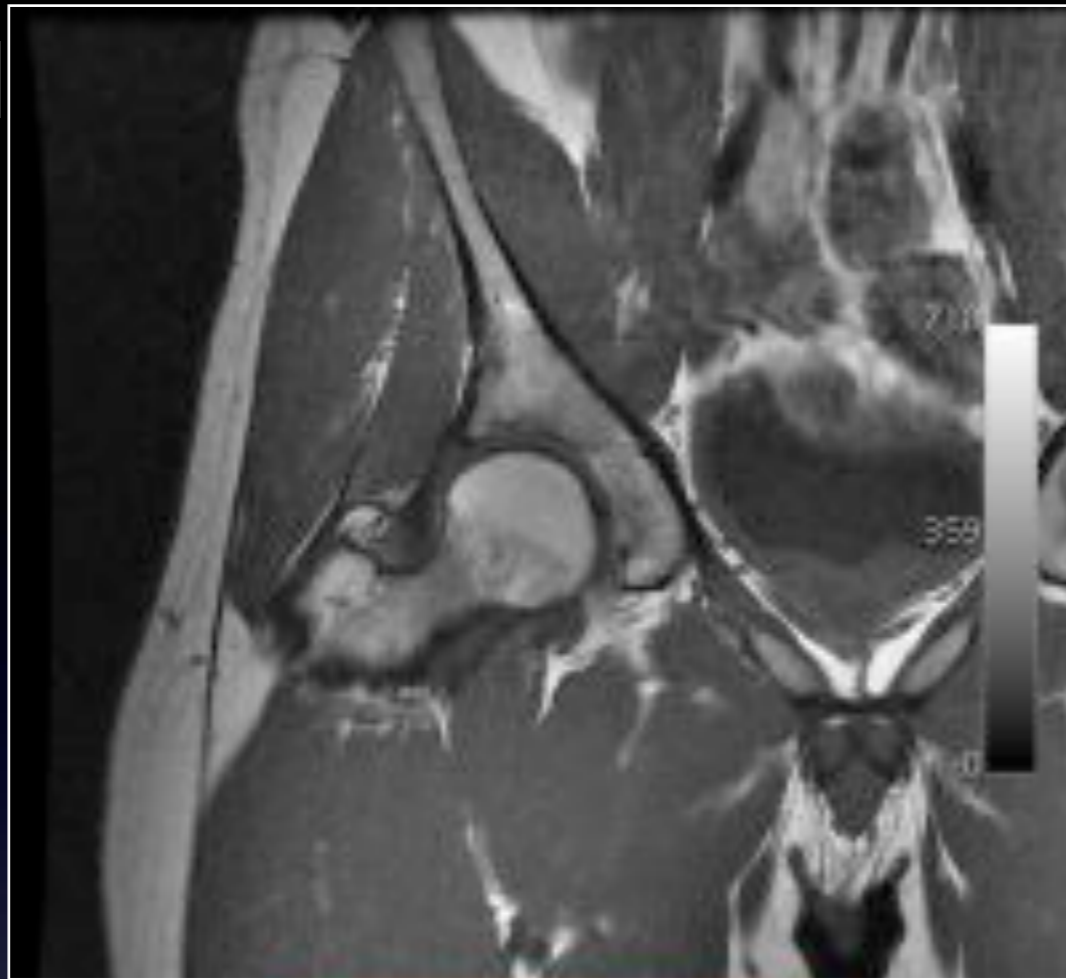
Axial T1 fat sat
Gado

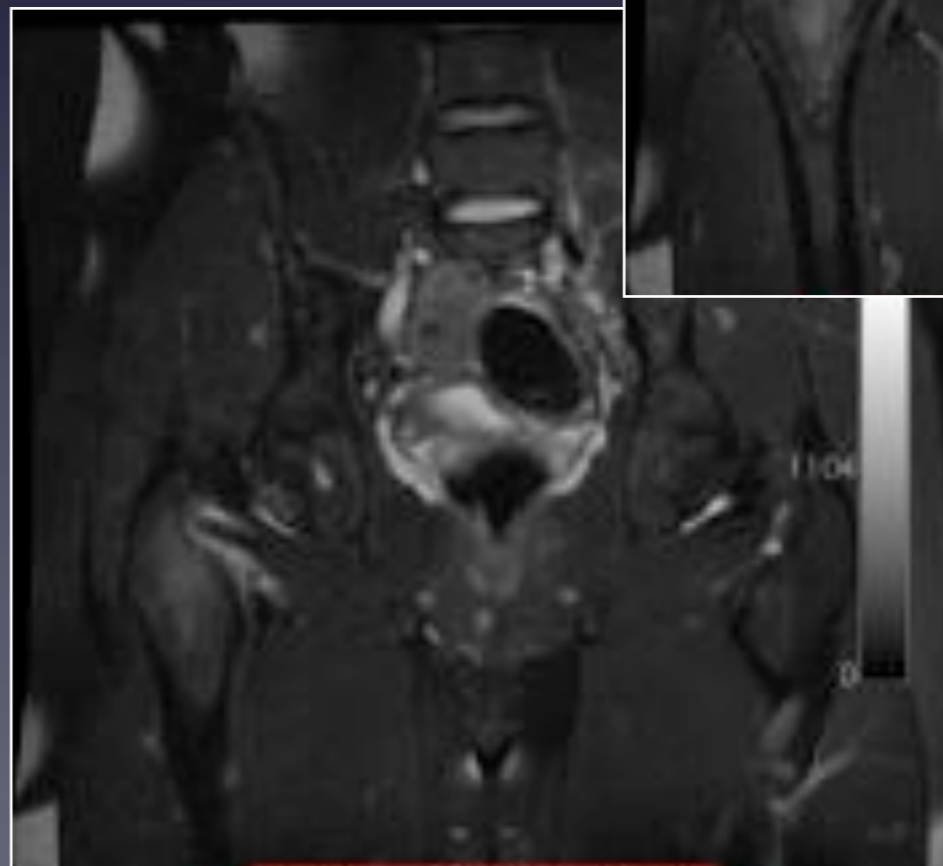
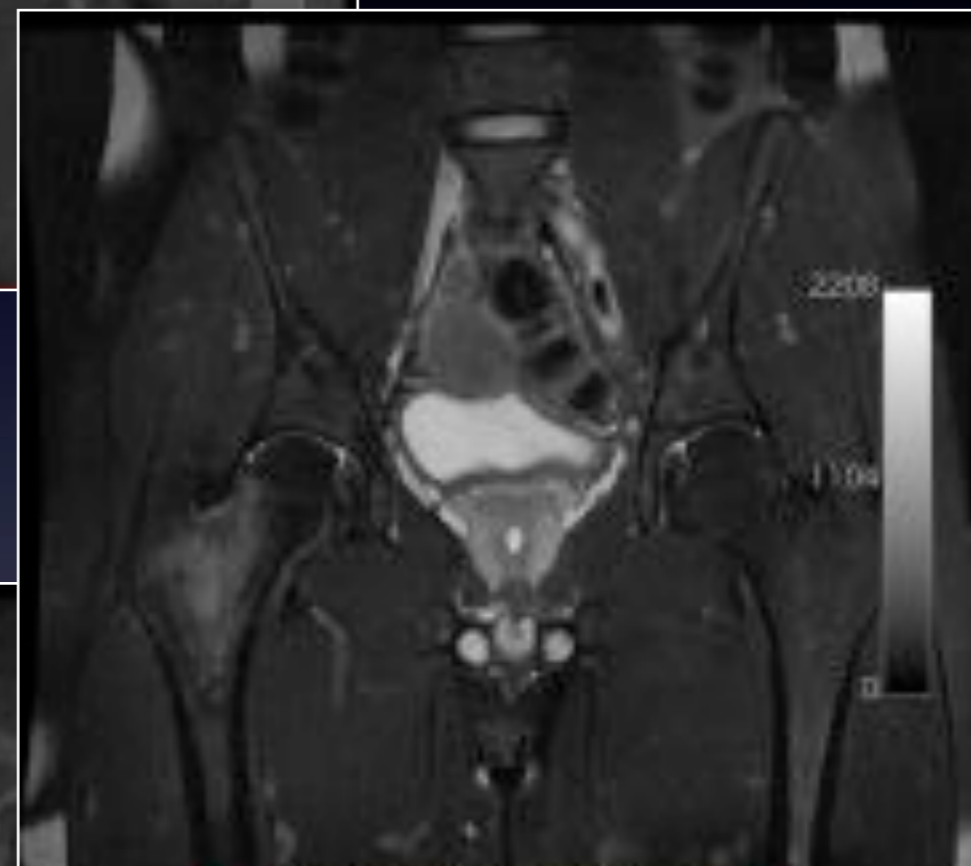
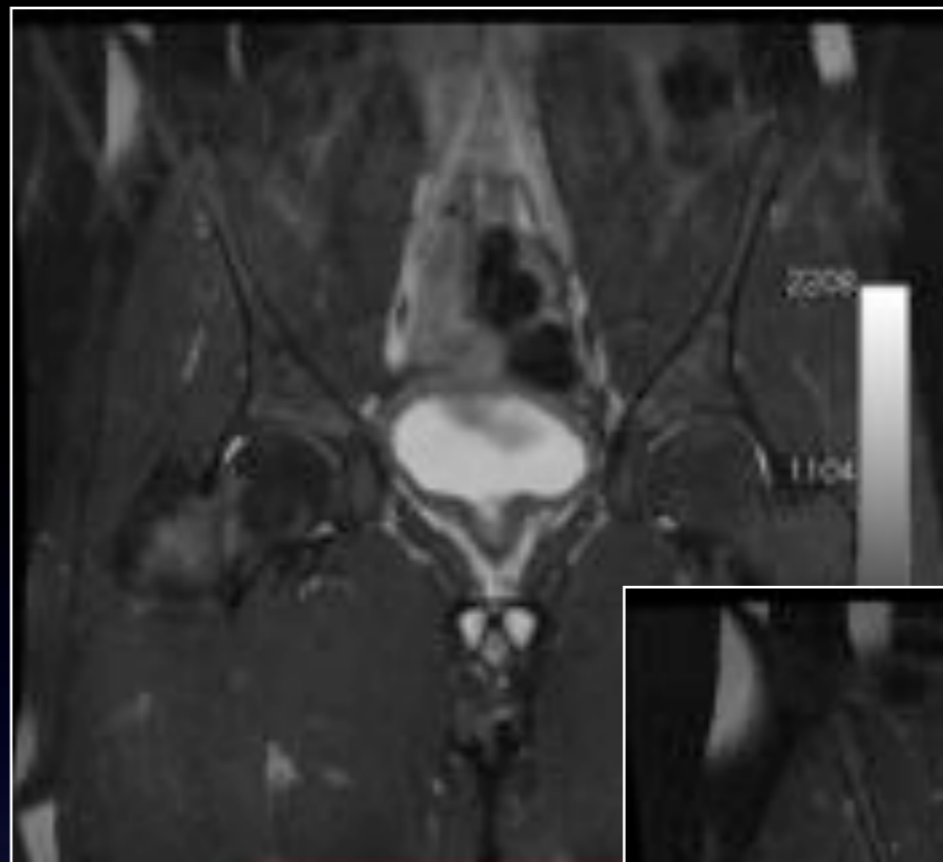
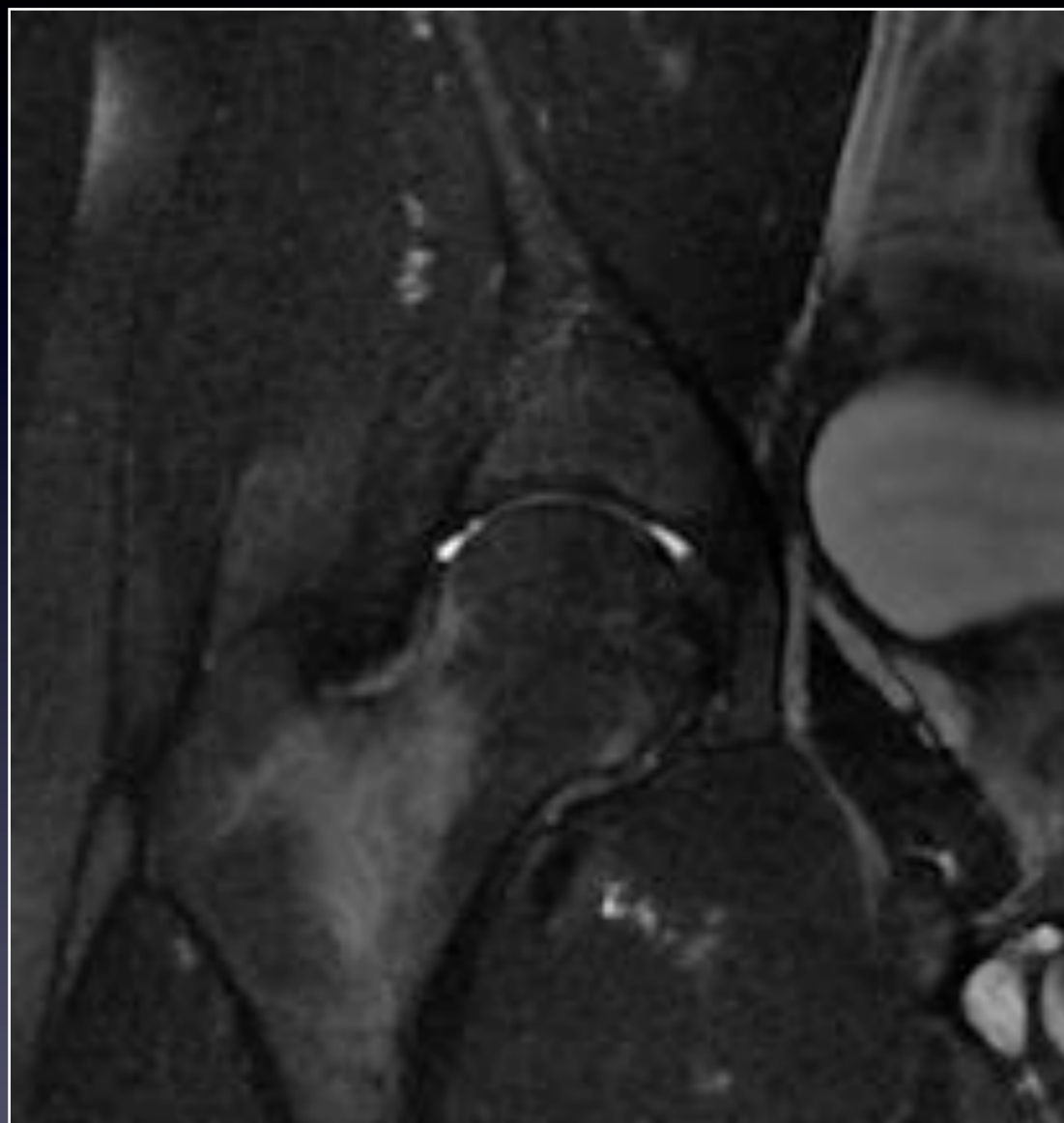
- Scanner hanche Droite Mars 2013 : RAS
- Traitement
 - Décharge pendant 45 jours
 - Marche avec des cannes canadiennes
- Nouvelle consultation : **Juin 2013**
 - Persistance des douleurs de la hanche
 - Nouvelle imagerie de la hanche droite

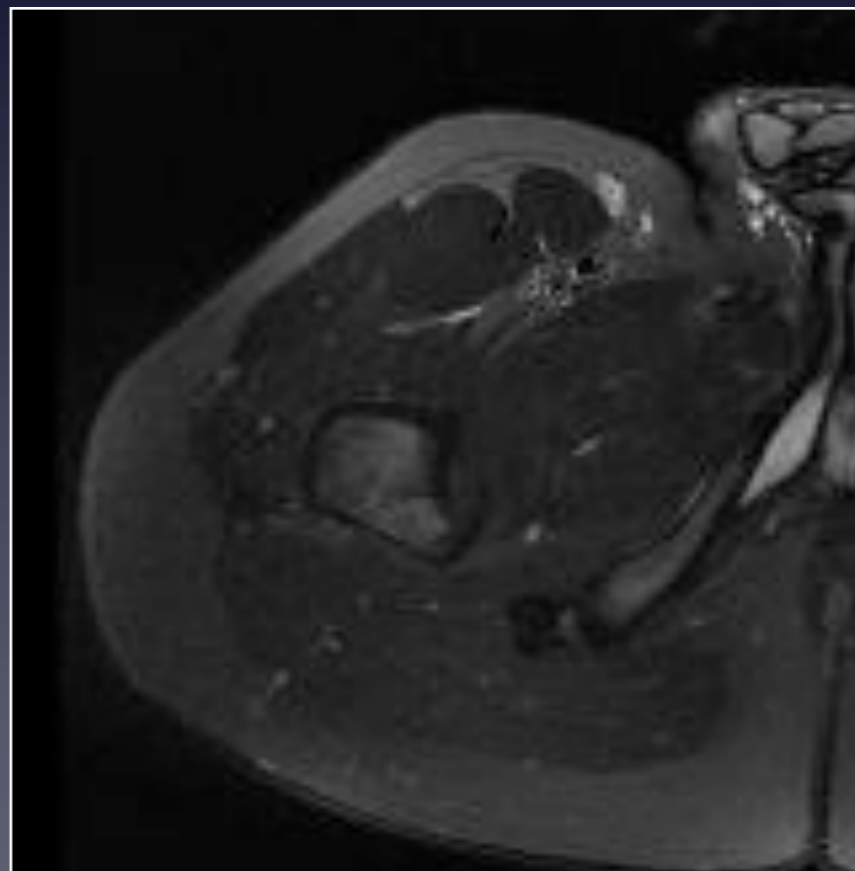
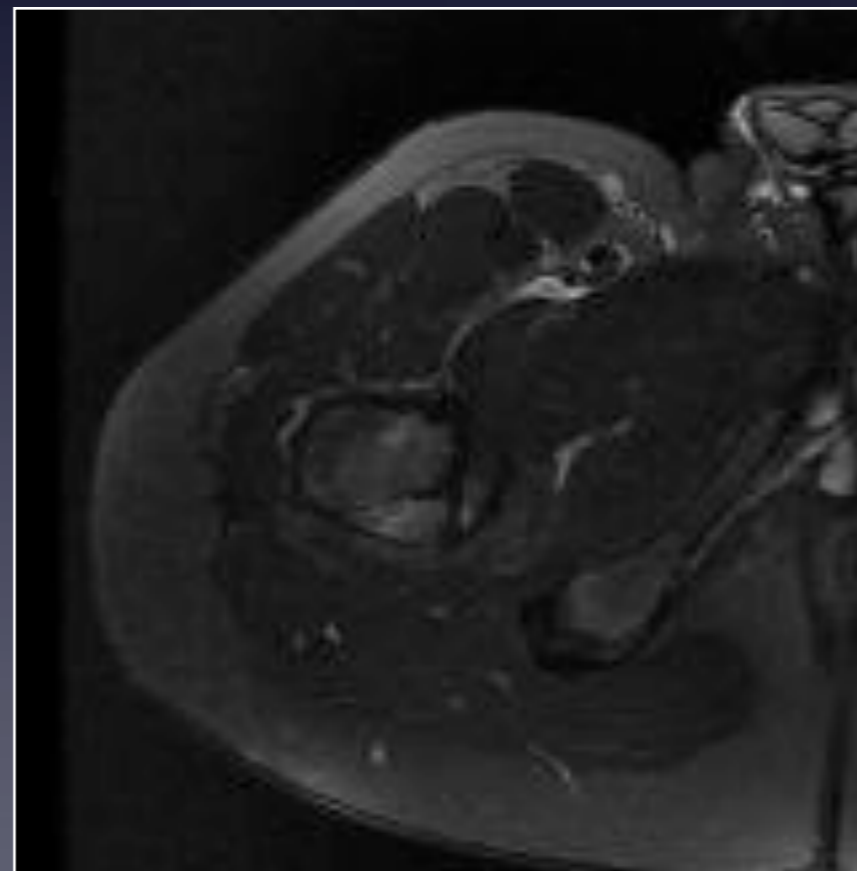
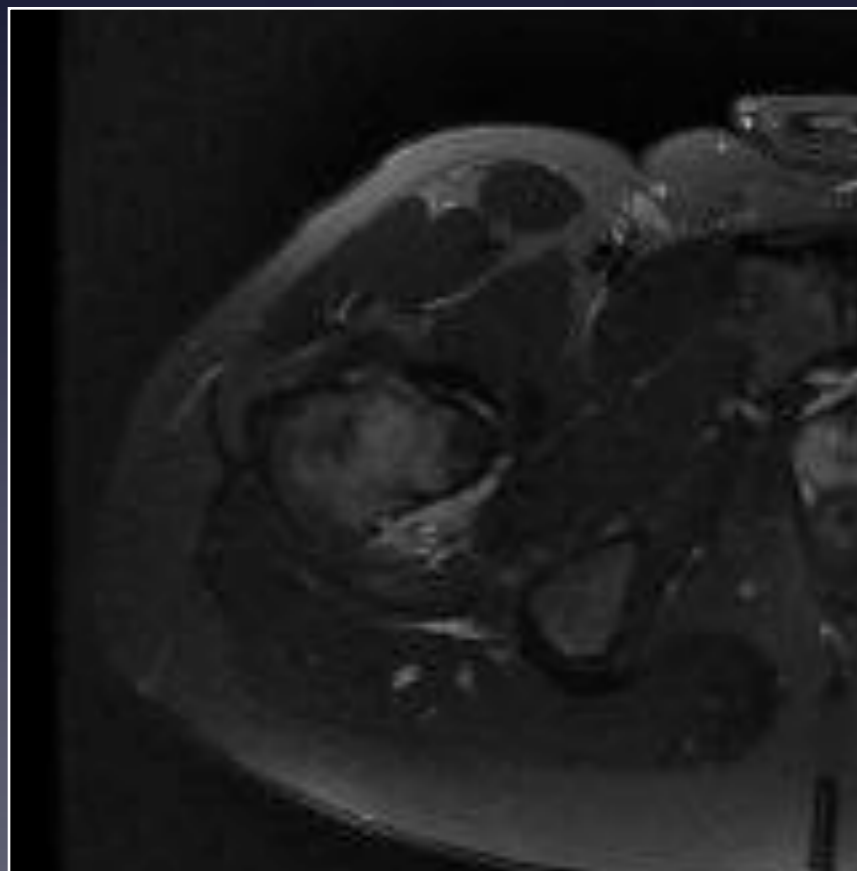
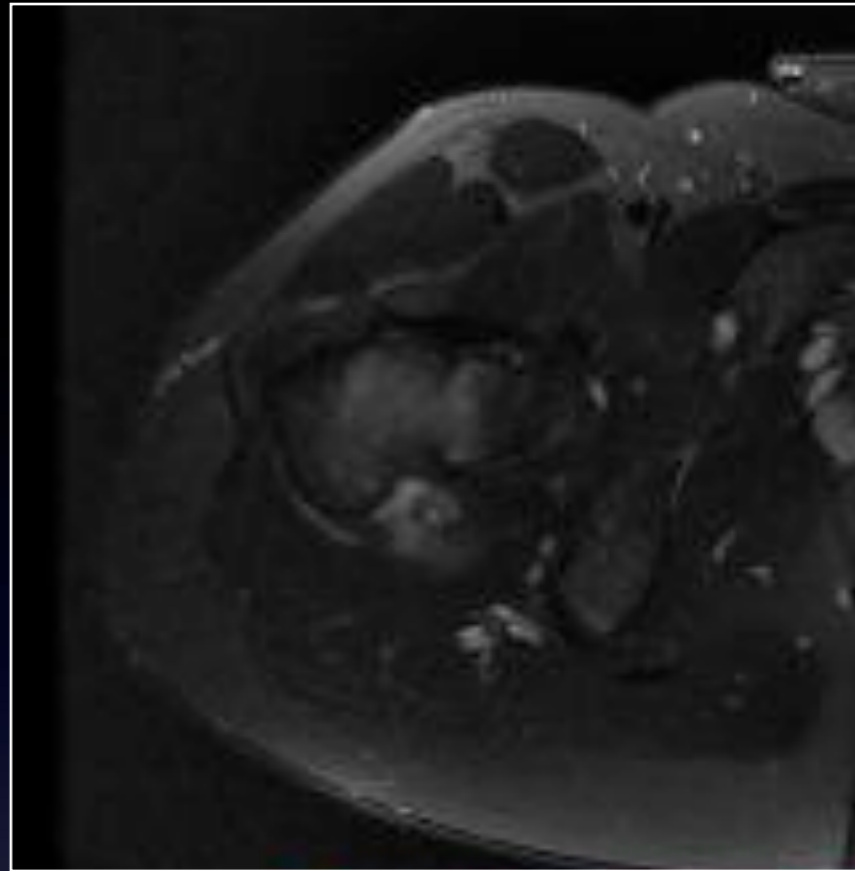
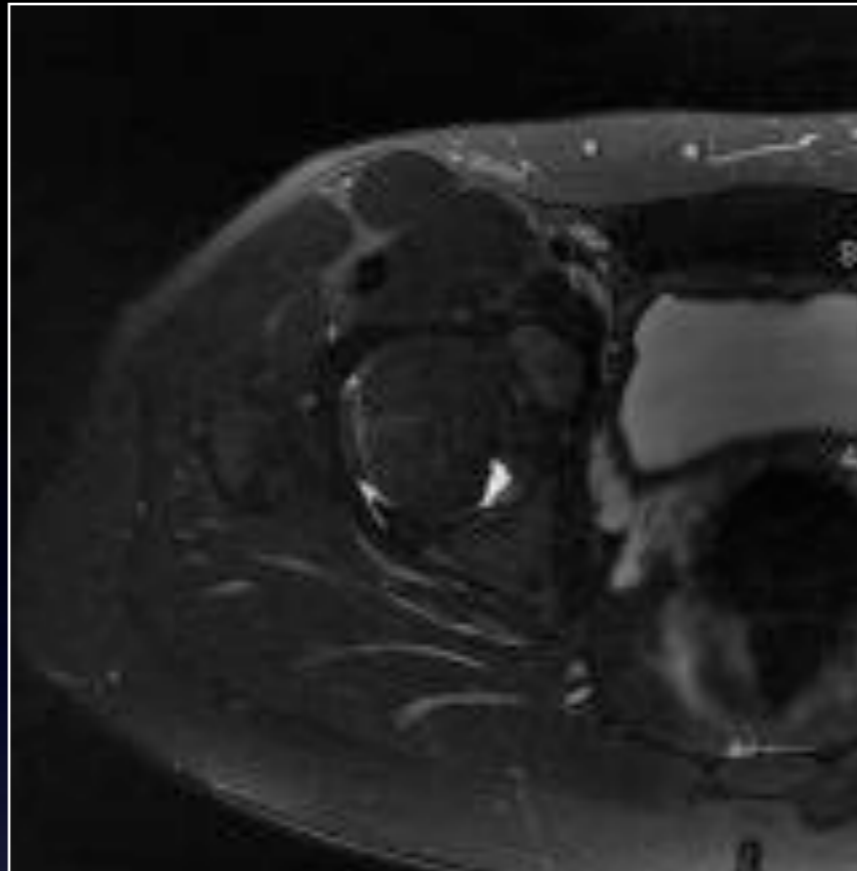
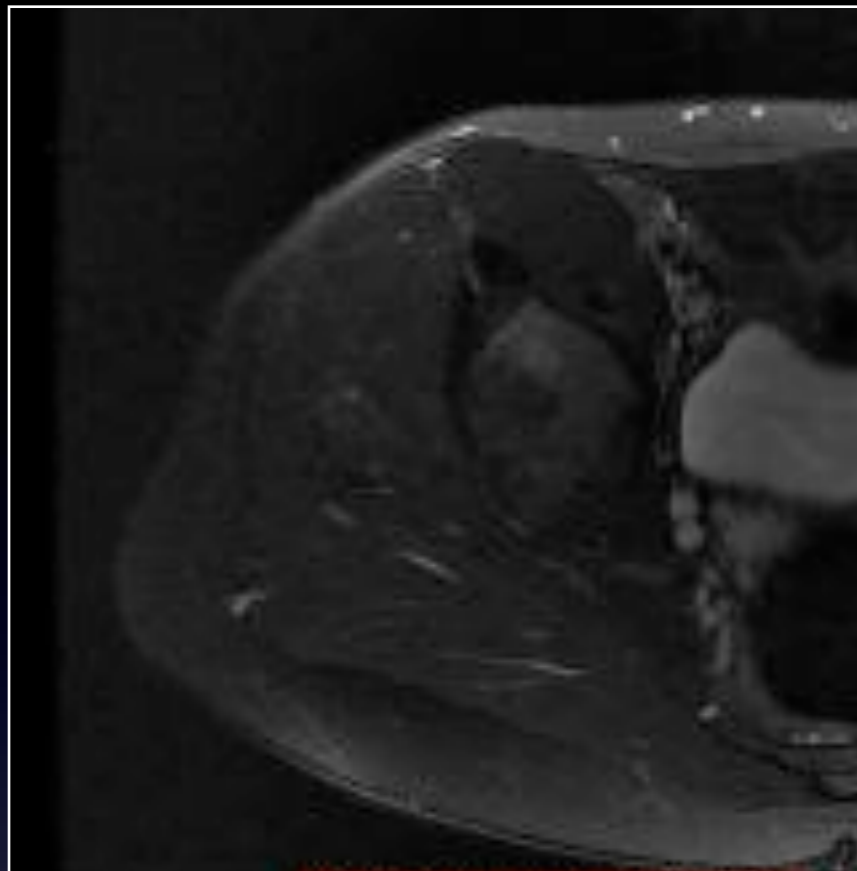
IRM Juillet 2013

Coronal T1

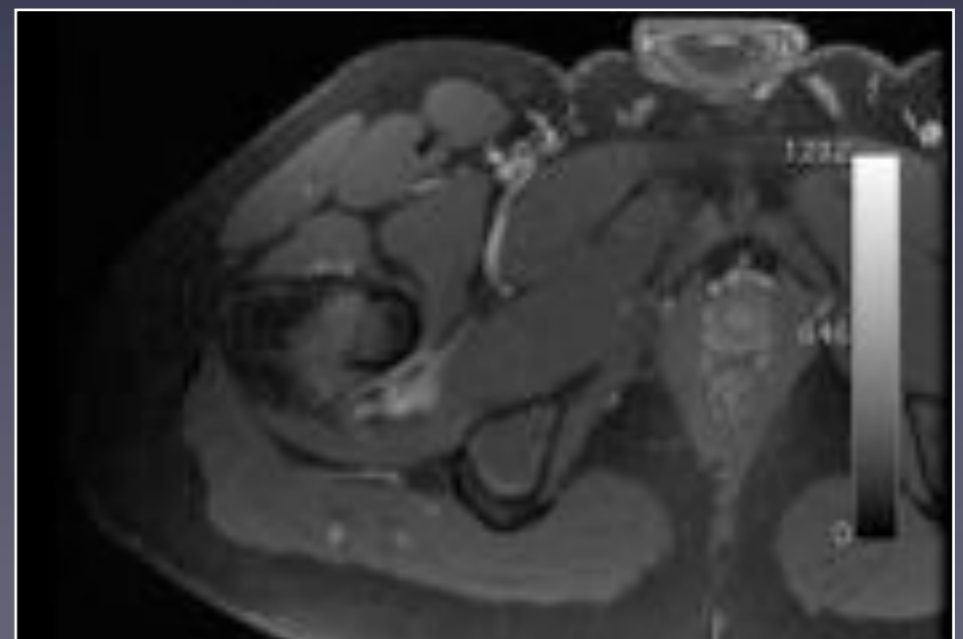
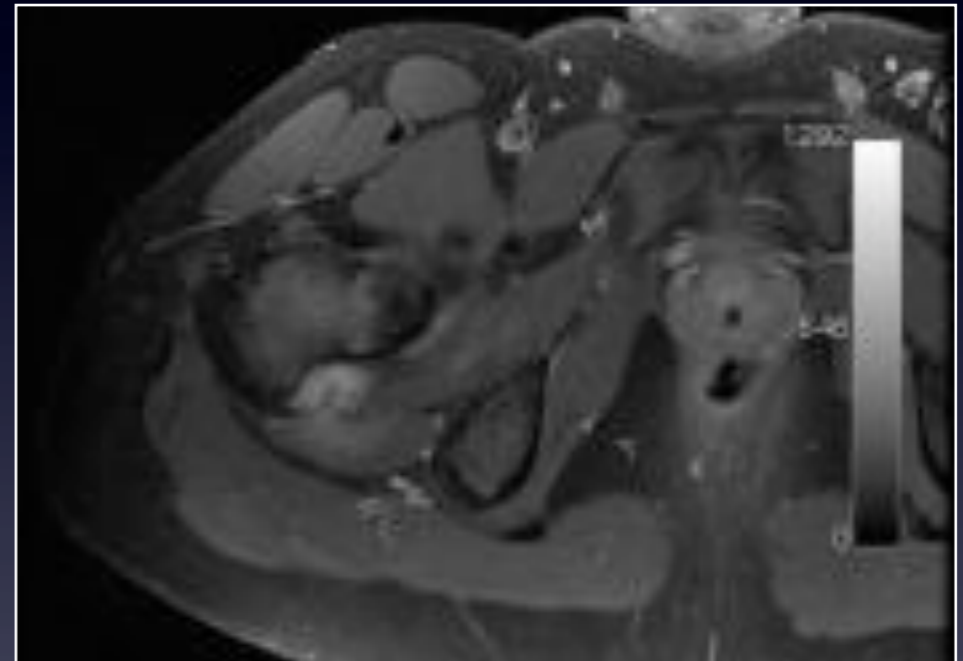
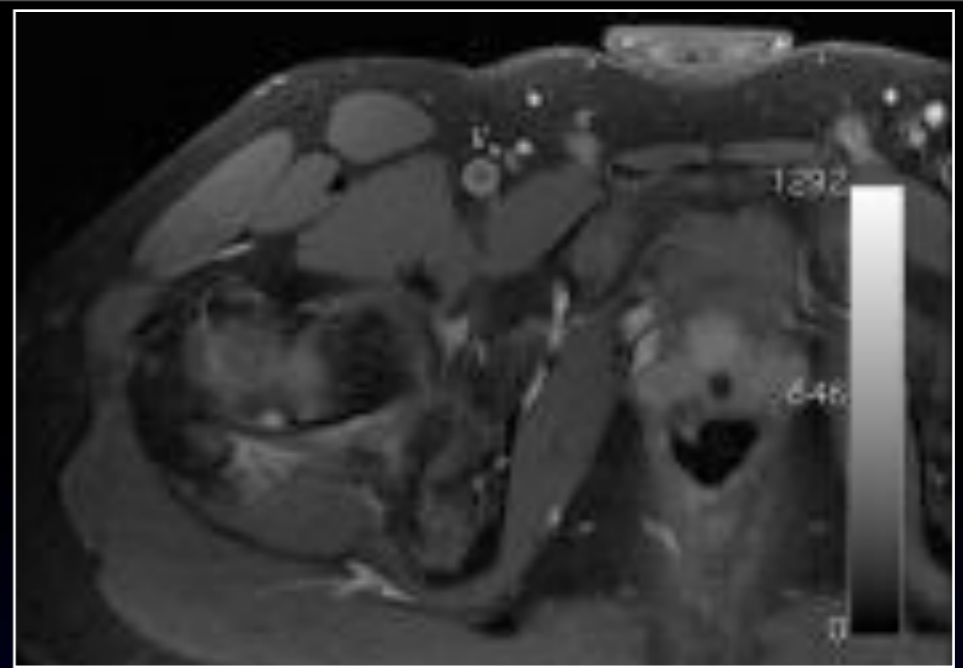
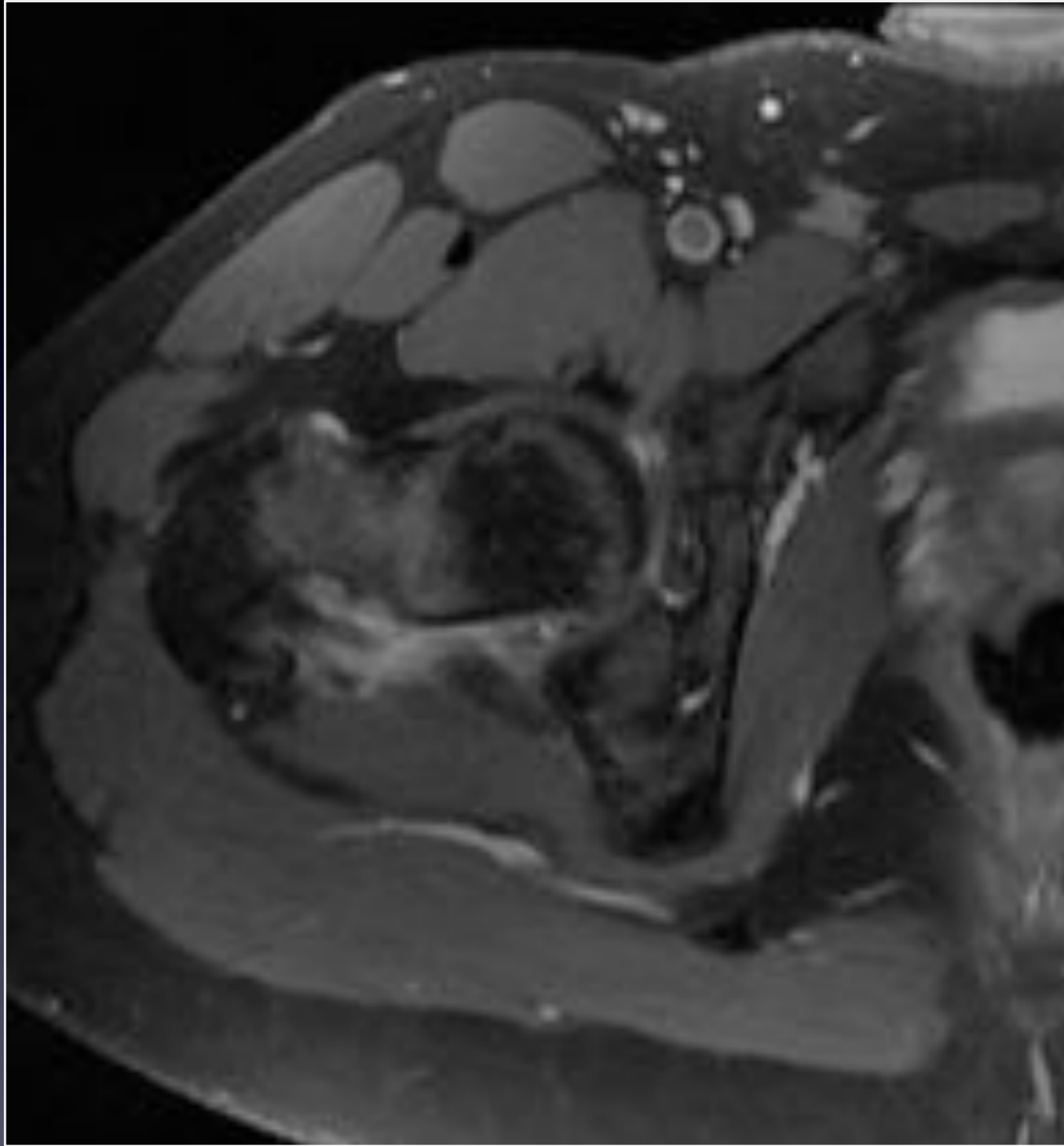


Coronal T2 Fat Sat





Axial T2 Fat Sat



Axial T1 Fat Sat Gado

Avez vous besoin d'examens complémentaires ?

Quel est votre diagnostic positif ?

Quels sont les diagnostics différentiels ?

