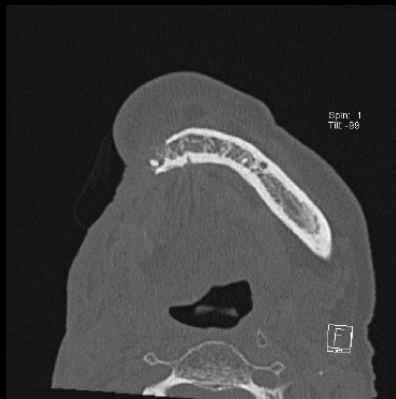

# Complications de la radiothérapie :

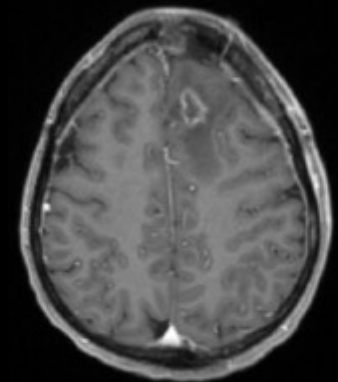
## Cas cliniques

---

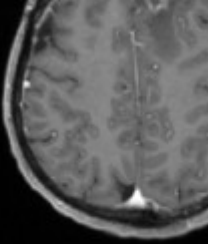
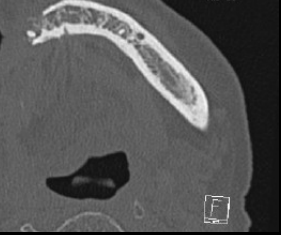

Claire Boutet

14 Septembre 2013

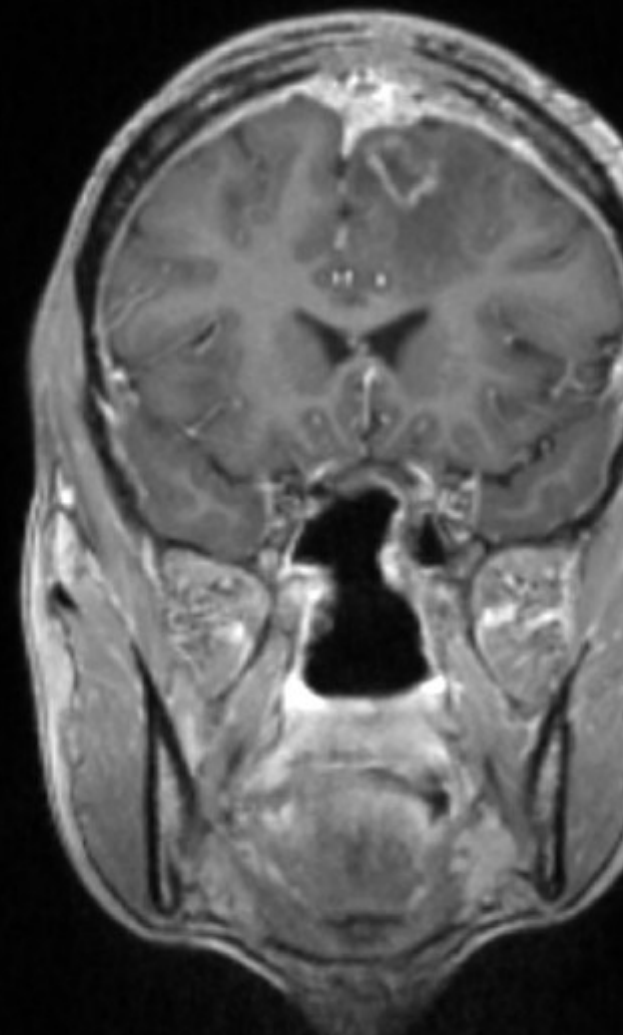
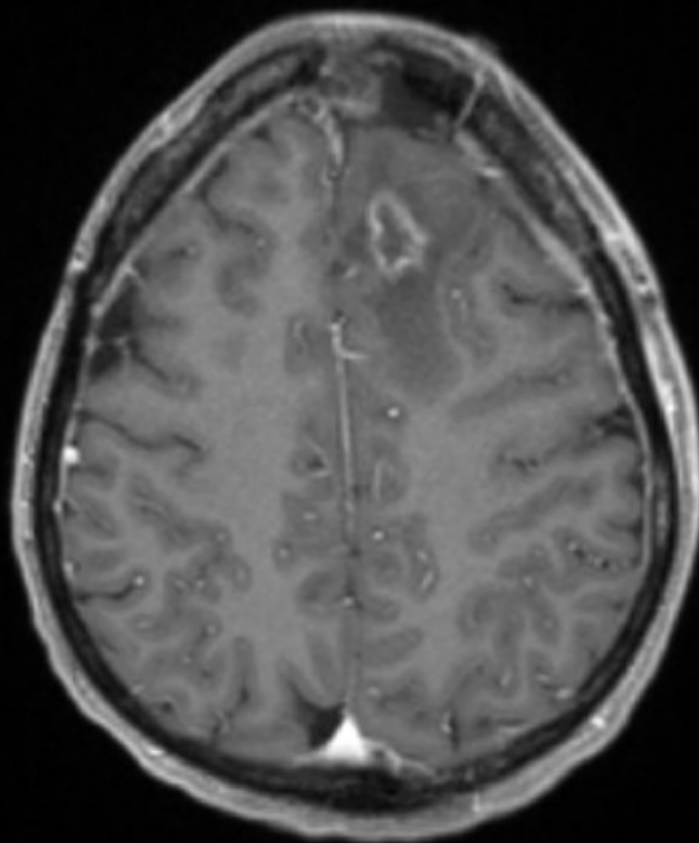
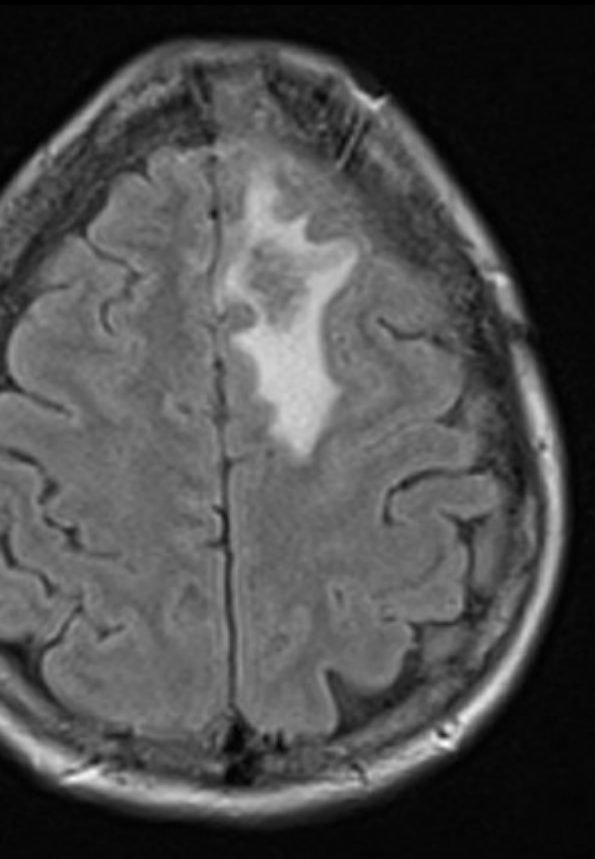
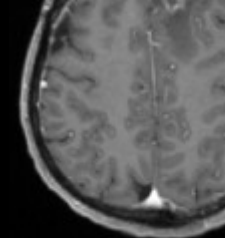
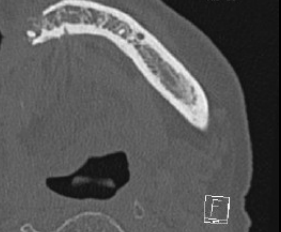


# Cas clinique 1

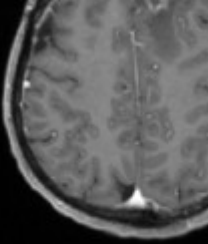


Patiente de 36 ans présentant un cancer de l'ethmoïde avec extension frontale, traitée par chirurgie et radiothérapie

# Cas clinique 1

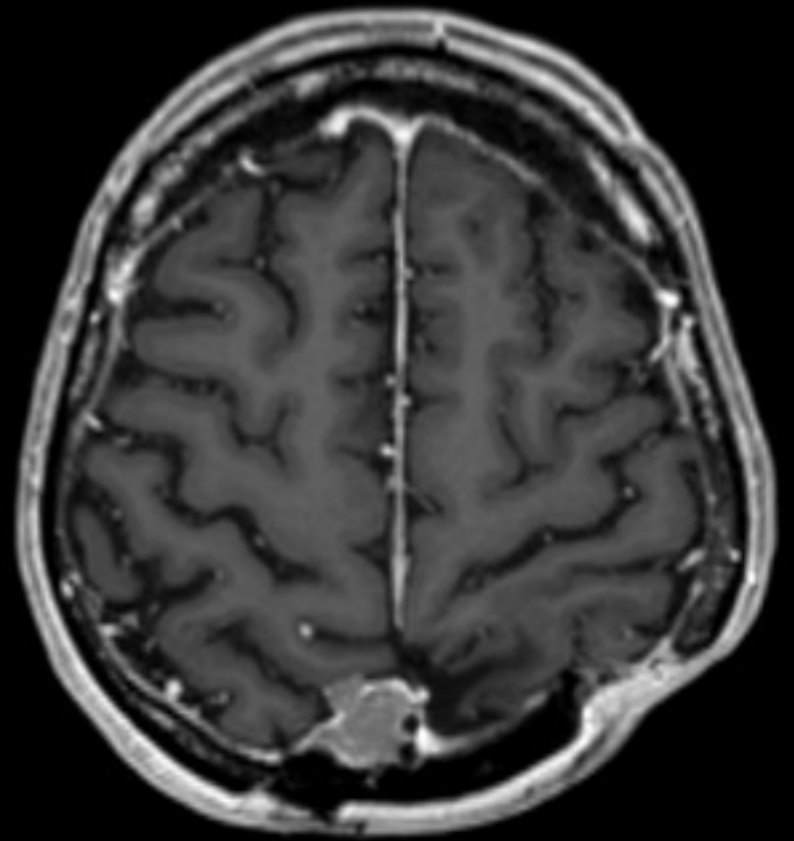
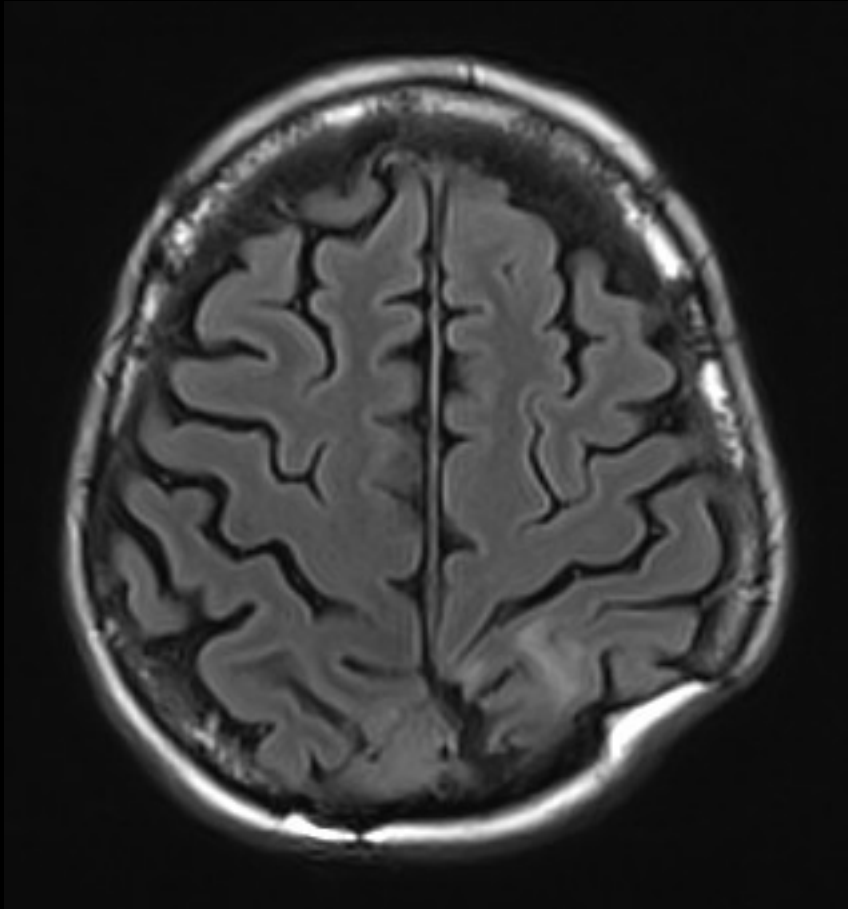
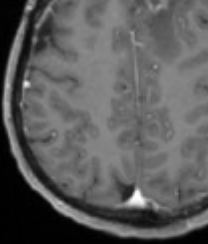


# Cas clinique 2



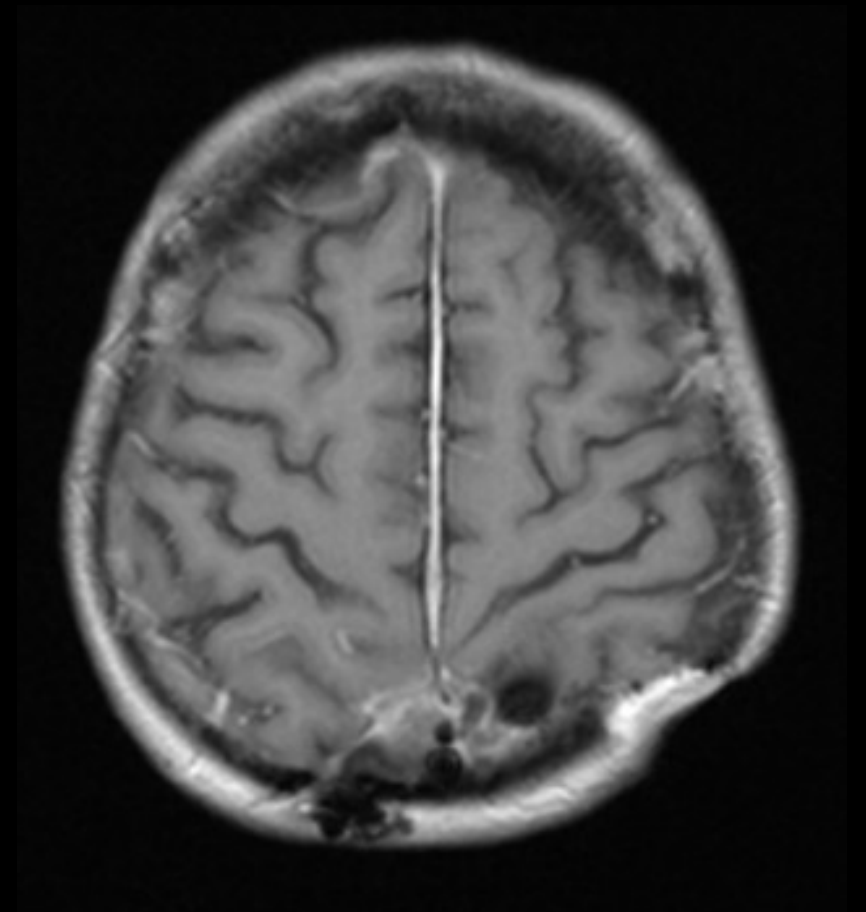
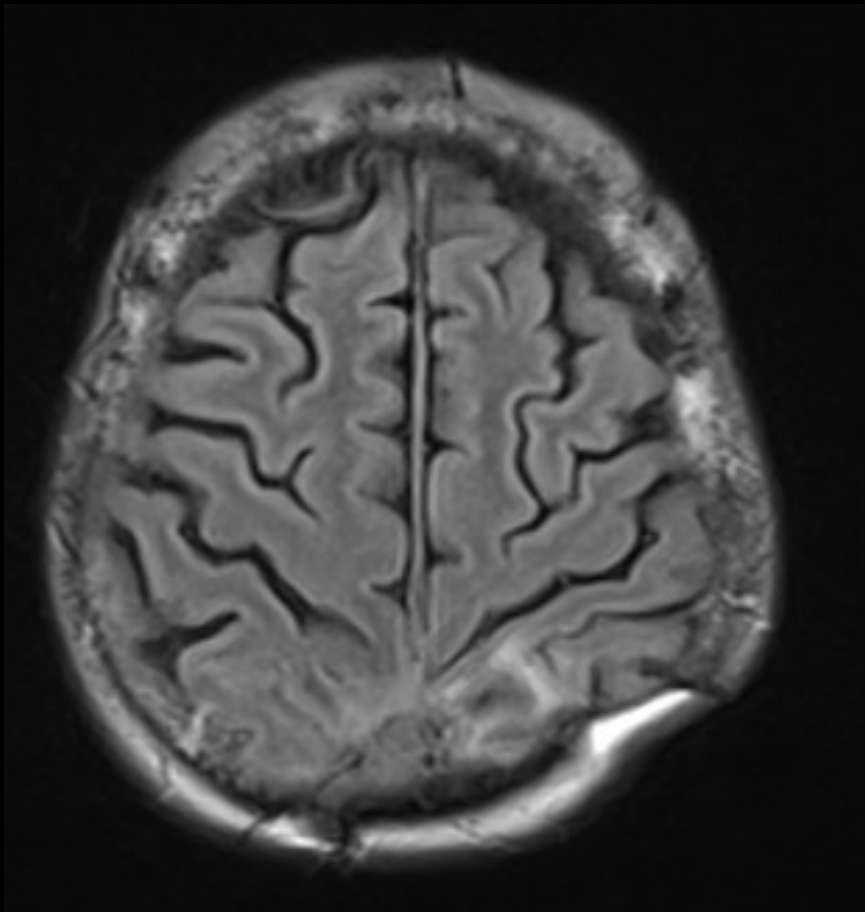
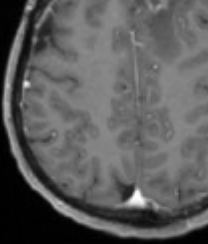
Patiente de 44 ans présentant un méningiome pariétal droit agressif, opérée et radiothérapée

# Cas clinique 2



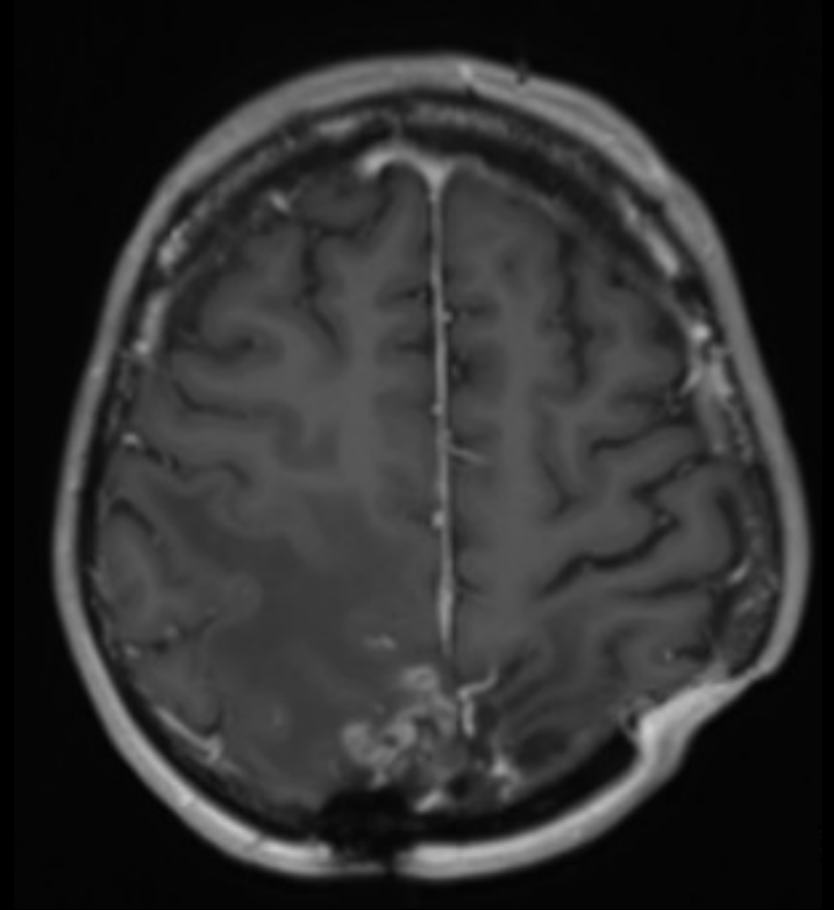
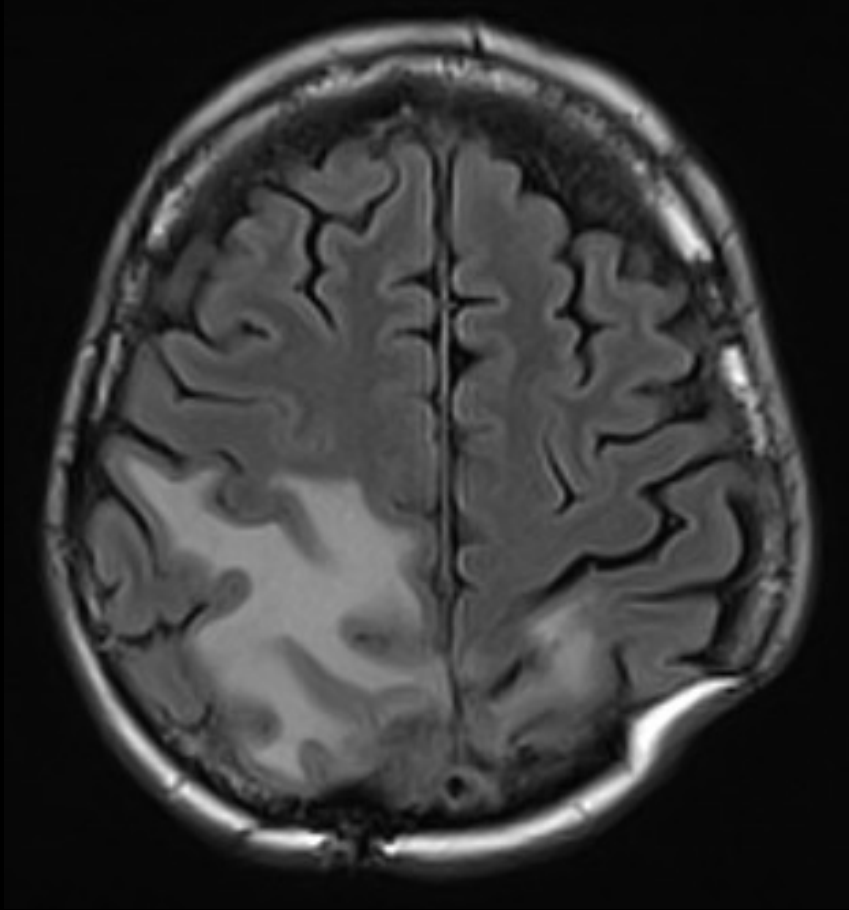
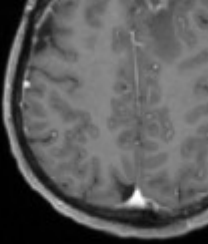
IRM du 16.05.2012

# Cas clinique 2



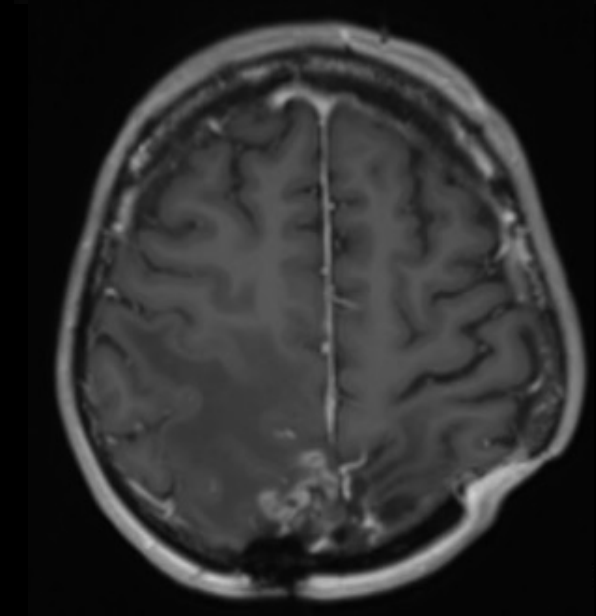
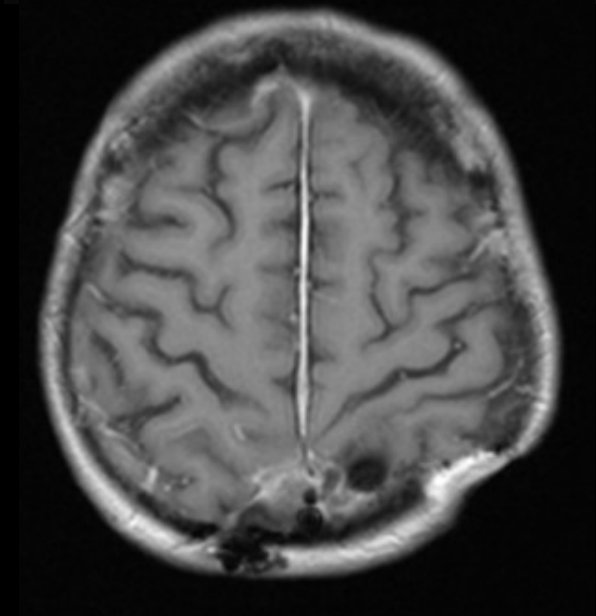
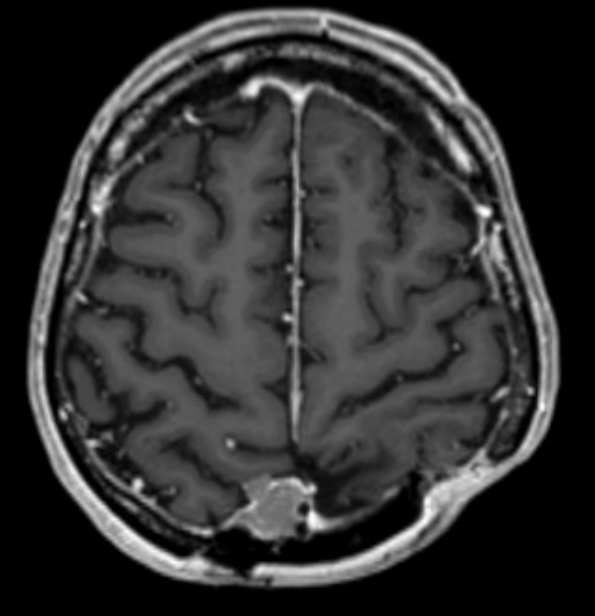
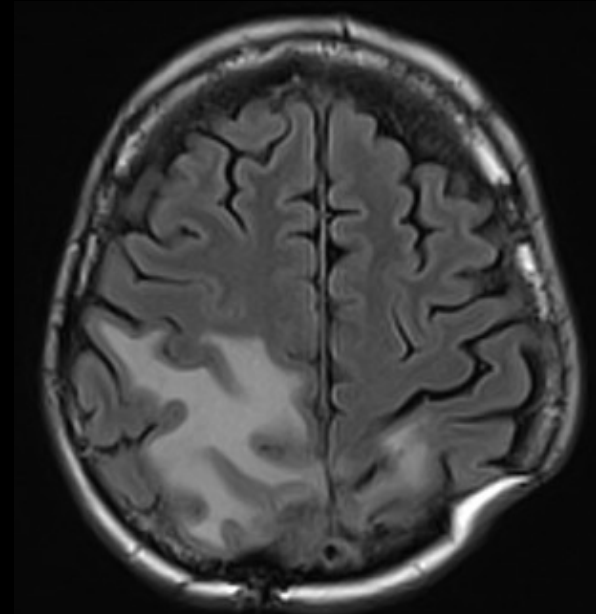
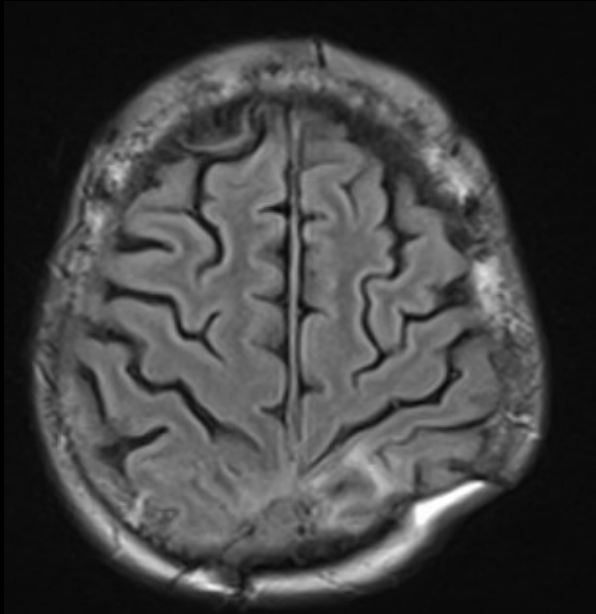
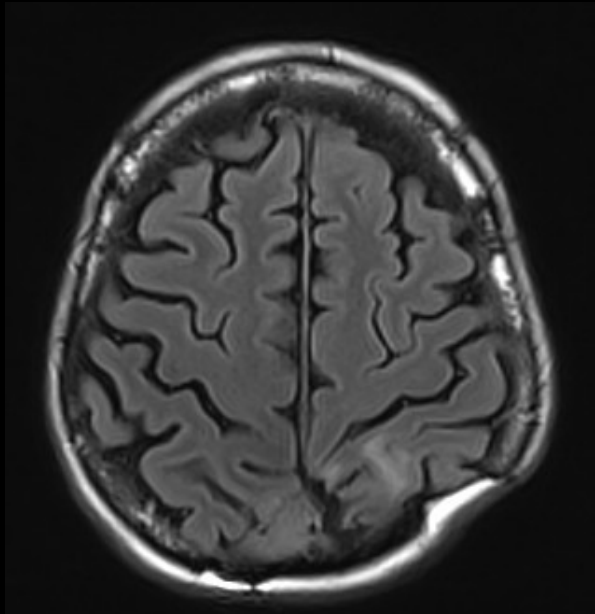
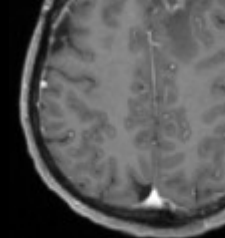
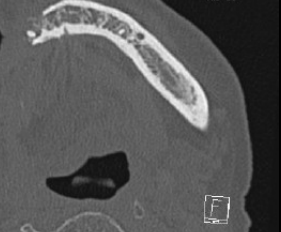
IRM du 21.02.2013

# Cas clinique 2



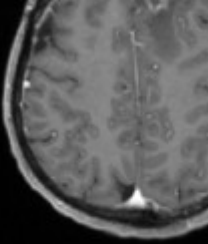
IRM du 16.08.2013

# Cas clinique 2



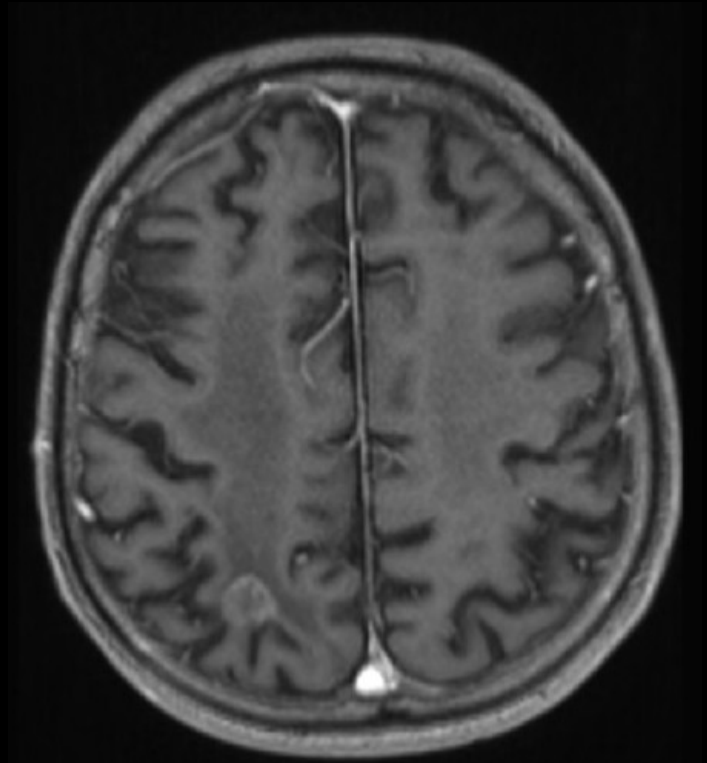
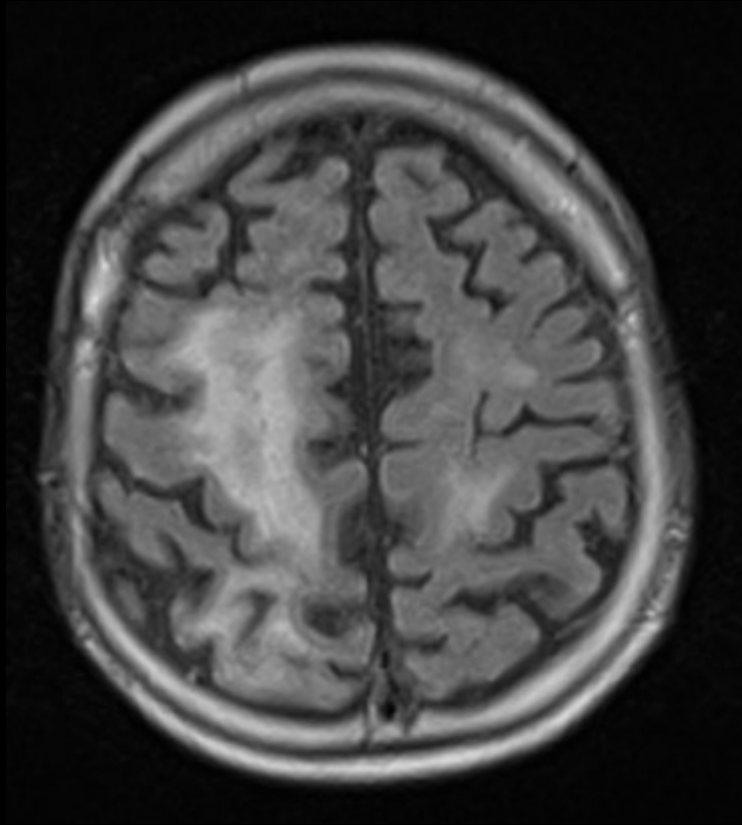
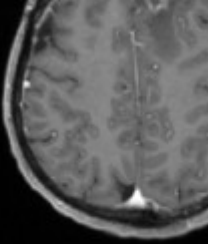


# Cas clinique 3


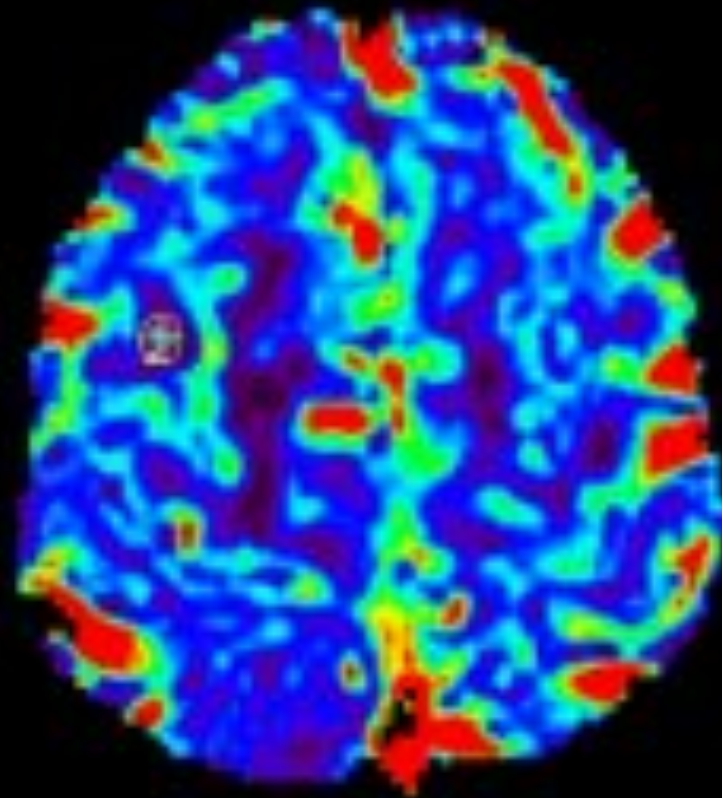
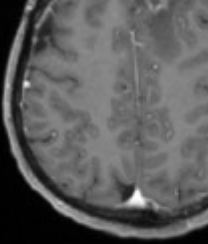


Patient de 76 ans, traitée par radiothérapie pour métastase cérébrale d'un cancer pulmonaire

# Cas clinique 3

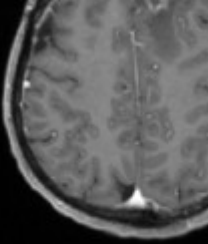


# Cas clinique 3



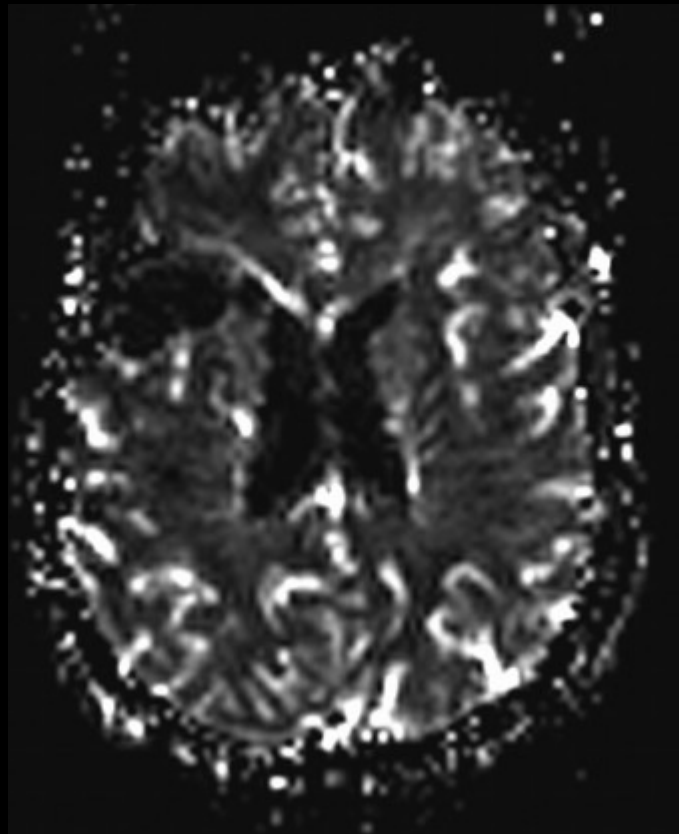
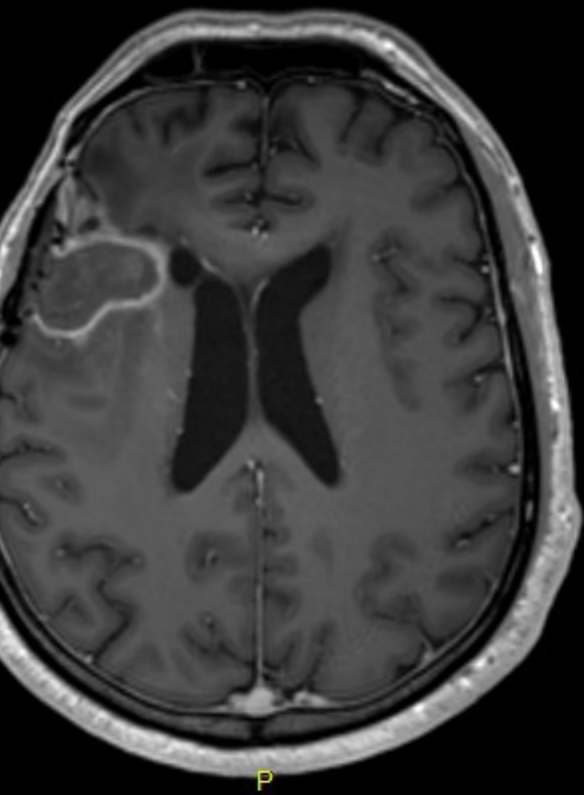
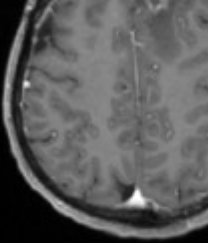
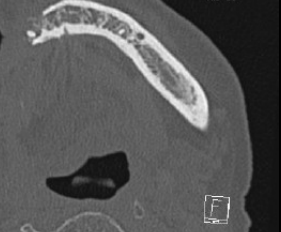
rCBV ↘

# Cas clinique 4

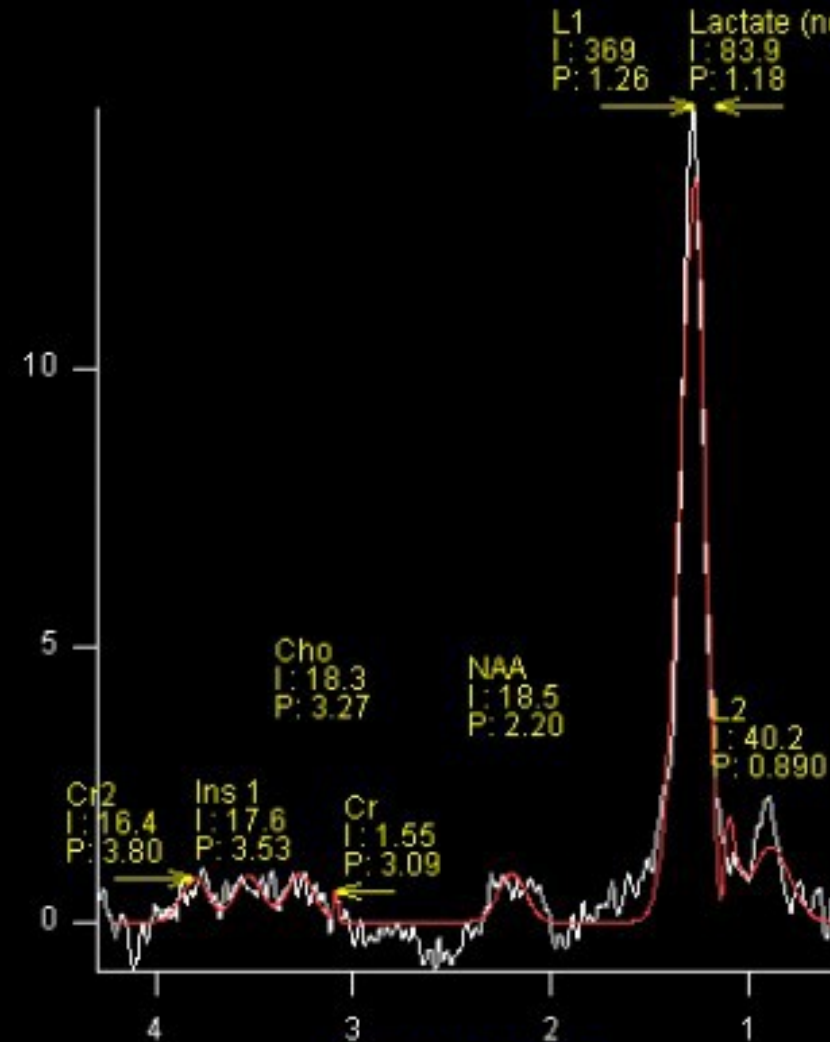


Patient de 56 ans aux antécédents de glioblastome de grade IV opéré à 2 reprises puis traité par radio-chimiothérapie.  
Contrôle systématique.

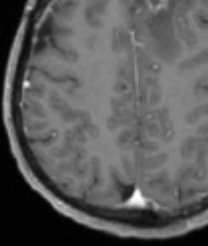
# Cas clinique 4



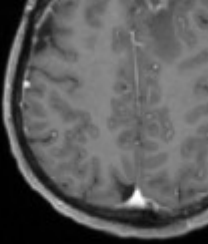
rCBV ↘



# Complication ?

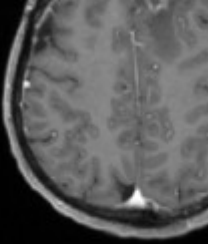


# Complication ?



Radionécrose cérébrale

# Complication ?



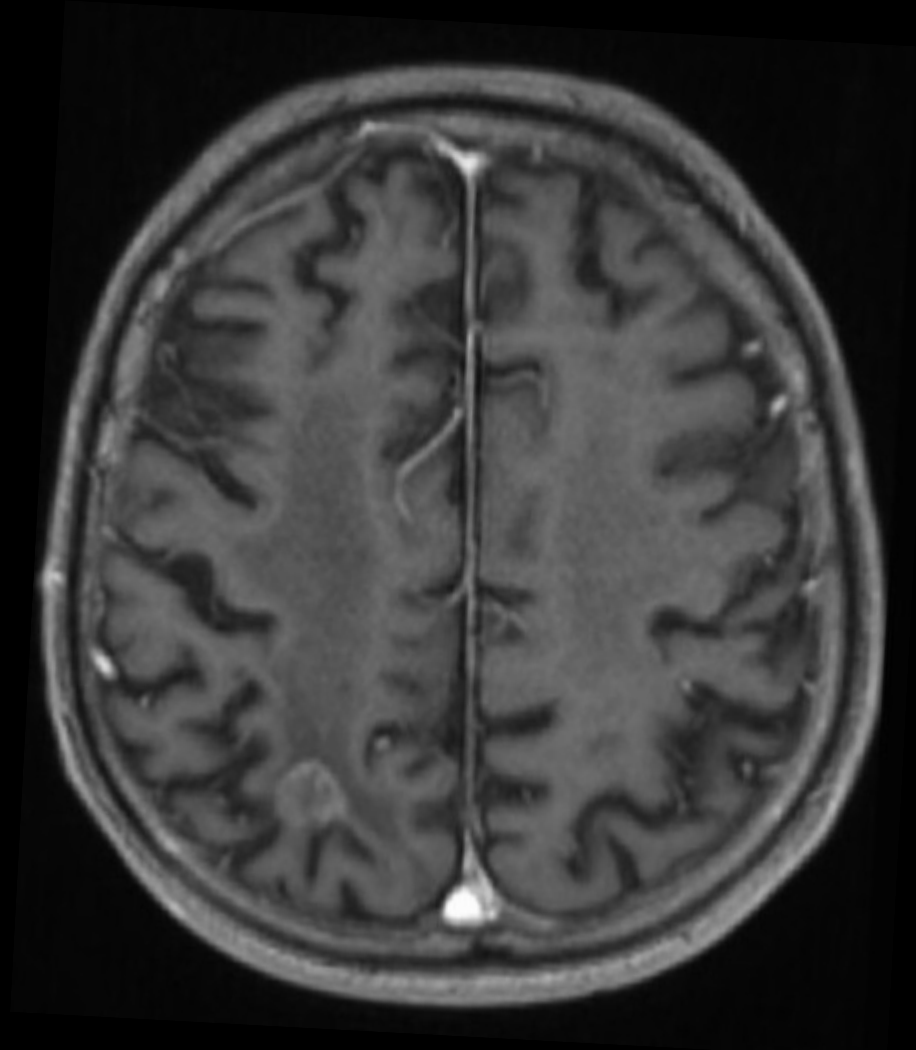
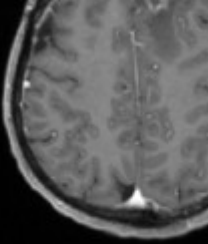
## Radionécrose cérébrale

Éléments diagnostics :

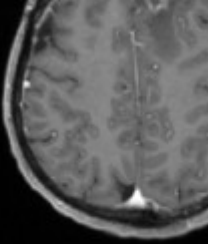
IRM morphologique : similaire à lésion néoplasique de haut grade



# Complication ?



# Complication ?

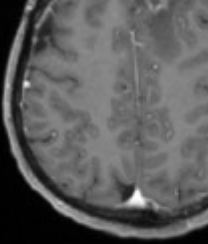


## Radionécrose cérébrale

Éléments diagnostics :

IRM morphologique : similaire à lésion néoplasique de haut g

# Complication ?




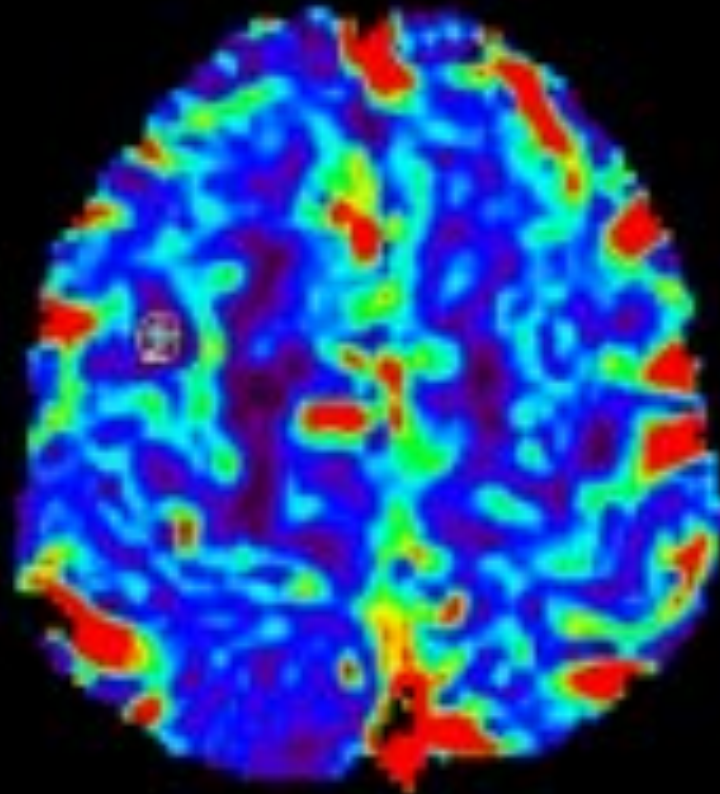
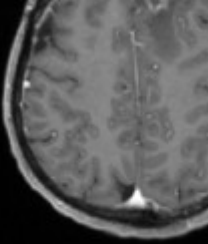
## Radionécrose cérébrale

Éléments diagnostics :

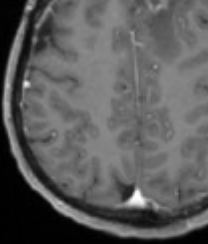
IRM morphologique : similaire à lésion néoplasique de haut grade

Perfusion : pas d'augmentation du CBV, hypoperfusion

# Complication ?



# Complication ?



## Radionécrose cérébrale

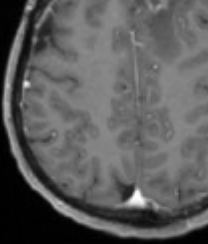
Éléments diagnostics :

IRM morphologique : similaire à lésion néoplasique de haut grade

Perfusion : pas d'augmentation du CBV, hypoperfusion



# Complication ?



## Radionécrose cérébrale

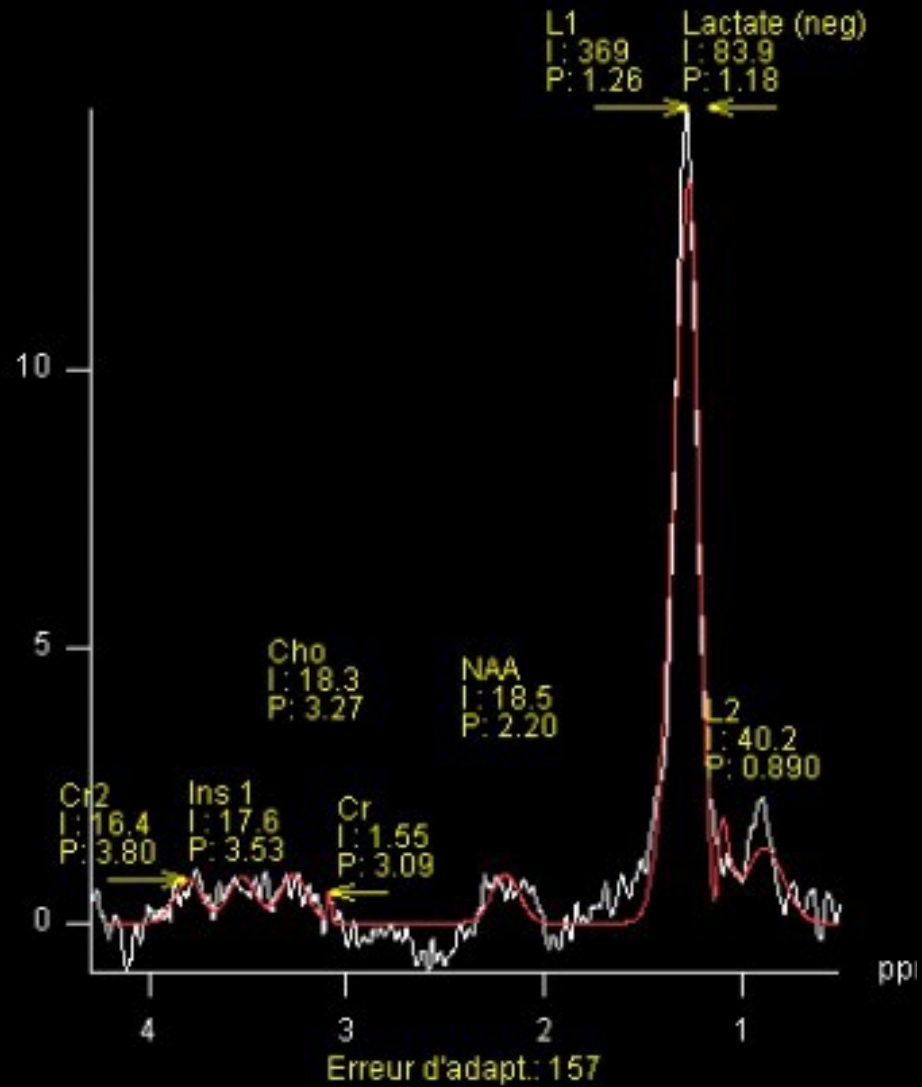
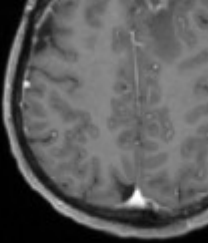
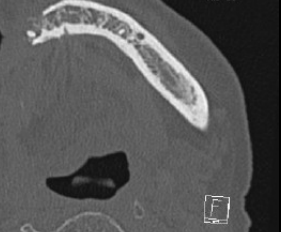
Eléments diagnostics :

IRM morphologique : similaire à lésion néoplasique de haut grade

Perfusion : pas d'augmentation du CBV, hypoperfusion

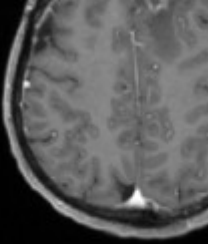
Spectroscopie : baisse des choline, créatine et NAA. Pic de lip

# Complication ?





# Complication ?



## Radionécrose cérébrale

Éléments diagnostics :

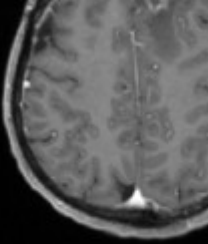
IRM morphologique : similaire à lésion néoplasique de haut grade

Perfusion : pas d'augmentation du CBV, hypoperfusion

Spectroscopie : baisse des choline, créatine et NAA. Pic de lip



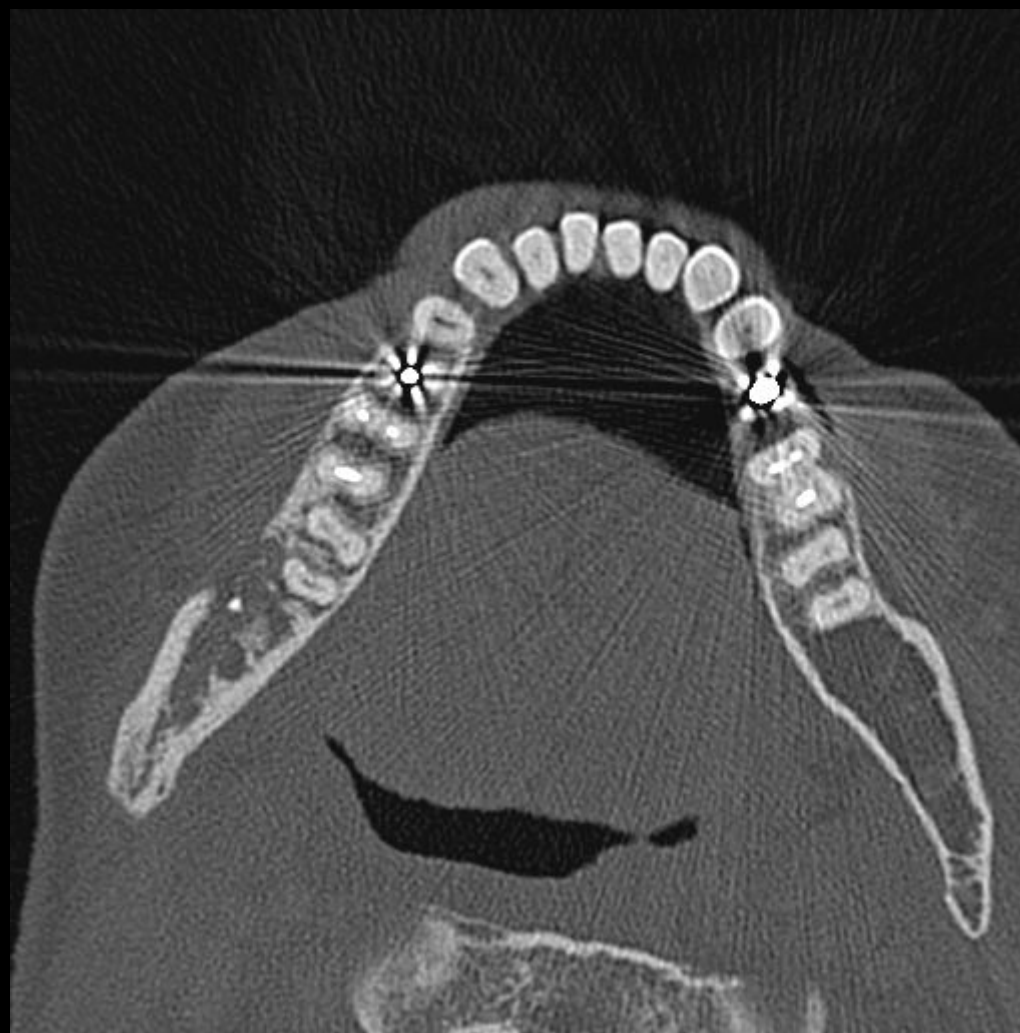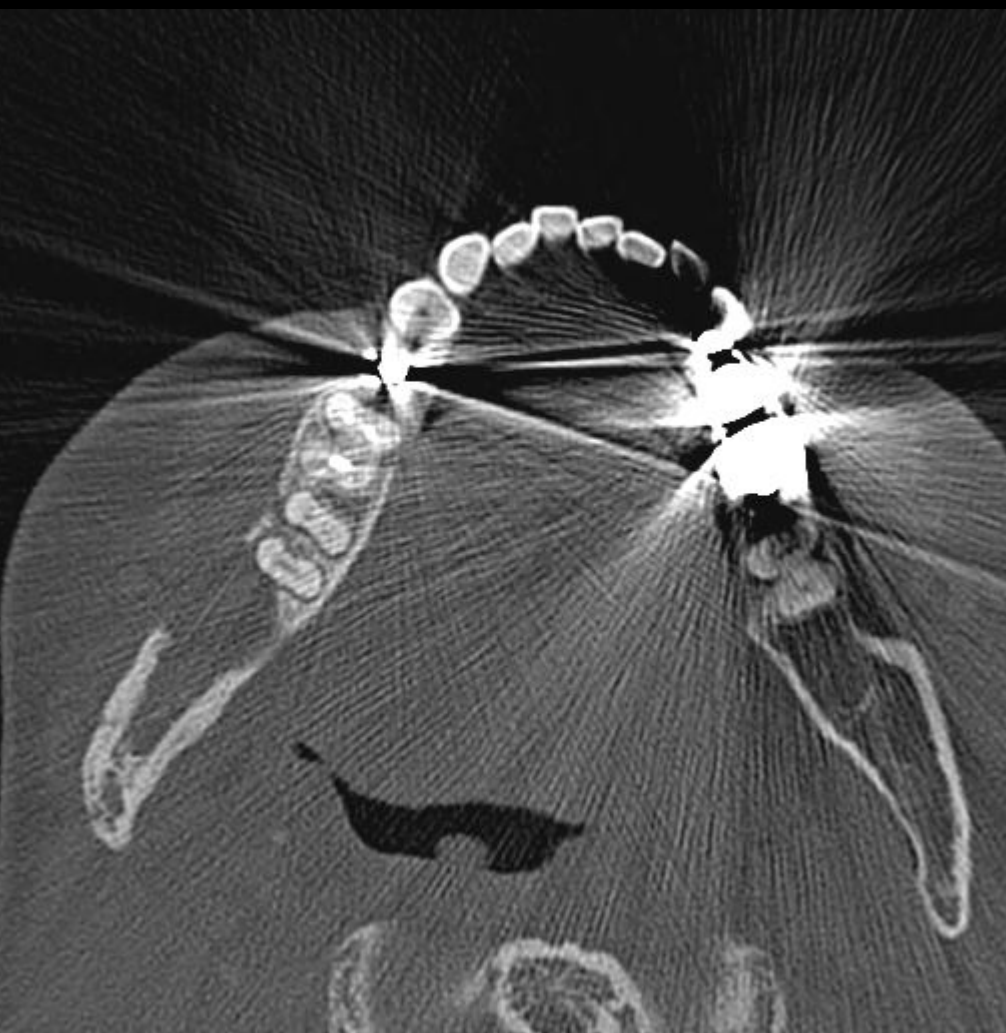
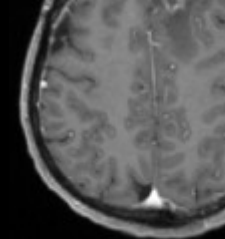
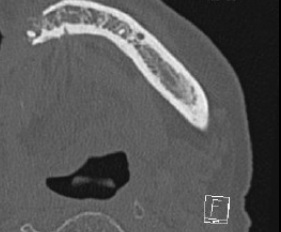
# Cas clinique 5



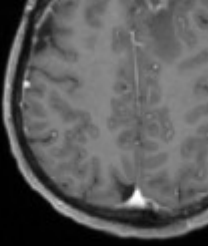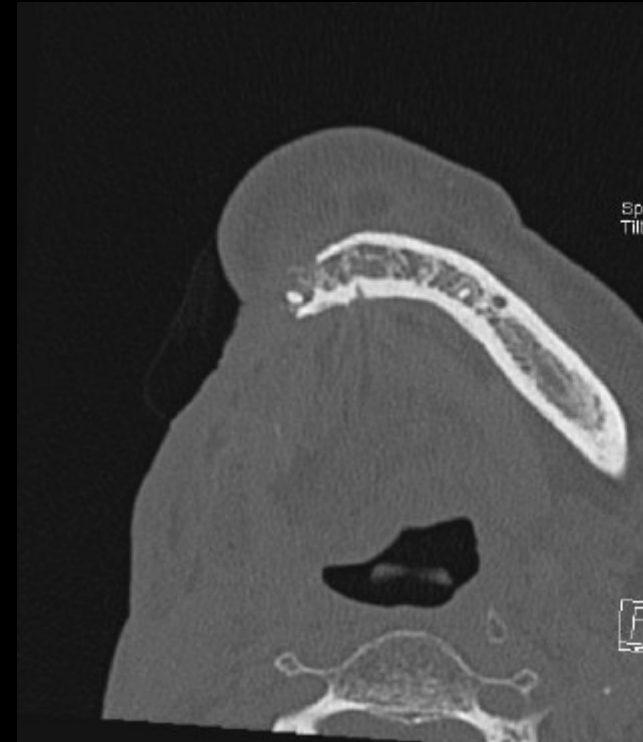
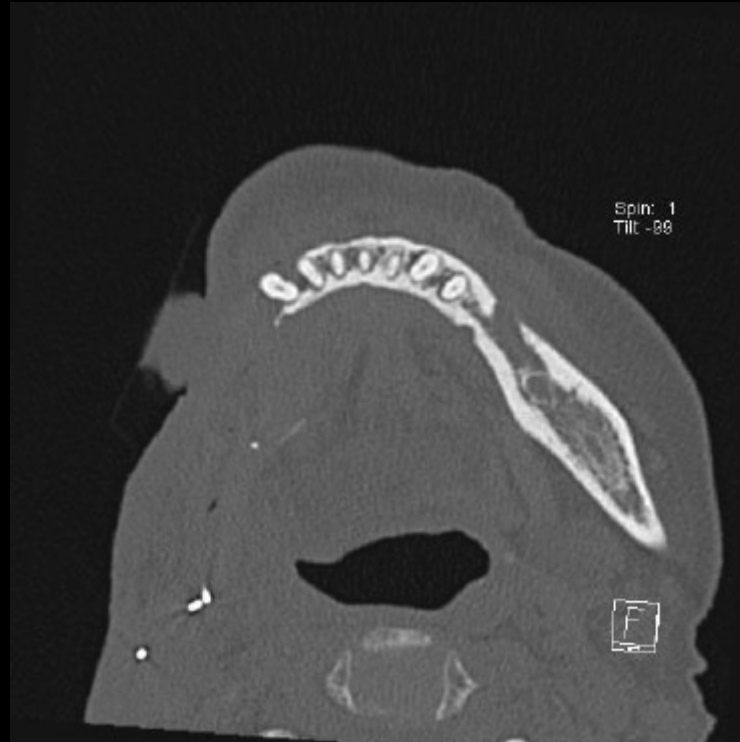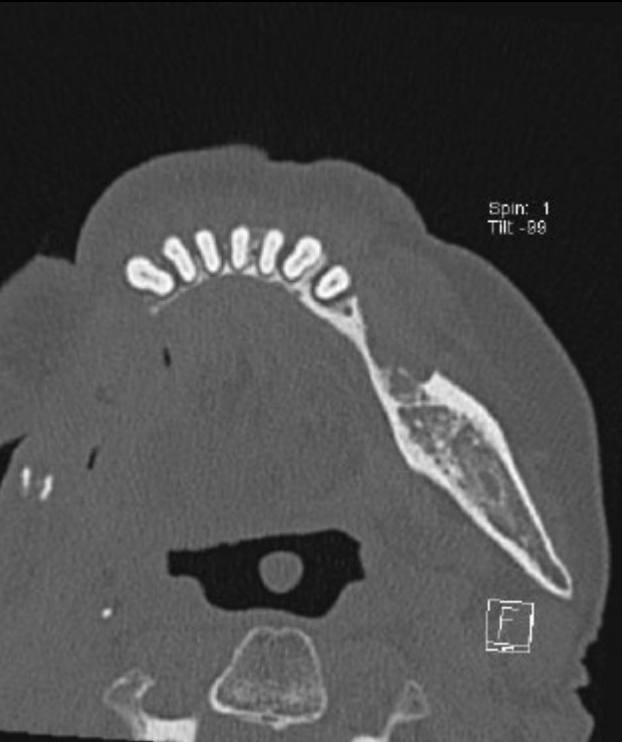Patiente traitée par radiothérapie pour tumeur maligne du cavum

Vient pour douleurs localisées mandibulaires droites

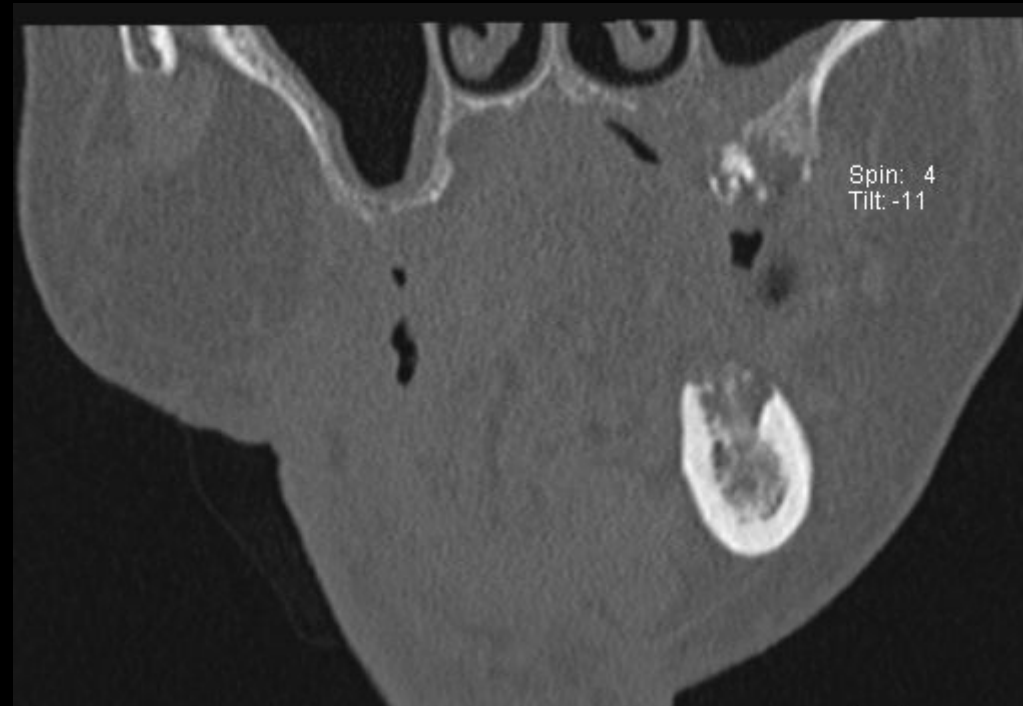
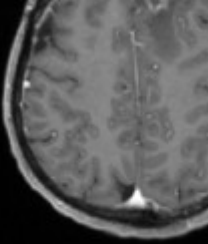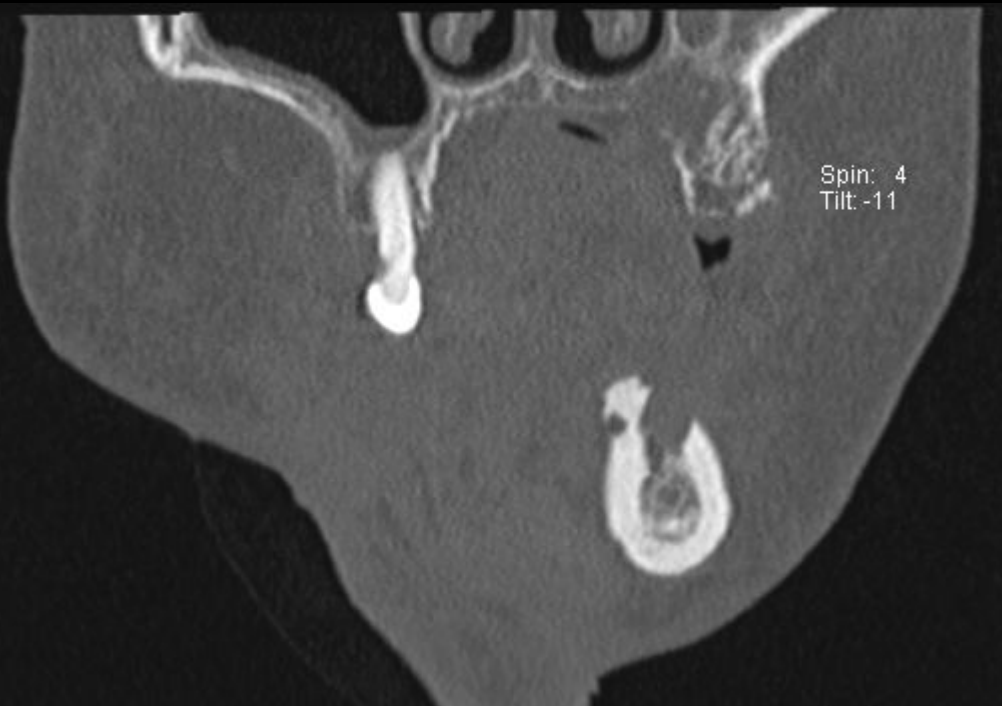
# Cas clinique 5



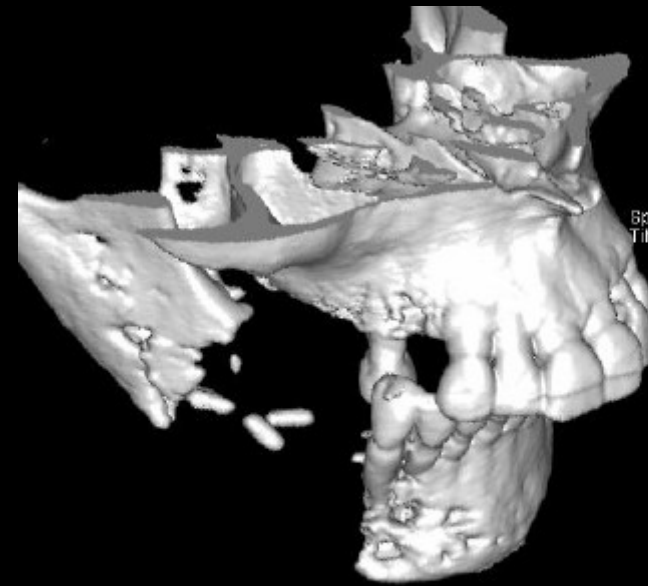
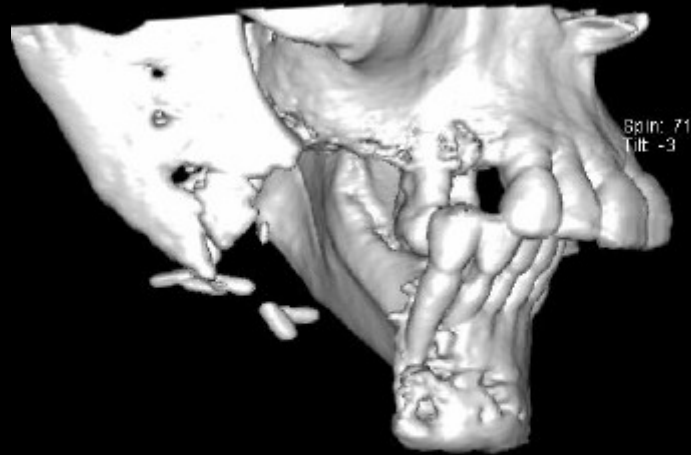
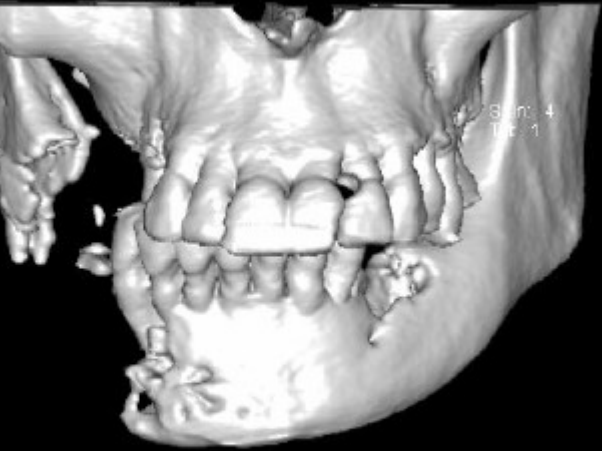
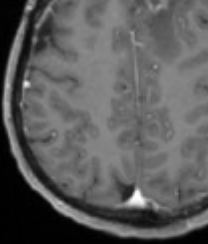
# Cas clinique 6



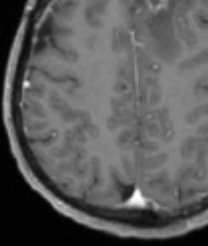
# Cas clinique 6



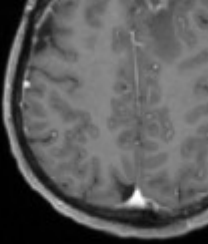
# Cas clinique 6



# Complication ?

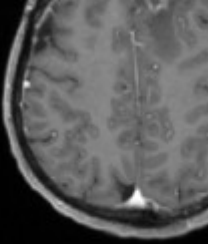


# Complication ?



Ostéoradionécrose mandibulaire

# Complication ?



## Ostéoradionécrose mandibulaire

Etiologie :

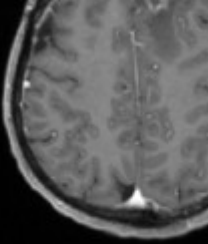
Sclérose post-radique des branches terminales de l'artère dentaire inférieure

Atteinte ostéoblastique plus importante que celle ostéoclastique

Hyposialie favorisant les caries



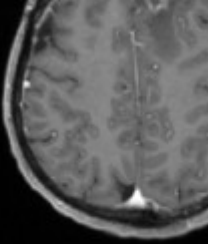
# Complication ?



## Ostéoradionécrose mandibulaire

Facteurs favorisants :

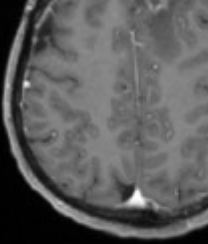
# Complication ?



## Ostéoradionécrose mandibulaire

Facteurs favorisants : Liés au patient

# Complication ?



## Ostéoradionécrose mandibulaire

Facteurs favorisants : Liés au patient

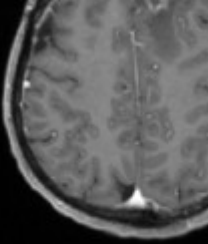
Mauvaise hygiène bucco-dentaire

Dénutrition

Artériopathie

Intoxication alcoolo-tabagique

# Complication ?

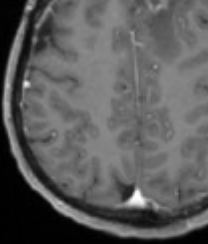


## Ostéoradionécrose mandibulaire

Facteurs favorisants : Liés au traitement



# Complication ?



## Ostéoradionécrose mandibulaire

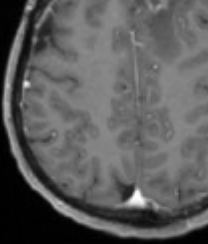
Facteurs favorisants : Liés au traitement

Dose supérieure à 60 Gy dans un volume étendu

Irradiation trop précoce après extraction dentaire

Curiethérapie interstitielle au voisinage sans protection plombée

# Complication ?

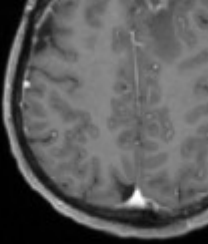


Radionécrose cérébrale

Ostéoradionécrose mandibulaire



# Complication ?



Radionécrose cérébrale

Ostéoradionécrose mandibulaire

Rare

Grave

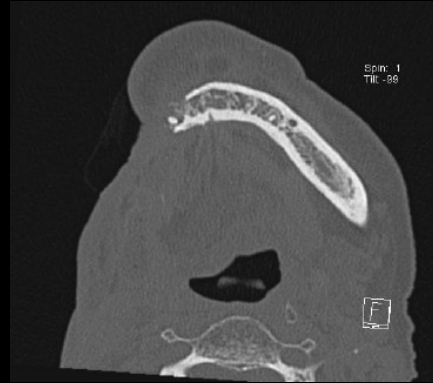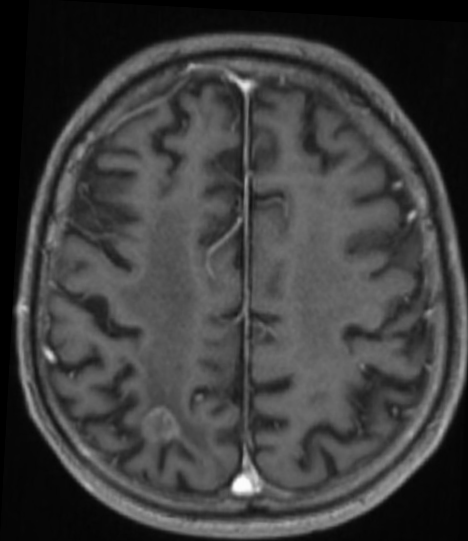
Retardée

---

# Remerciements

Denis Bossard, Lyon





Merci

