Imagerie multimodale des tumeurs cérébrales-SFRRA

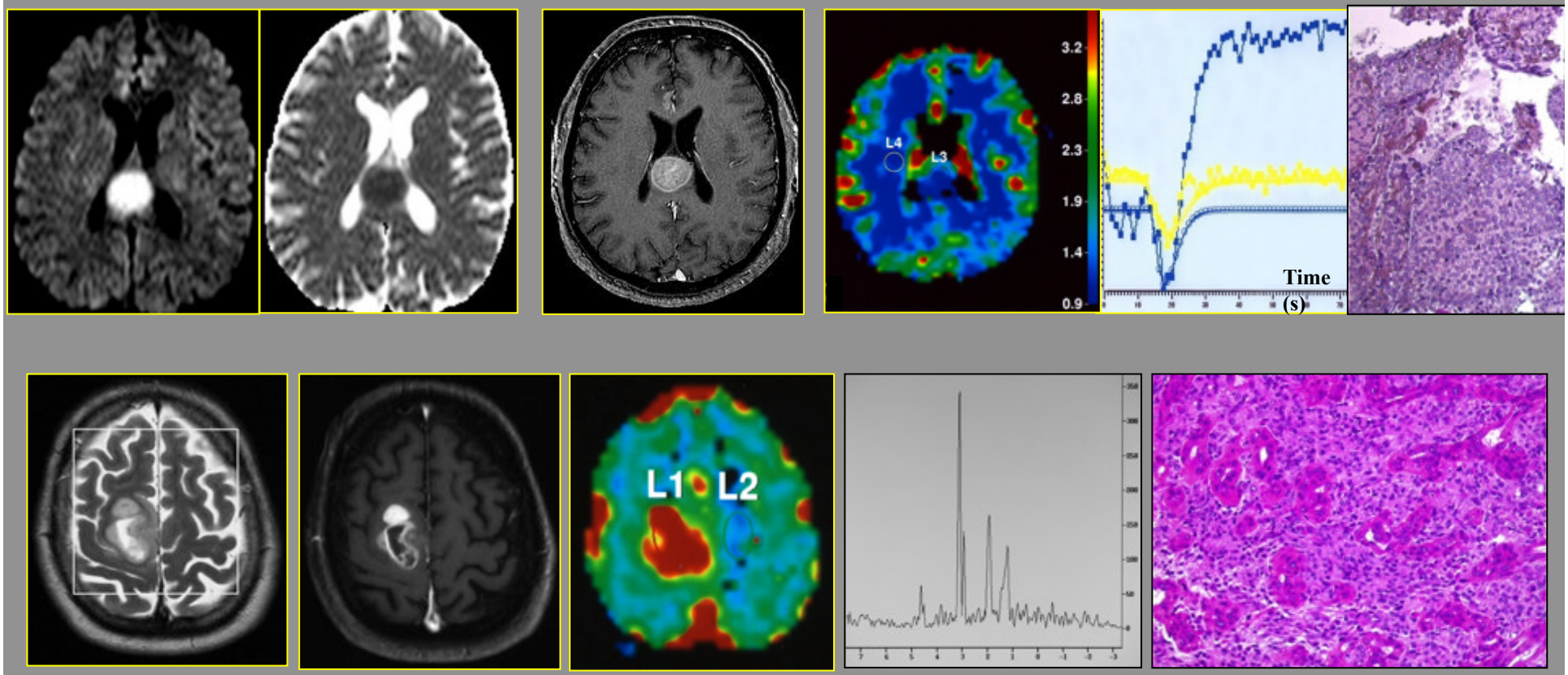

Samedi 24 mars 2012

Pr. François Cotton
Dr Jean Amédée Roch

Service d'imagerie, CHLS

Laboratoire d' Anatomie, UFR Laennec

CREATIS

OBJECTIFS PEDAGOGIQUES

1- Connaître le protocole d'acquisition de l'IRM multimodale pour explorer une tumeur du SNC.

2- Connaître l'évolution naturelle des gliomes de bas grade.

3- Connaître la caractérisation en IRM multimodale des principales lésions prenant le contraste

5- Connaitre les aspects en perfusion de l'astrocytome pilocytique et le profil métabolique de la gliomatose cérébrale.

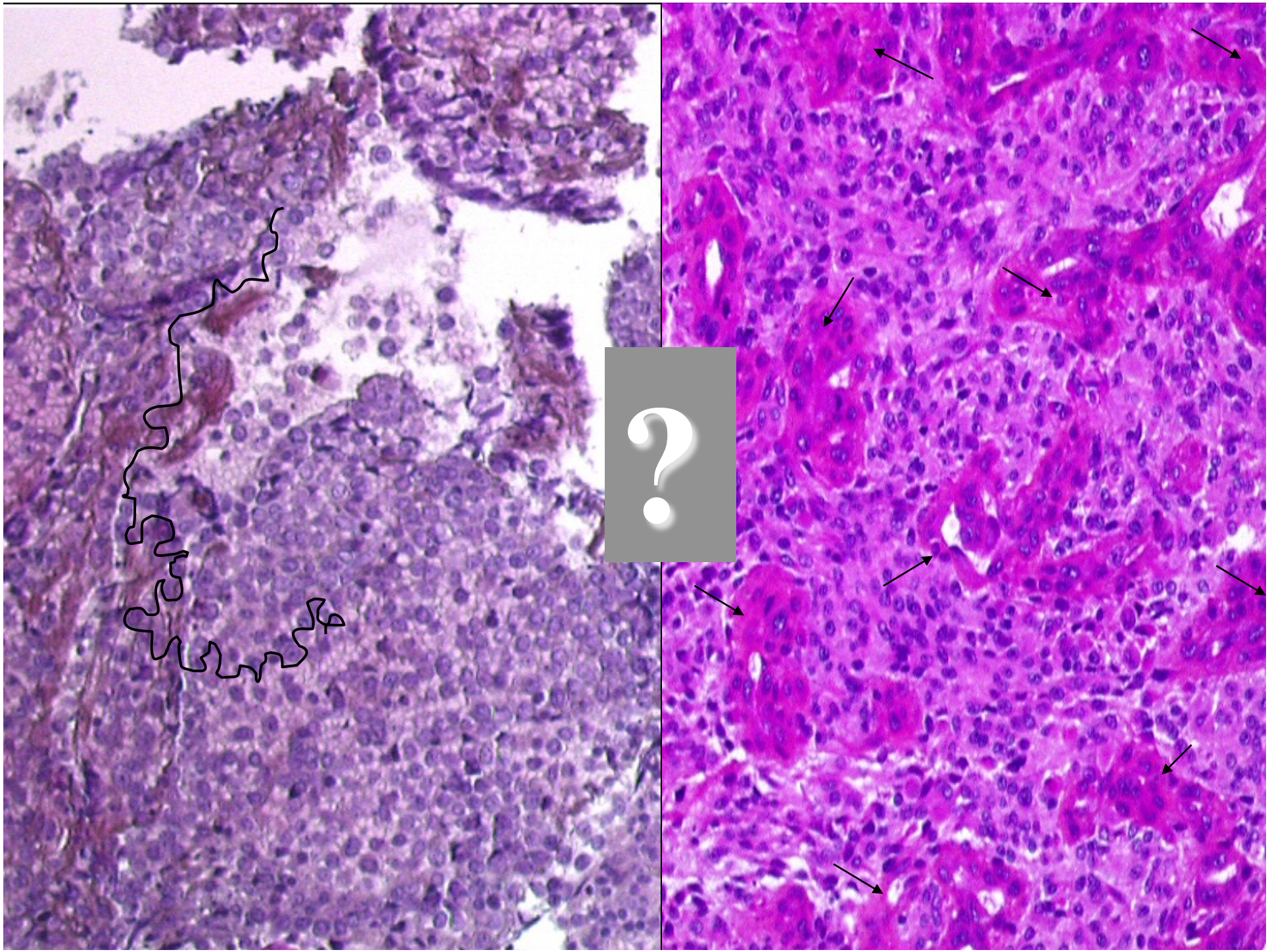

Approche multidisciplinaire, RCP ++

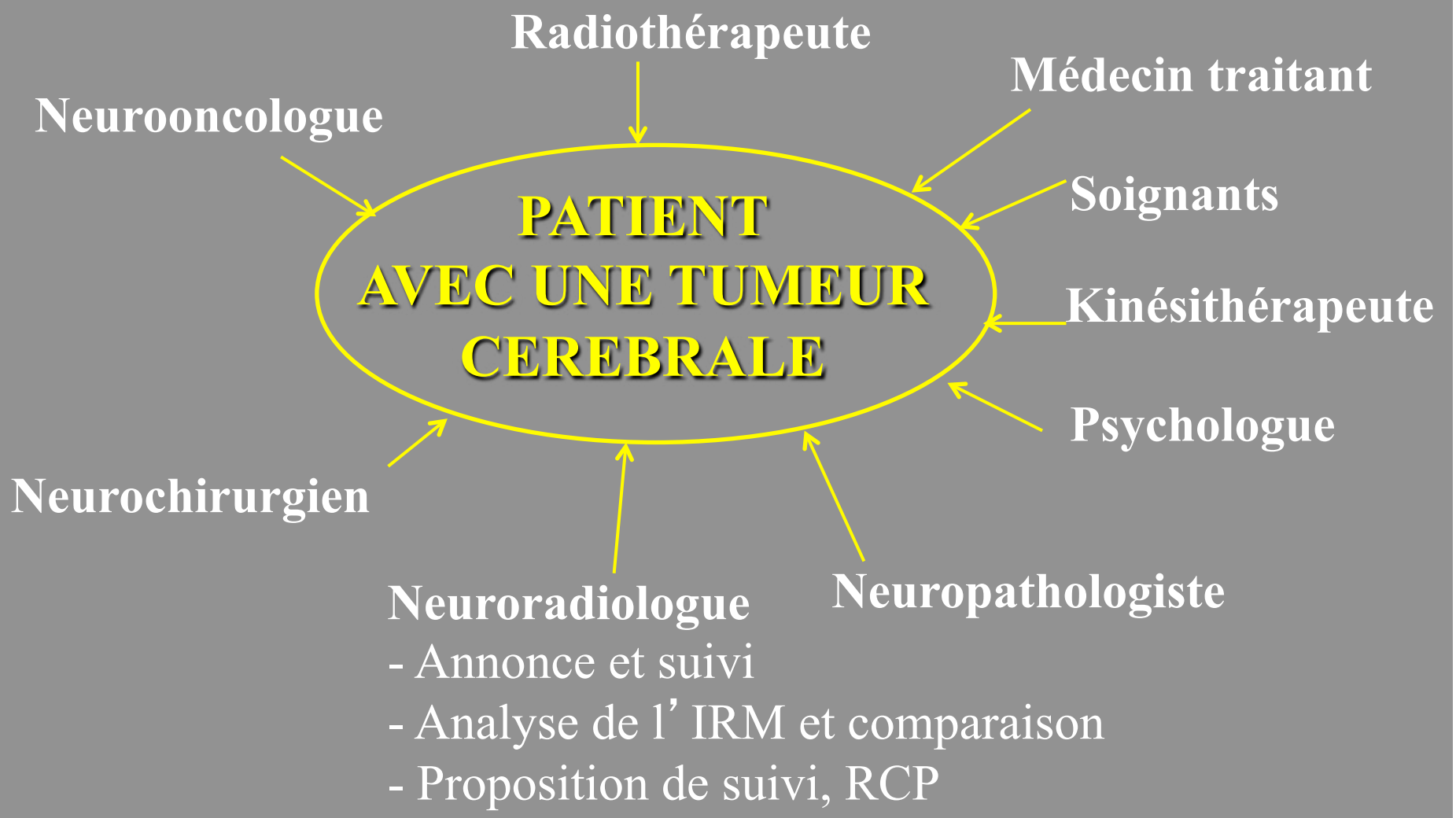

- Annonce et suivi
- Analyse de l'IRM et comparaison
- Proposition de suivi, RCP

Protocole d'acquisition

- T2 ou FLAIR 2D ou 3D (3 Tesla ++) [4-5mn]
- Diffusion [1mn]
- T2* ou imagerie de susceptibilité magnétique [4-5 mn]
- Perfusion (avant le T1, double pompe) [1mn]
- T1 après injection de chélates de gadolinium (2D axial ou 3D ++) [4-5mn]
- Spectroscopie proton monovoxel dans la lésion [2-3mn]

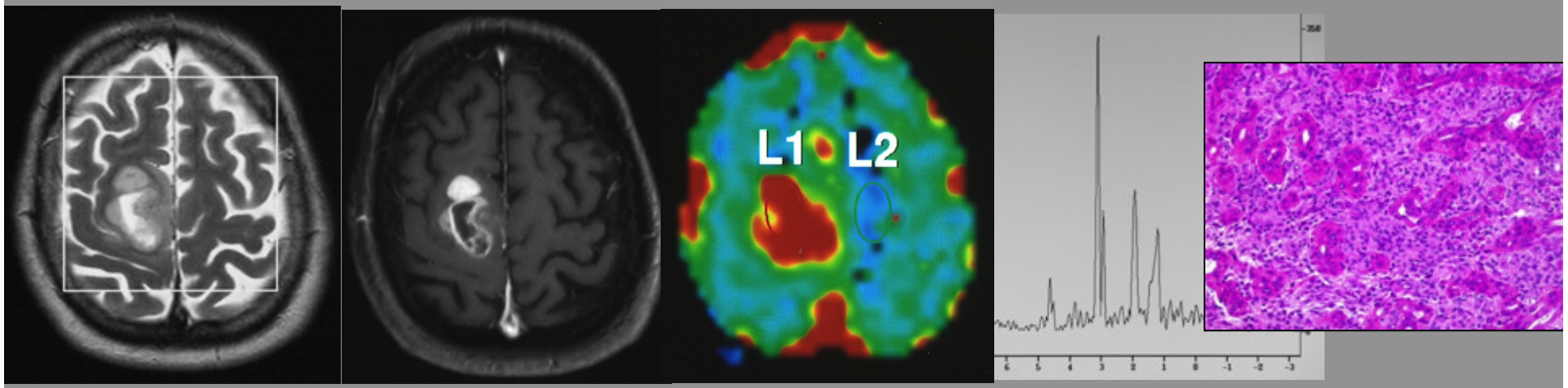

Durée d'acquisition: moins de 20 minutes

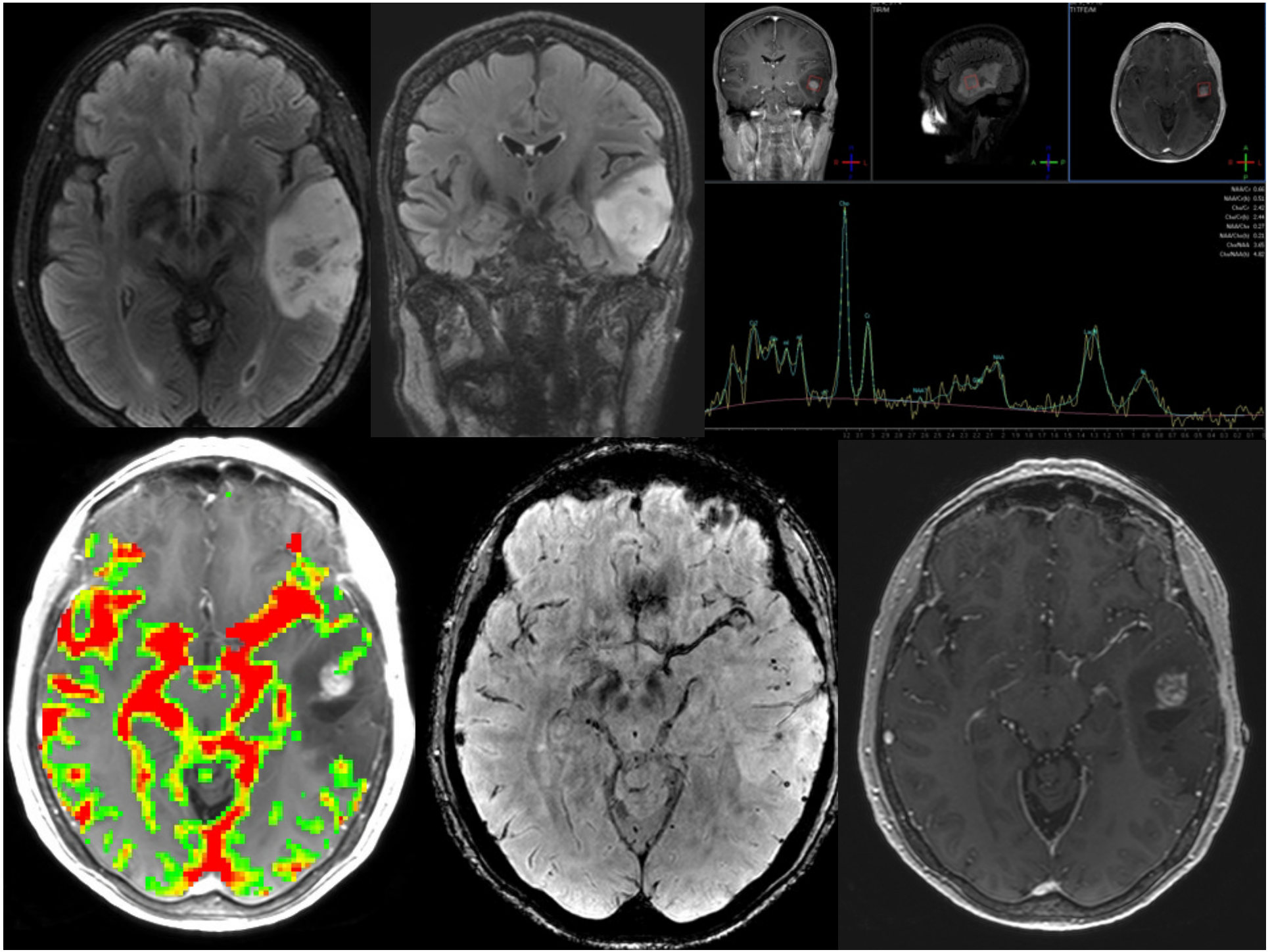
T1TFEAM
NAA/Cr 0.66
NAA/Cr(b) 0.51
Cho/Cr 2.42
Cho/Cr(b) 2.44
NAA/Cho 0.27
NAA/Cho(b) 0.21
Cho/NAA 3.65
Cho/NAA(b) 4.82
Cho
Cr
NAA

I TECHNIQUE (spectroscopie, perfusion)

II APPLICATIONS en neuro-oncologie

1- Caractérisation tissulaire et histoire naturelle des gliomes

2- Diagnostic différentiel entre gliomes de haut grade et lésions présentant une rupture de la BHE

⇒ Métastases

⇒ Lymphomes

3- Ciblage, intérêt potentiel de la perfusion

4- Suivi

- Nécrose versus abcès
- Récidive versus radionécrose

5- Cas particuliers

- Astrocytome pilocytique vs hémangioblastome
- Gliomatose cérébrale

IA- Spectroscopie proton

IRM « anatomique »: structure des tissus en fonction de H20

Spectroscopie: structure des molécules après élimination d'H20

Spectre normal
TE long [270 ms]

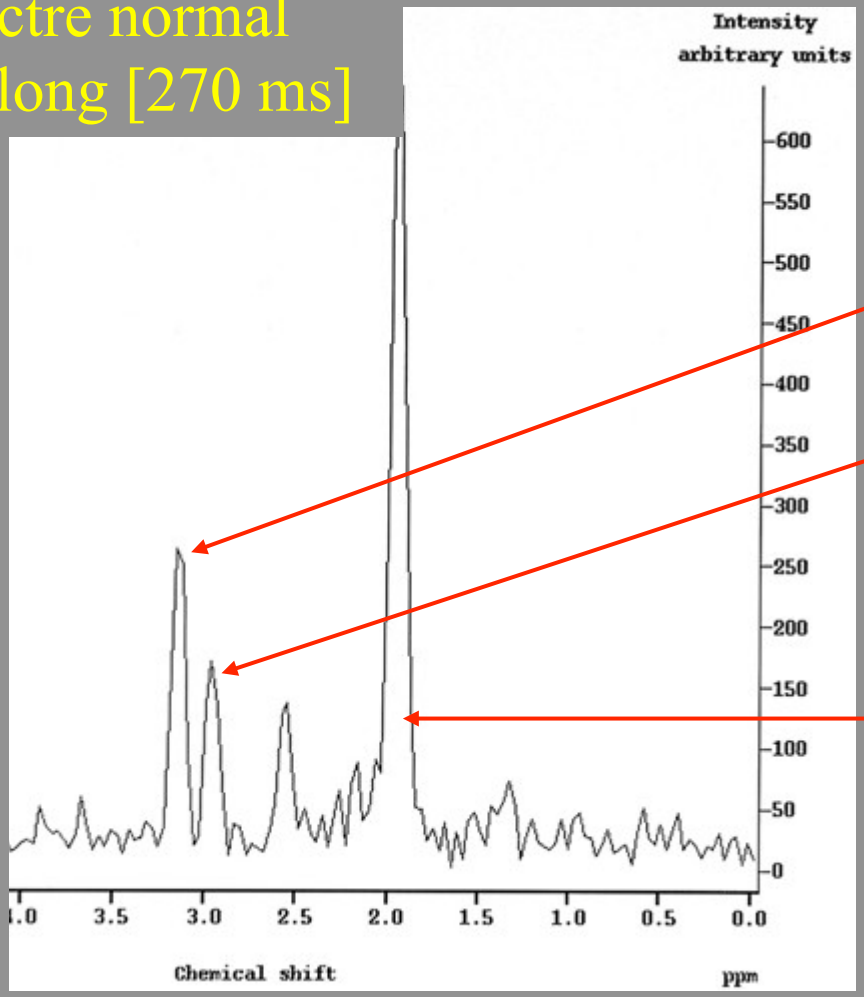

Eau (5 ppm)

Myo-inositol (3,6 ppm):
Marqueur glial (gliose)

Choline (3,2 ppm):
Marqueur membranaire (SEP, turn-over)

Créatine (3 ppm):
Marqueur du métabolisme énergétique

Glutamate (2,2-2,4 ppm)
Neurotransmetteur d'excitation

N-acétyl-aspartate (2 ppm):
Marqueur neuronal

Lipide-Lactate (1,3 ppm):
Marqueur de souffrance anoxique

ACQUISITION

Monovoxel, à TE court

- plus de métabolites explorés
- couverture réduite
(en général supérieure à 10*10*10 mm)
- Monovoxel controlatéral

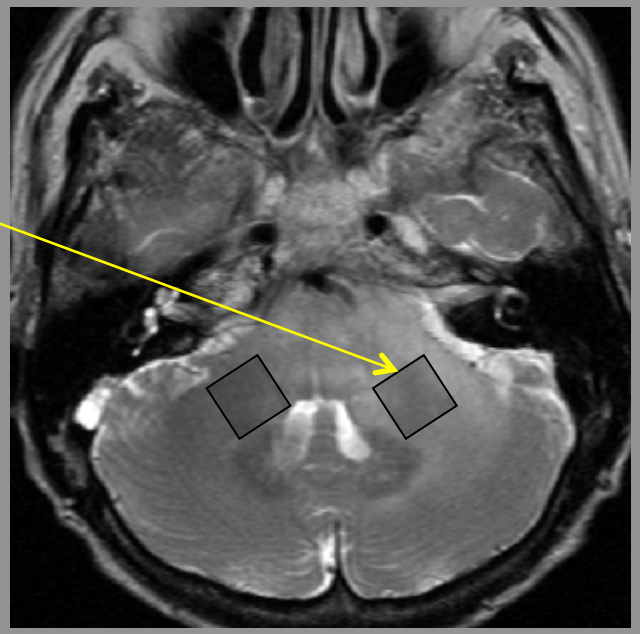

Multivoxel, mono ou multicoupes et imagerie spectroscopique:

- moins de métabolites explorés (TE long)
- couverture plus large de la coupe ou d'un volume

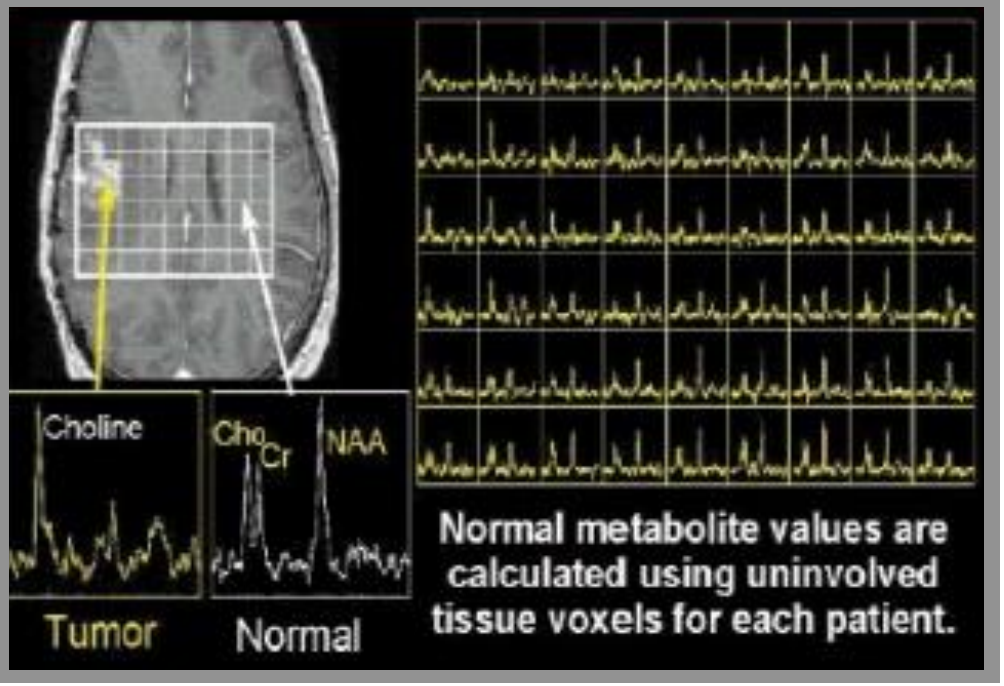

Principaux métabolites (ppm)

Métabolites	Pic (ppm)
Eau	5
NAcétyl-aspartate (NAA)	2
Créatine	3
Choline (Cho)	3.2
Glutamate-Glutamine (Glx) *	2.2 à 2.4
Myo-inositol (mI)	3.6
Lipides	0.9-1.3
Lactate	1.33
Acide aminés (**alanine**, aspartate, valine, leucine)	Mutiplets à 0,9-1,5 Alanine: 1,48 ppm

** Les métabolites non surlignés en gras sont uniquement visibles en TE court*

Quelques exemples de profils métaboliques à TE court dans les tumeurs

SB normale

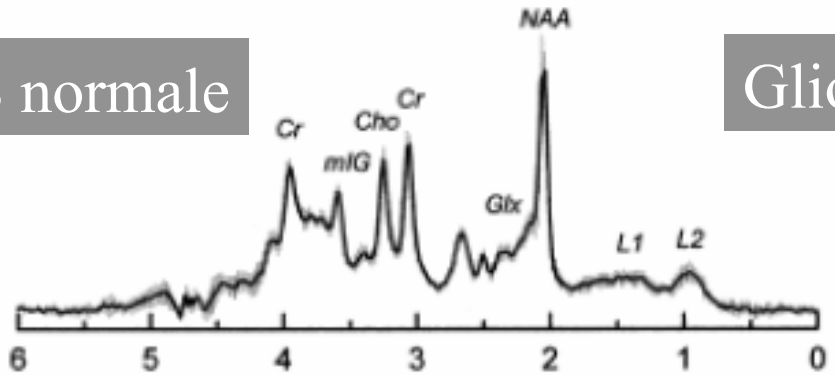

Gliome bas grade

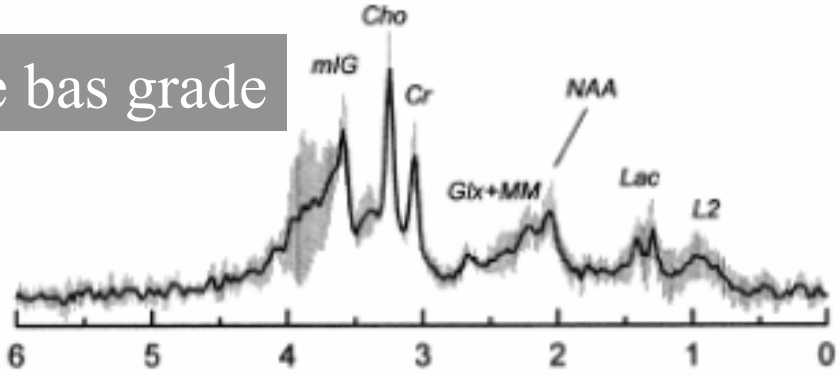

Méningiome

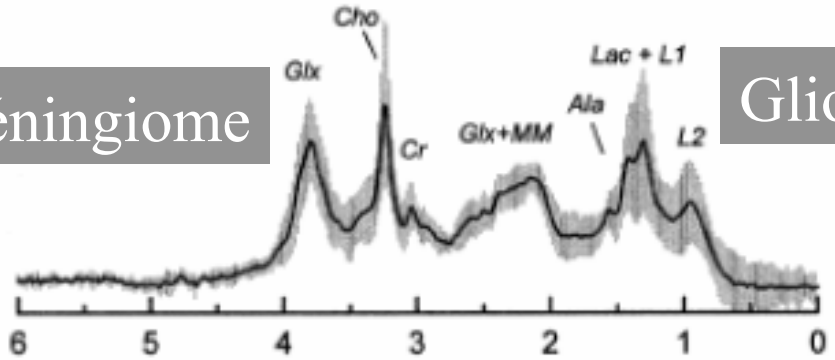

Gliome anaplasique

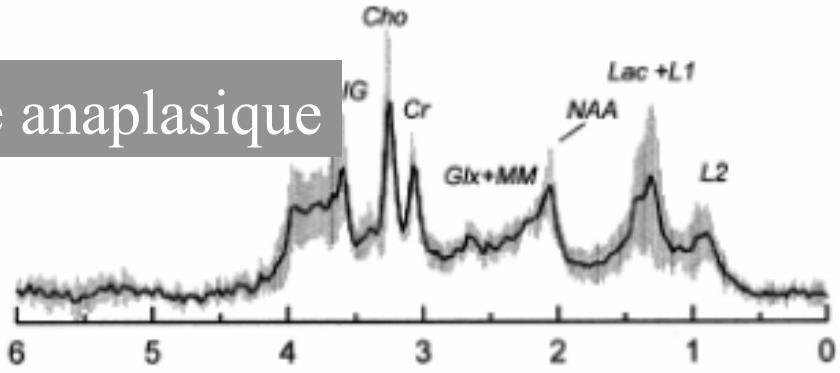

Métastase

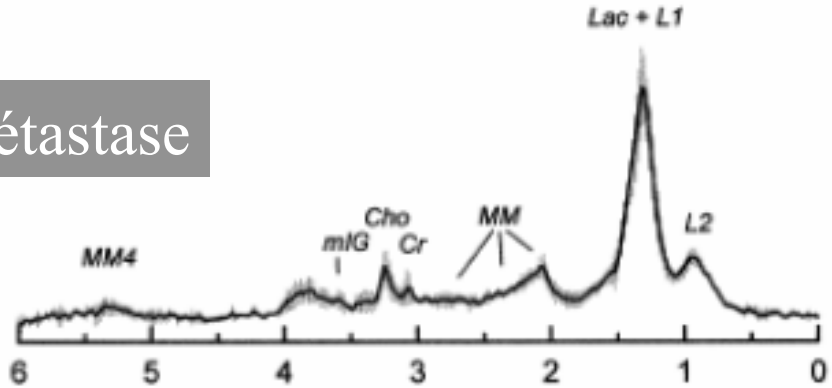

Glioblastome



IB- DIFFUSION

Hypersignal en diffusion avec ↓ du CDA
=marqueur de cellularité et non du grade

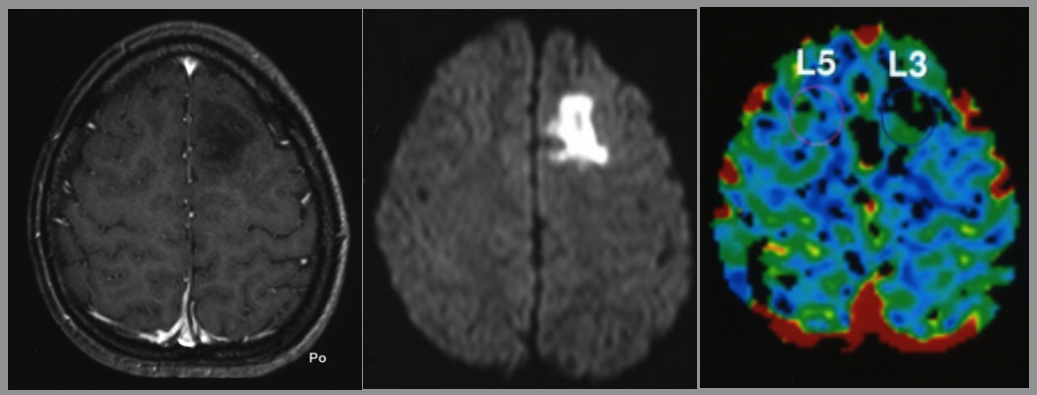

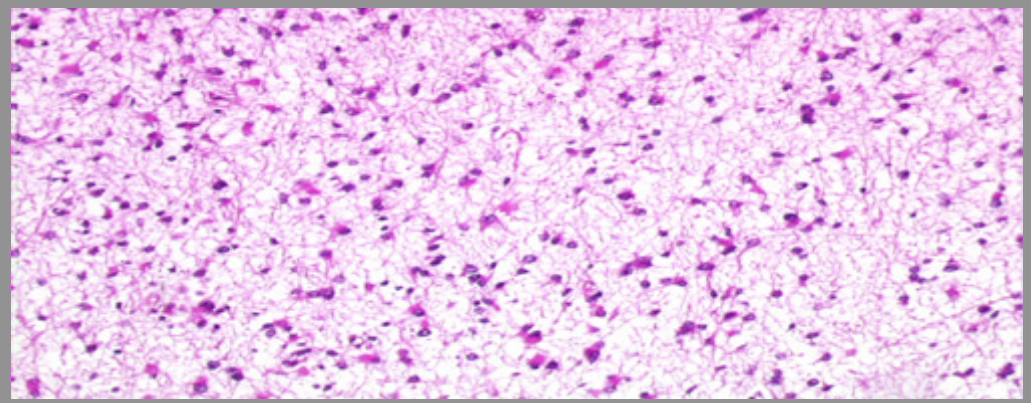

Oligodendrogliome
de bas grade

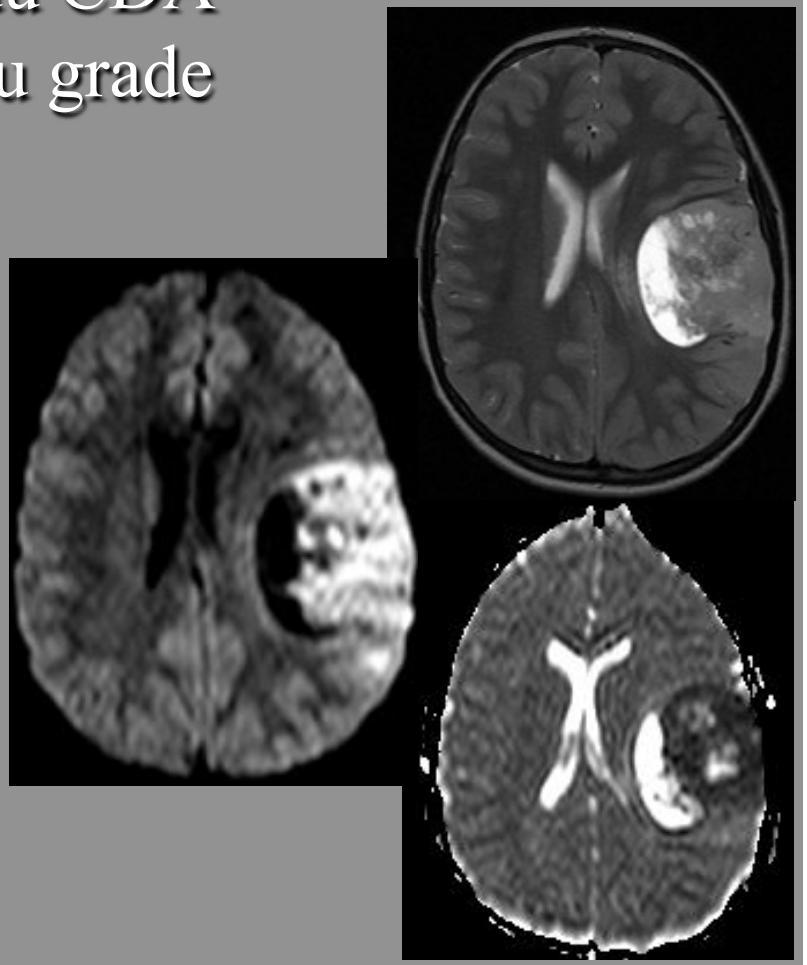

Tumeur neurogliale maligne

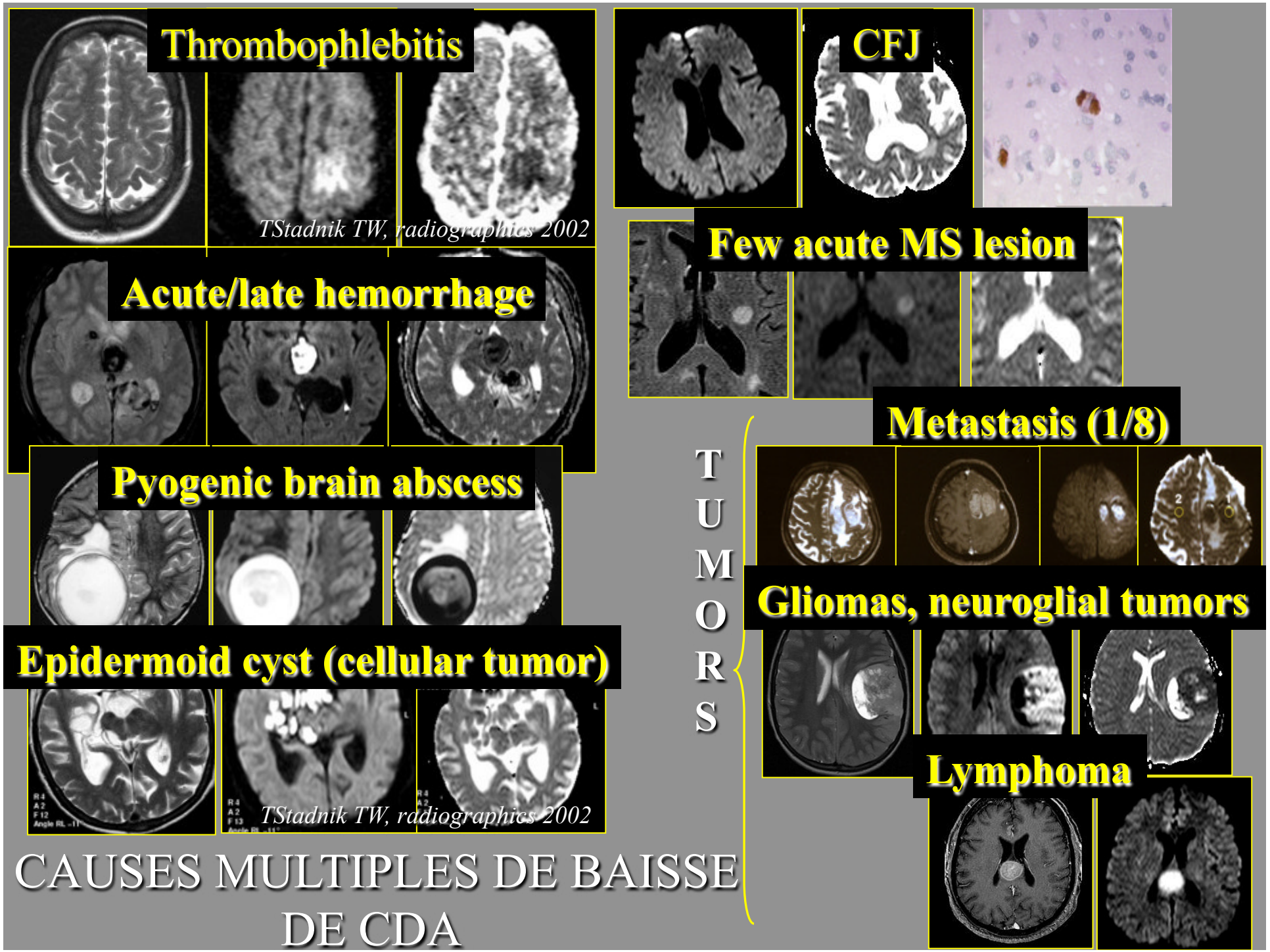
Thrombophlebitis
TStadnik TW, radiographics 2002
CFJ
Few acute MS lesion
Acute/late hemorrhage
Pyogenic brain abscess
Metastasis (1/8)
TUMORS
Gliomas, neuroglial tumors
Epidermoid cyst (cellular tumor)
Lymphoma
TStadnik TW, radiographics 2002
CAUSES MULTIPLES DE BAISSE DE CDA

IC- PERFUSION

Acquisition
- Antenne SENSE Head
- T2*
- Rapidité: résolution temporelle 1 seconde, durée: **1 mn**
- 24 coupes; matrice 94*128

Injection: débit de 6 ml/s
0,2 ml/kg, PDC de haute relaxivité T2
Rinçage avec 20 cc de sérum phy

Post-traitement:
- rCBV versus SB controlatérale (tumeur)
- Aspect de la courbe
- TTP, TO, MTT, CBF (AVC)

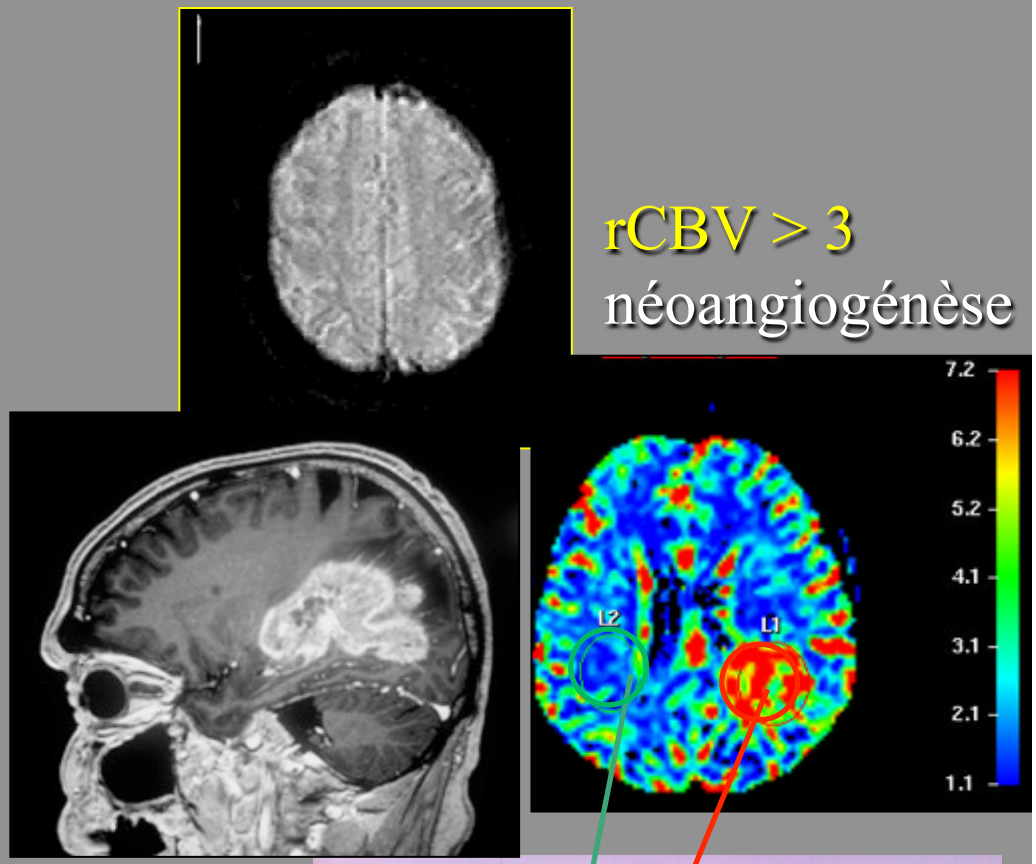

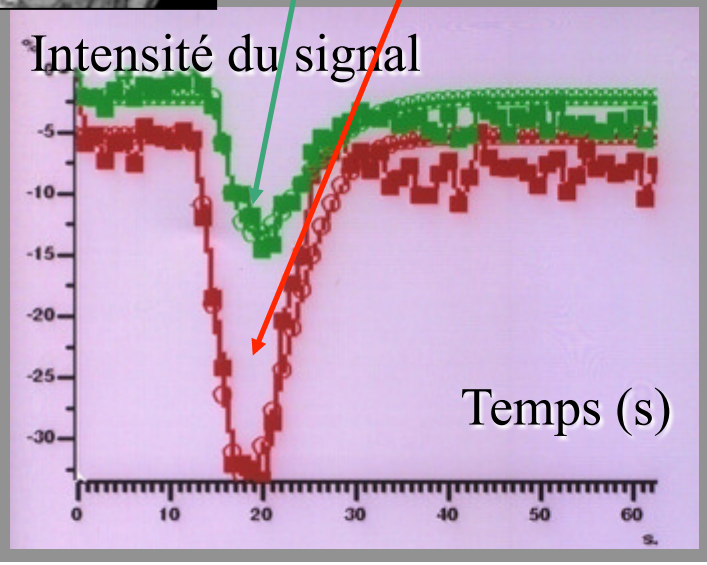

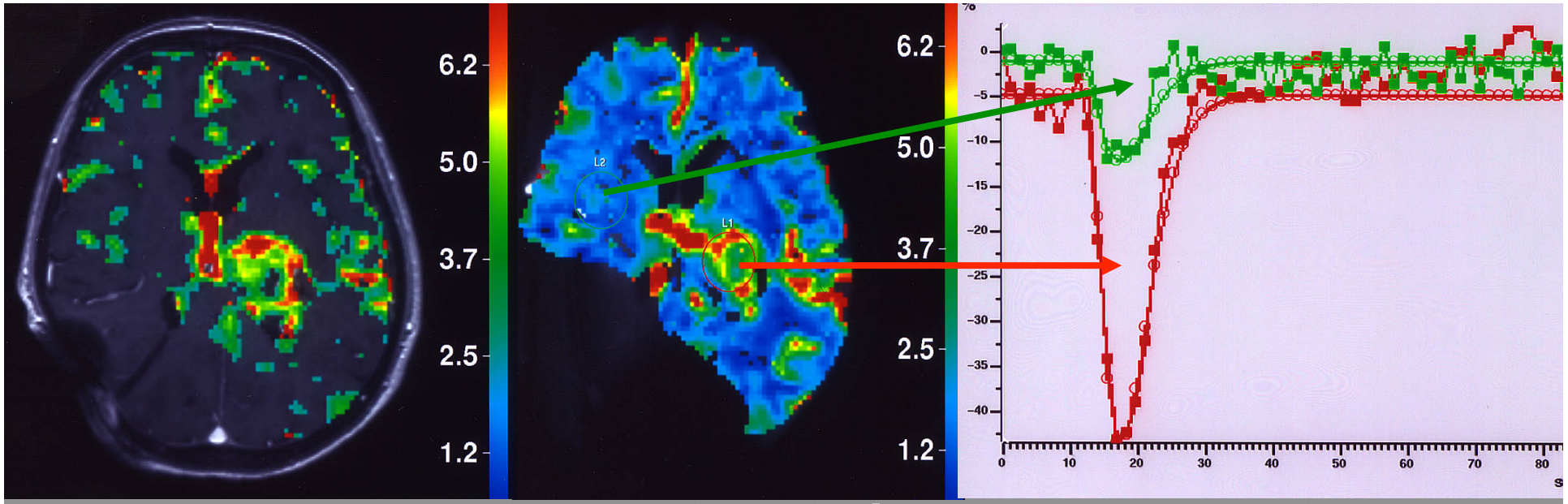

Post-traitement: rapide, possible si dérivation ventriculaire, fusion avec l'image morphologique

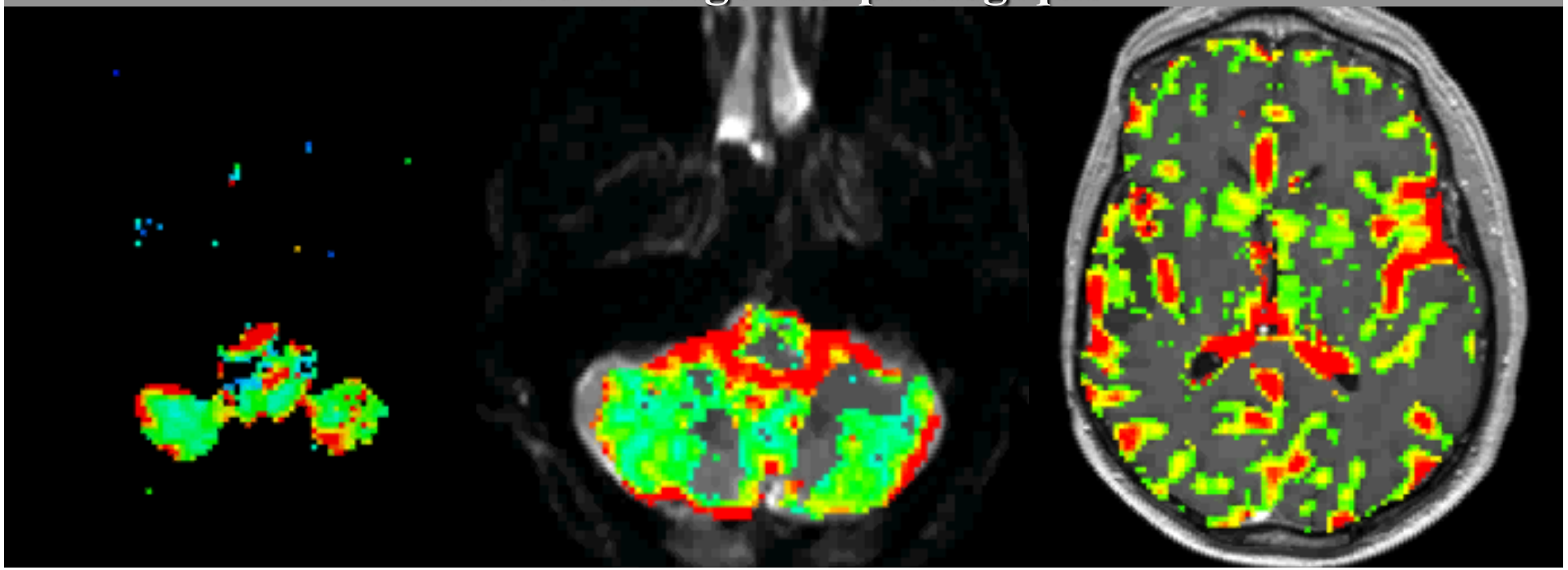

La prise de contraste = rupture de la BHE ≠ ↑ rCBV

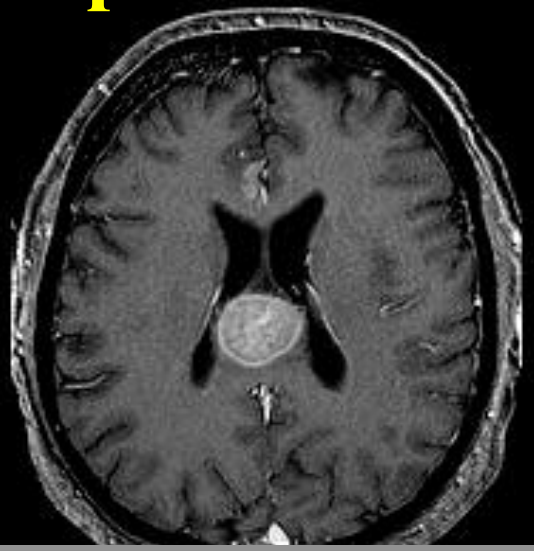

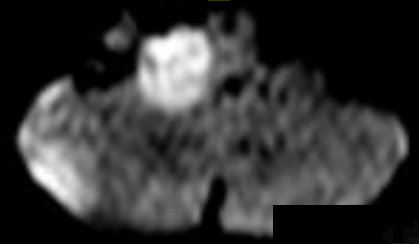

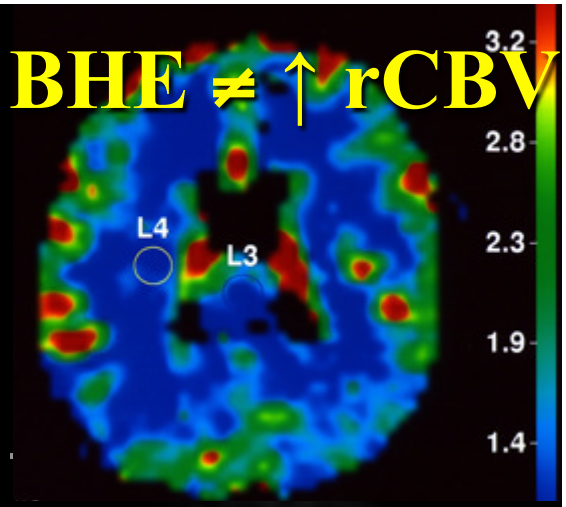

Lymphome cérébral primitif multifocal à grandes cellules B

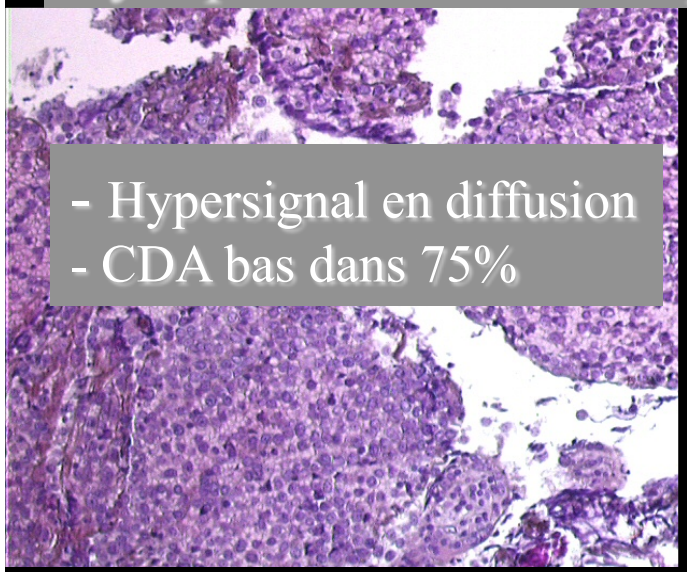

- Hypersignal en diffusion
- CDA bas dans 75%

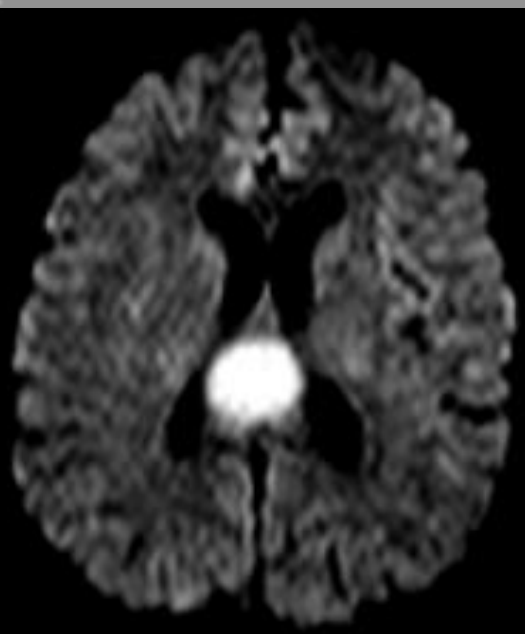

rCBV < 1.2

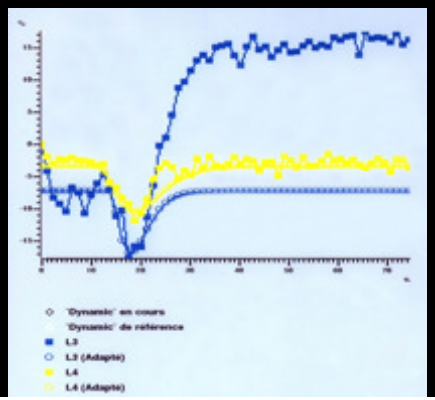

Cotton et al.,
J Neuroradiol. 2006

L'augmentation du rCBV ≠ Malignité

Carcinome des plexus choroïdes

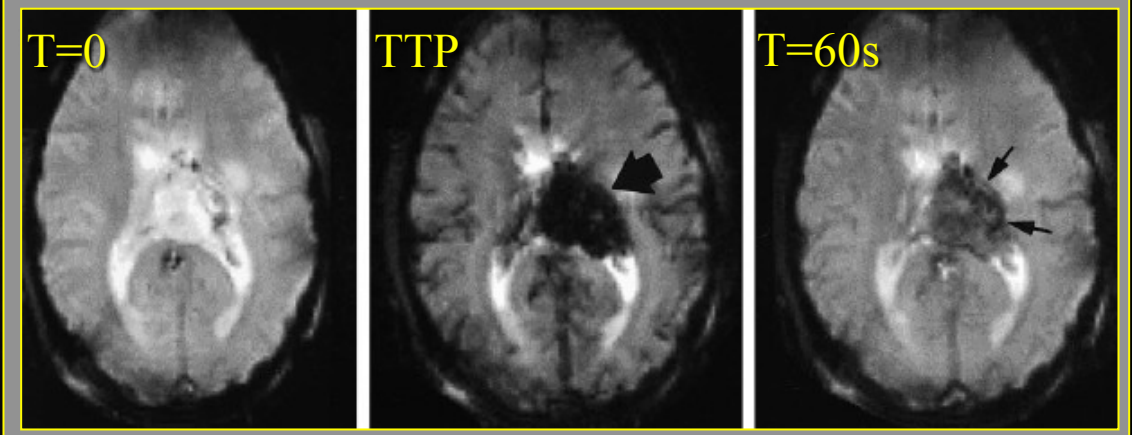

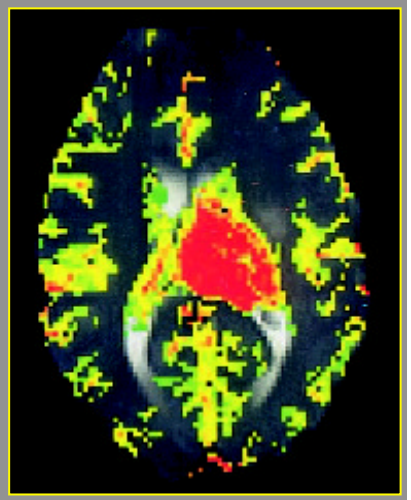

Méningiome

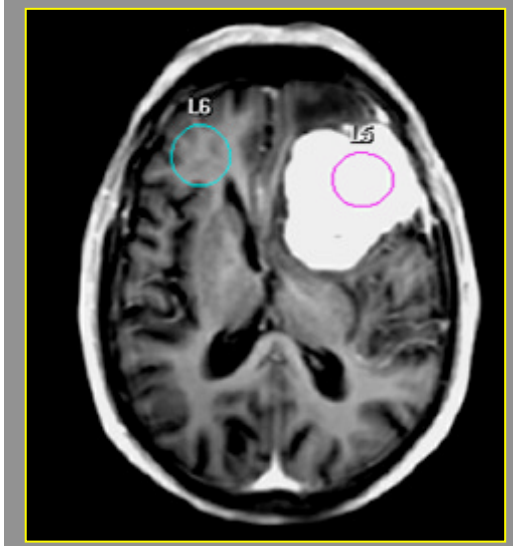

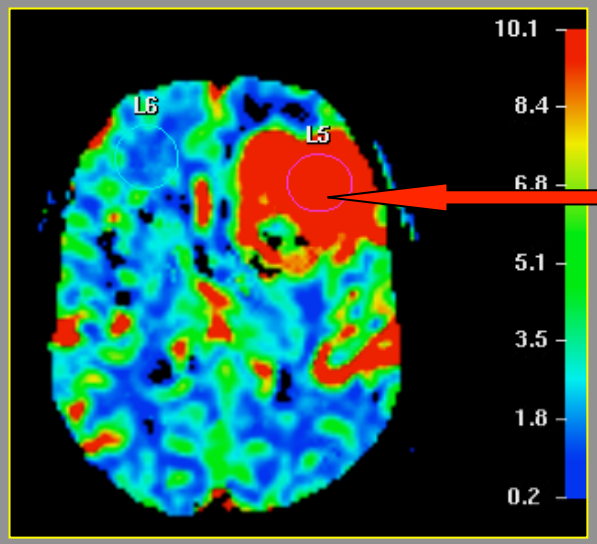

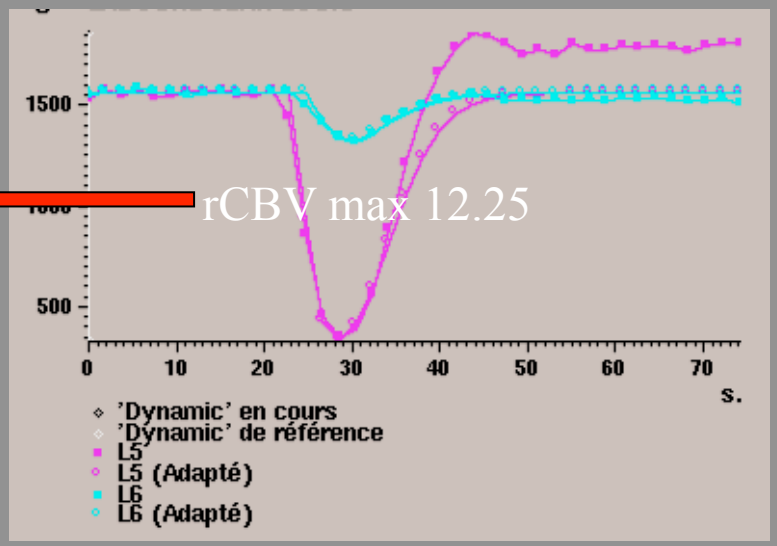

Fuite immédiate du PDC liée à l'absence de BHE, caractéristique des tumeurs extraaxiales

Patiente de 57 ans présentant un déficit progressif du membre inférieur droit.

Méningiome atypique refoulant le lobule paracentral gauche

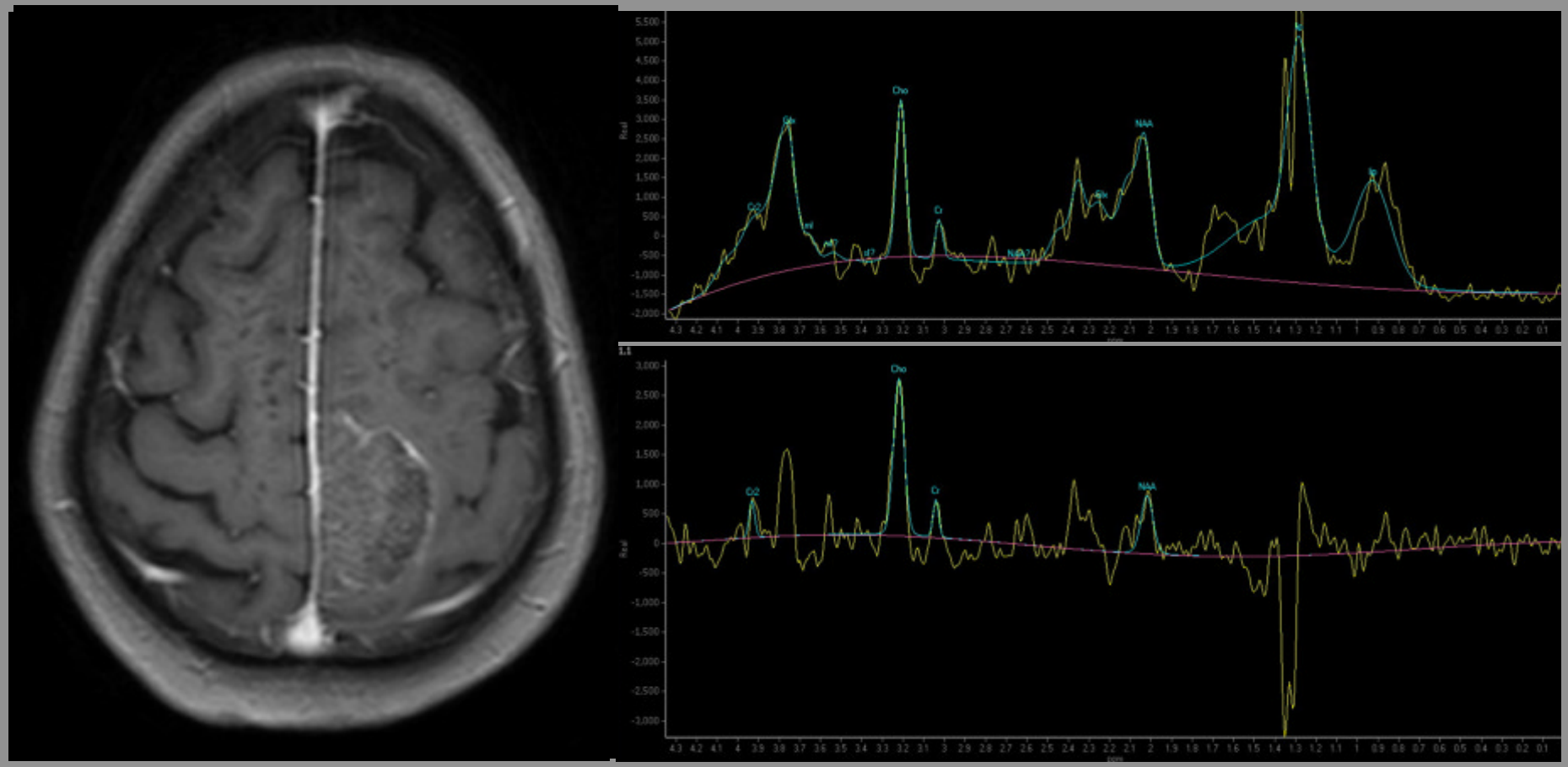

Pic d'alanine (1.48 ppm)

Comment différencier les métastases durales des méningiomes

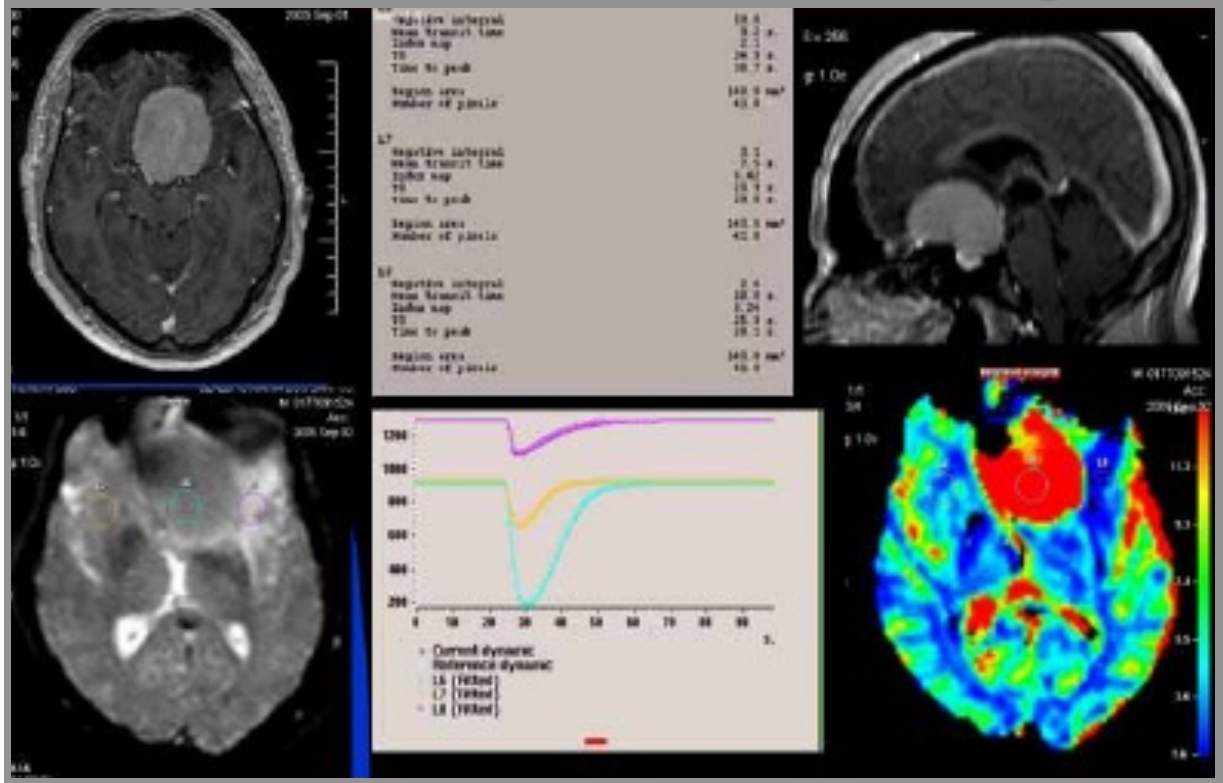

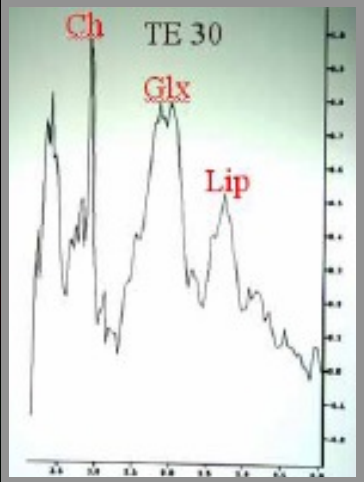

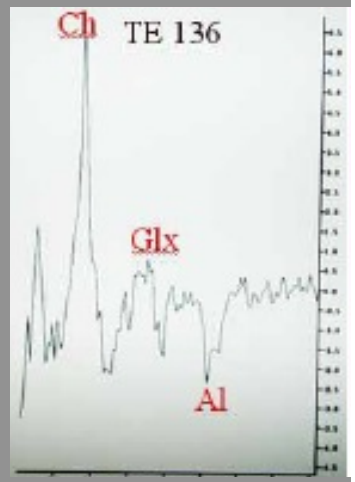

- **Perfusion:** rCBV plus bas (2-5) dans les métastases durales / méningiomes (8-10)
- **Spectroscopie:** pic d'alanine à 1,48 ppm dans les méningiomes; volumineux pic de lipide dans les métastases

II- APPLICATIONS EN NEUROONCOLOGIE

1- Caractérisation tissulaire des gliomes

Caractérisation des gliomes

Les tumeurs primitives du SNC (i: 10/100000) représente 2% de l'ensemble des cancers de l'adulte.

Les gliomes représentent 30% des tumeurs primitives du cerveau

	Astrocytome	Oligodendrogliome	Mixte	
Grade I	Astrocytome pilocytique			**> 20 ans**
Grade II	Astrocytome	Oligodendrogliome	Oligoastrocytome	**10-15 ans**
Grade III	Astrocytome anaplasique	Oligodendrogliome anaplasique	Oligoastrocytome anaplasique	**3-4 ans**
Grade IV	Glioblastome			**< 1 an**

Classification des gliomes (OMS)

Classification « moderne » des gliomes

Classification de Daumas-Duport (anapath +IRM)

Oligodendrogiomes et oligoastrocytomes de grade A :
Absence d'hyperplasies endothéliales et de prise de contraste

Oligodendrogiomes et oligoastrocytomes de grade B :
Hyperplasies et/ou prise de contraste

Glioblastomes

Daumas-Duport et al., Ann Pathol 2000; 20: 413-428

Oligodendrogliome de bas grade

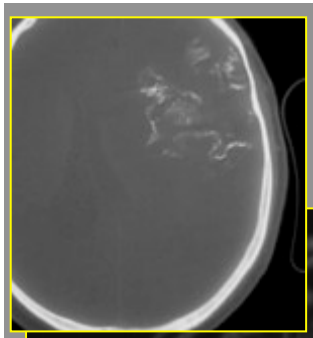

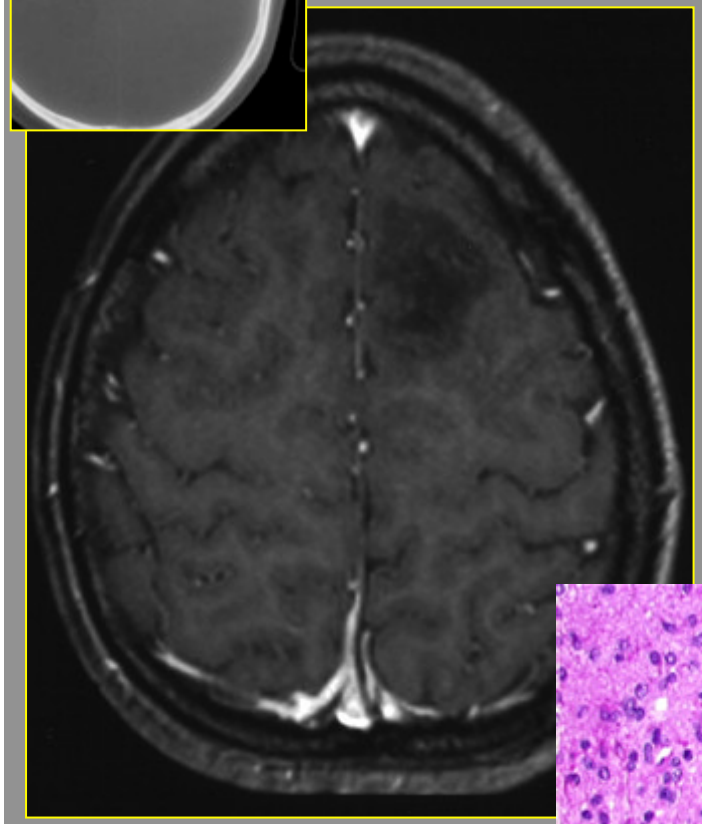

- hypodense
- Calcifications (1/3)
- hypo T1, hyper T2/FLAIR
- absence de PC
- SG et SB

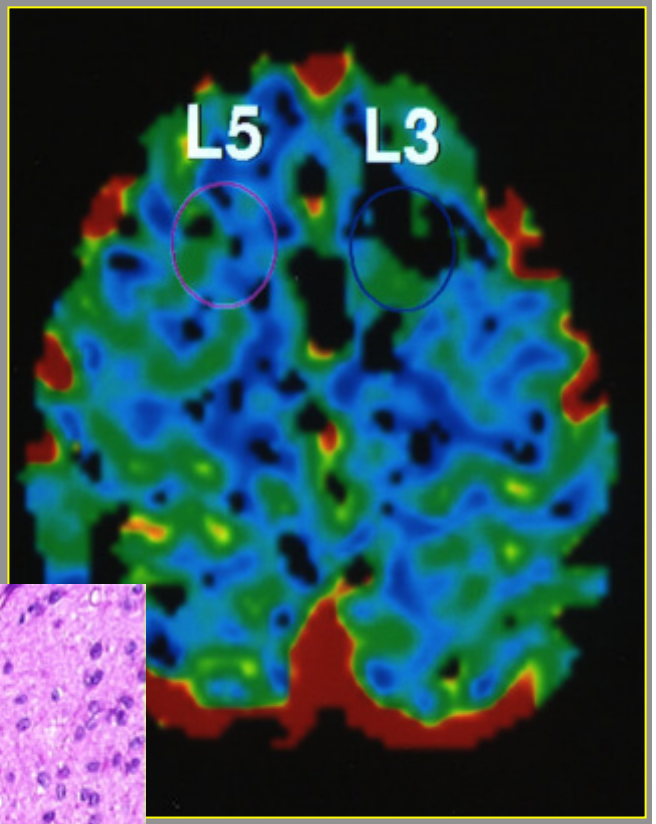

T1 après injection de Gadolinium

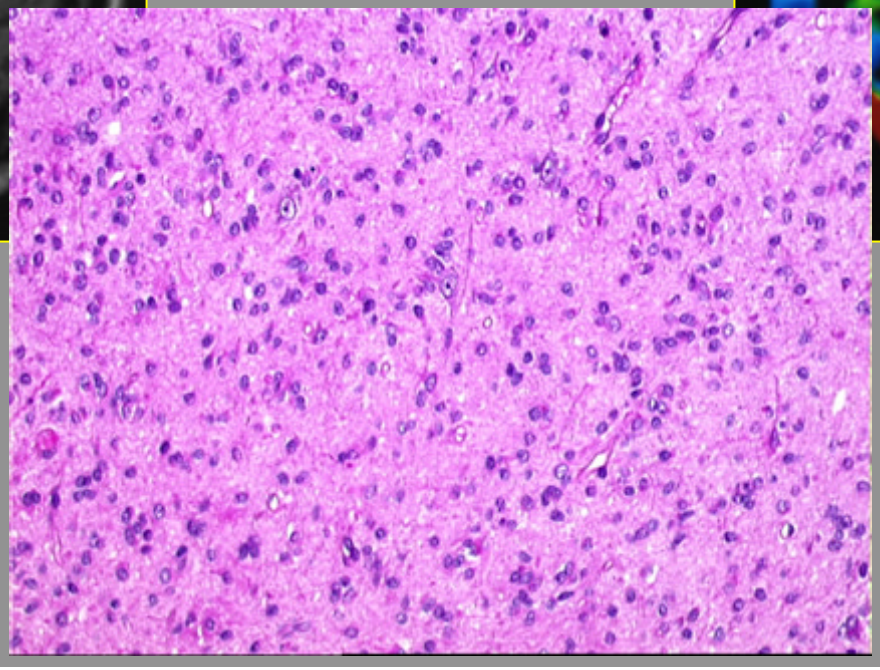

rCVB : 1.45

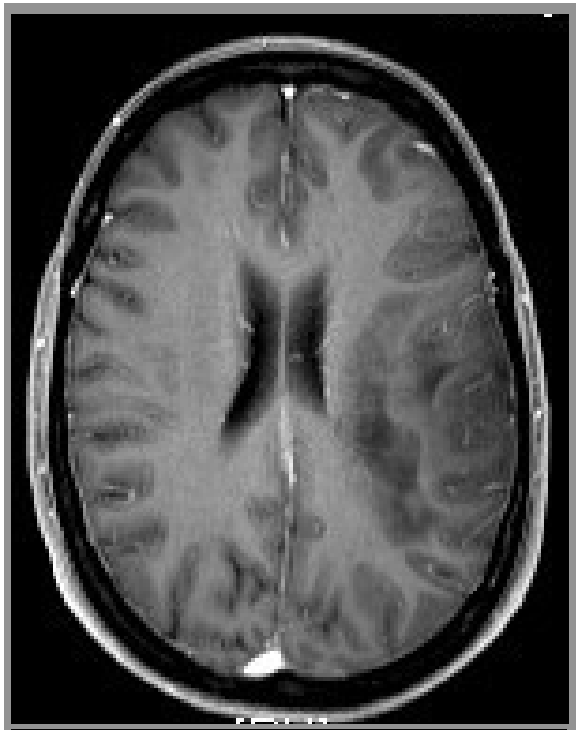

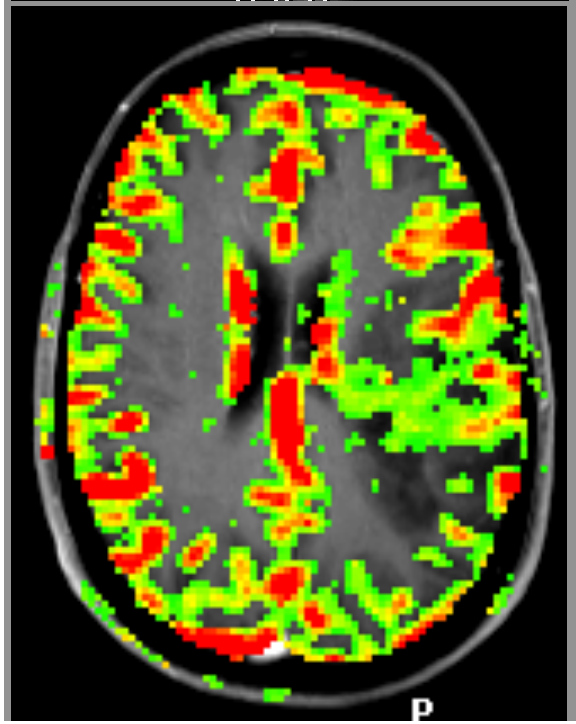

Patiente de 41 ans suivi pour un gliome de bas grade depuis 2 ans. Nouveau contrôle.

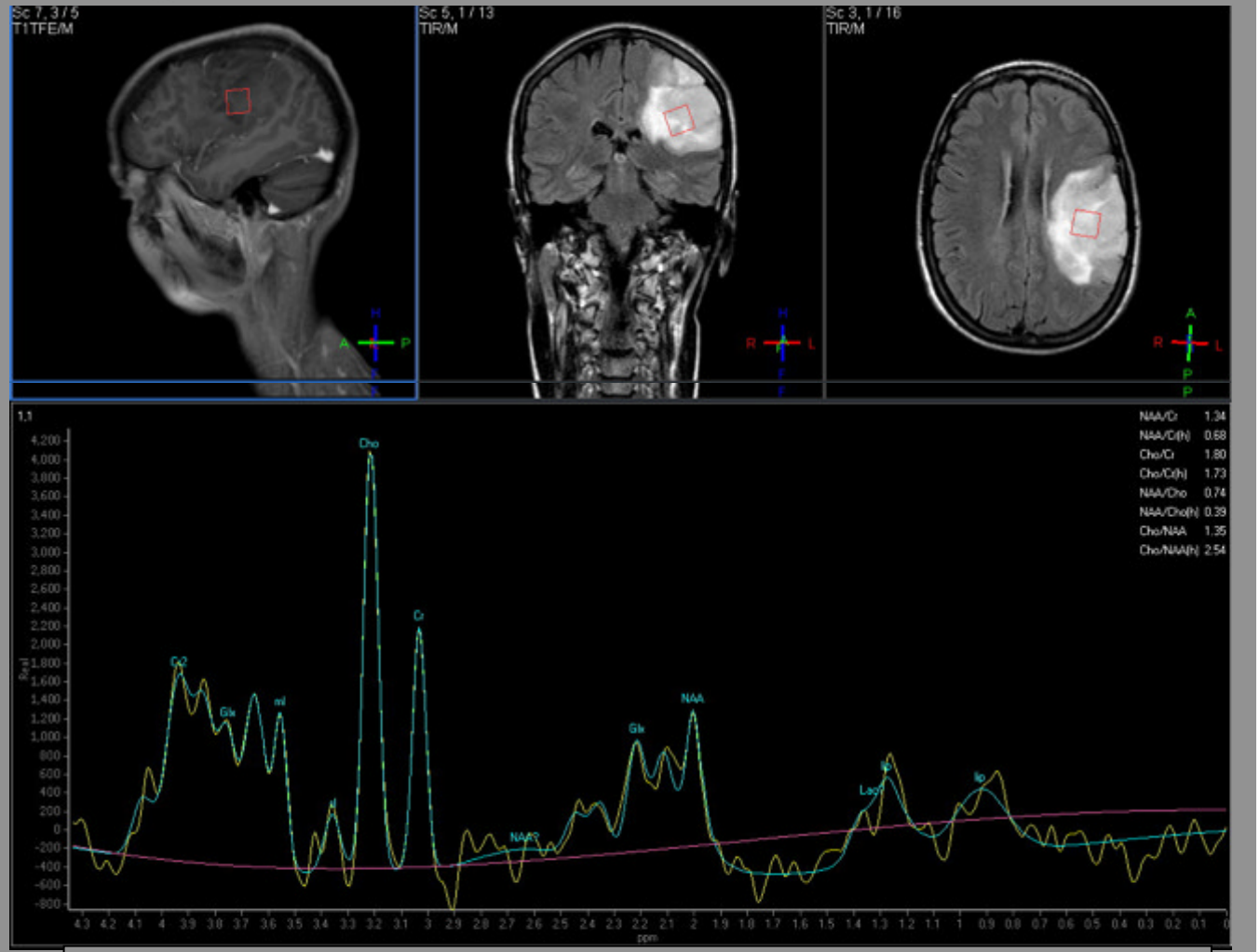

Virage anaplasique d'un gliome de bas grade 2 mois après

Oligodendrogliome anaplasique

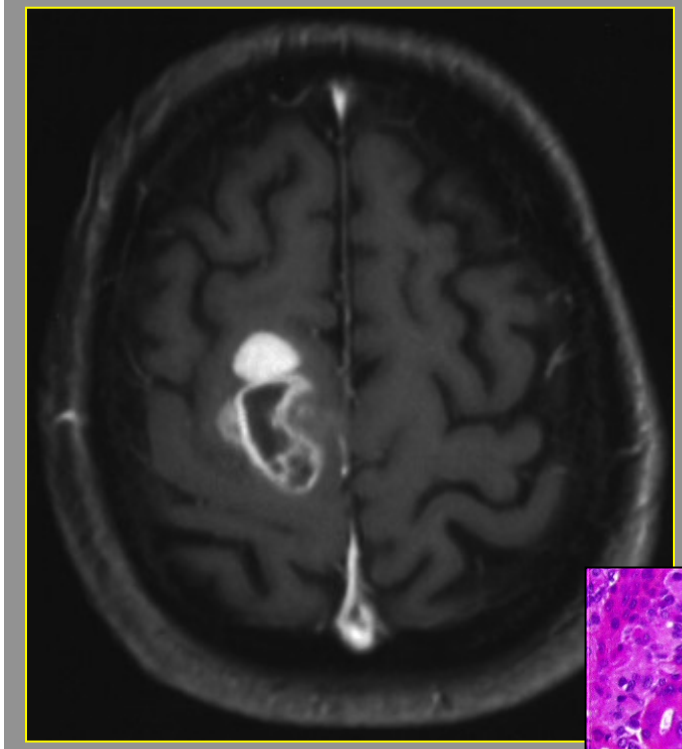

Séquence T1 après injection

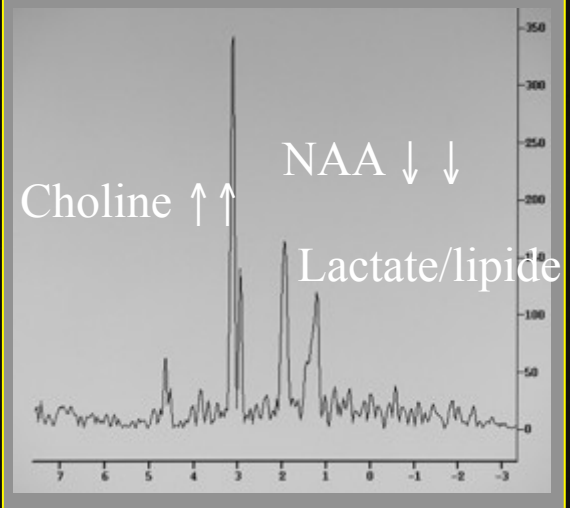

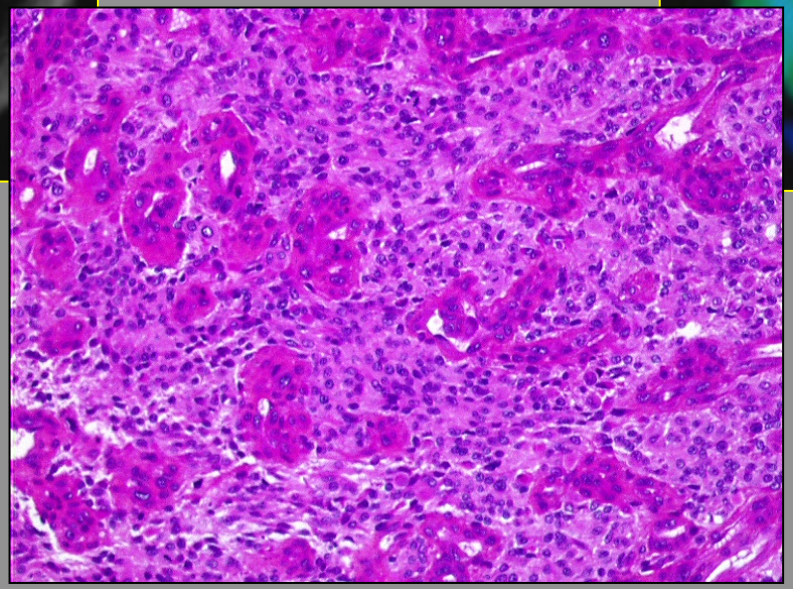

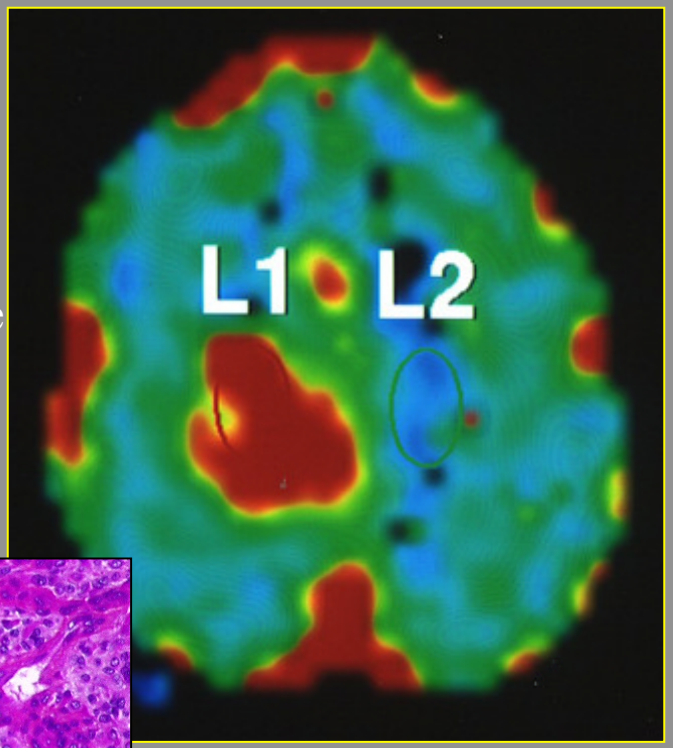

Cartographie de rCBV

- rCBV : 7.78
- Plus de 8 fois le côté controlatérale

Glioblastome

Lésion mal limitée
Densité/signal hétérogènes
Prise de contraste hétérogène
« Œdème » périlésionnel +++
Effet de masse souvent +++

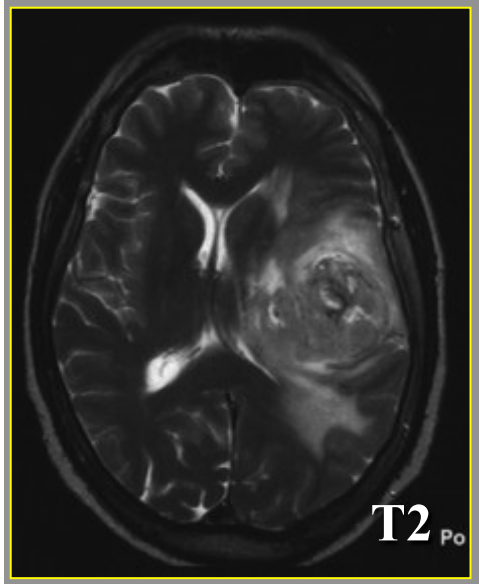

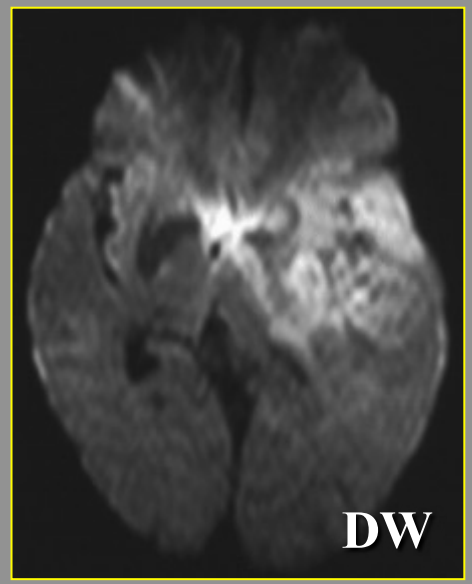

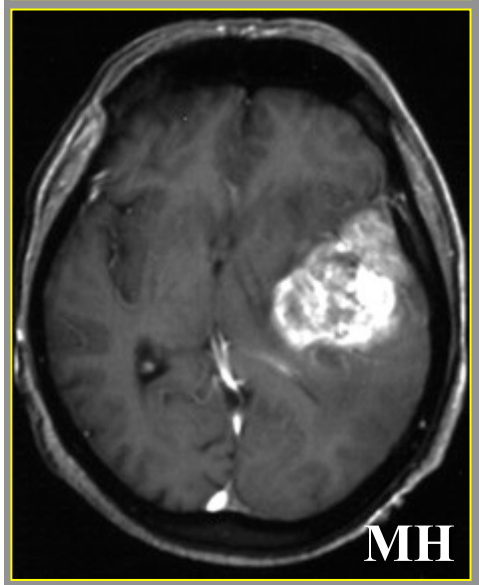

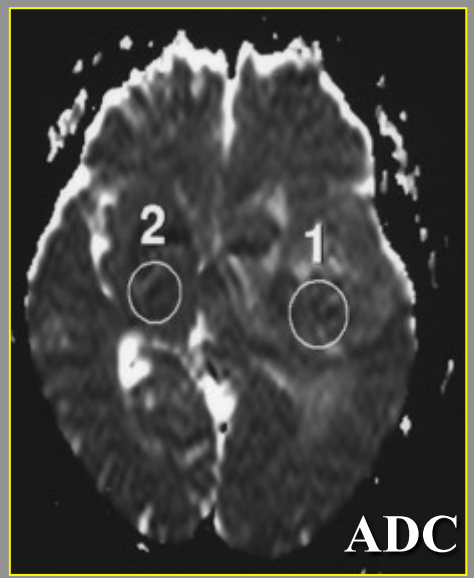

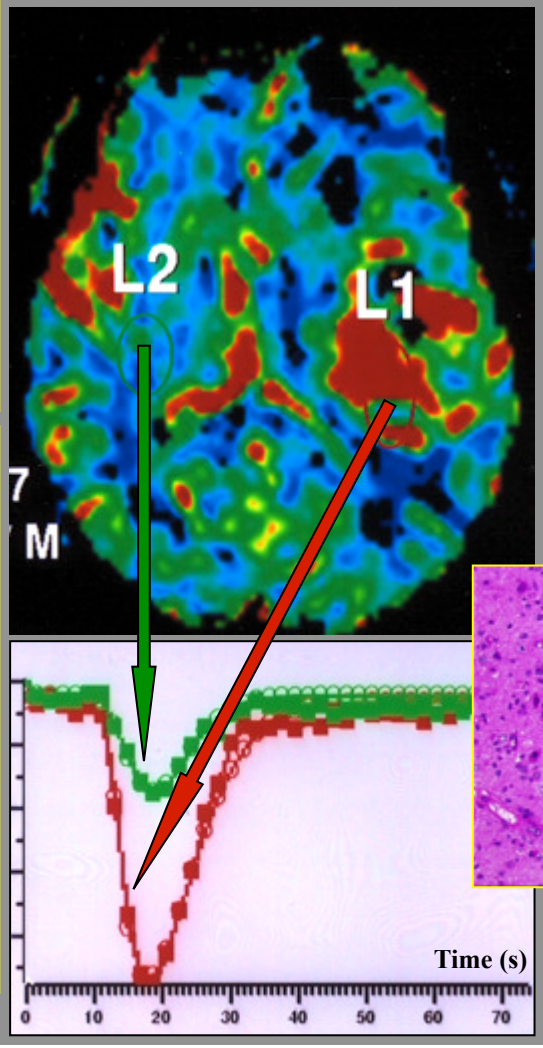

HPS * 200

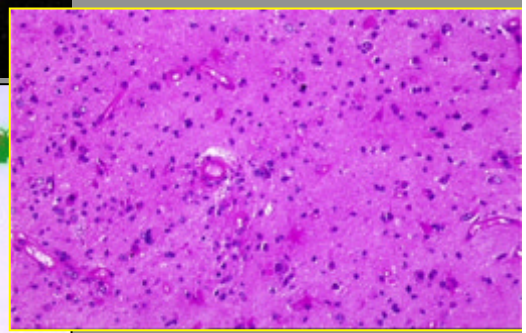

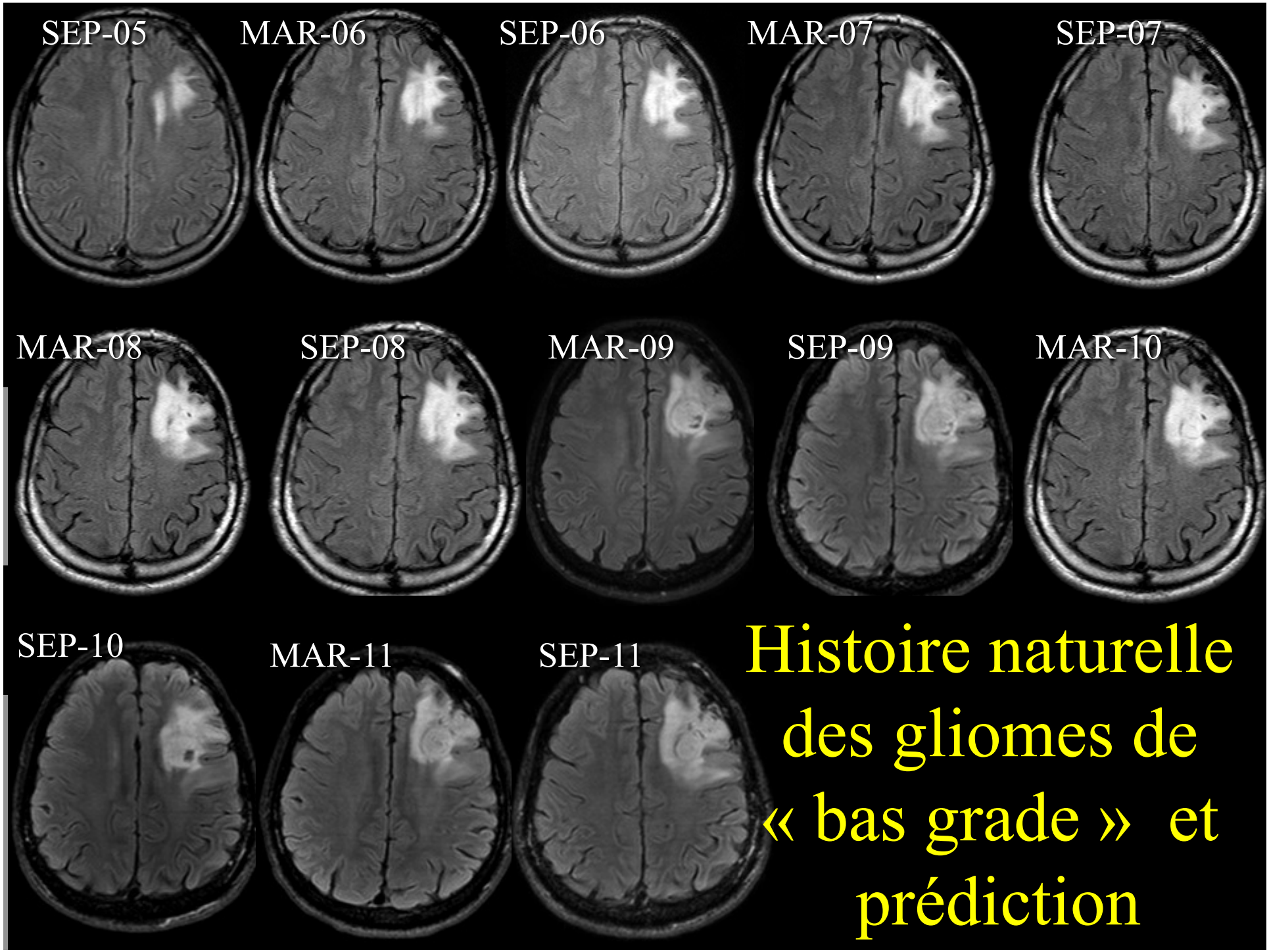

Histoire naturelle des gliomes de « bas grade » et prédiction

Croissance tumorale

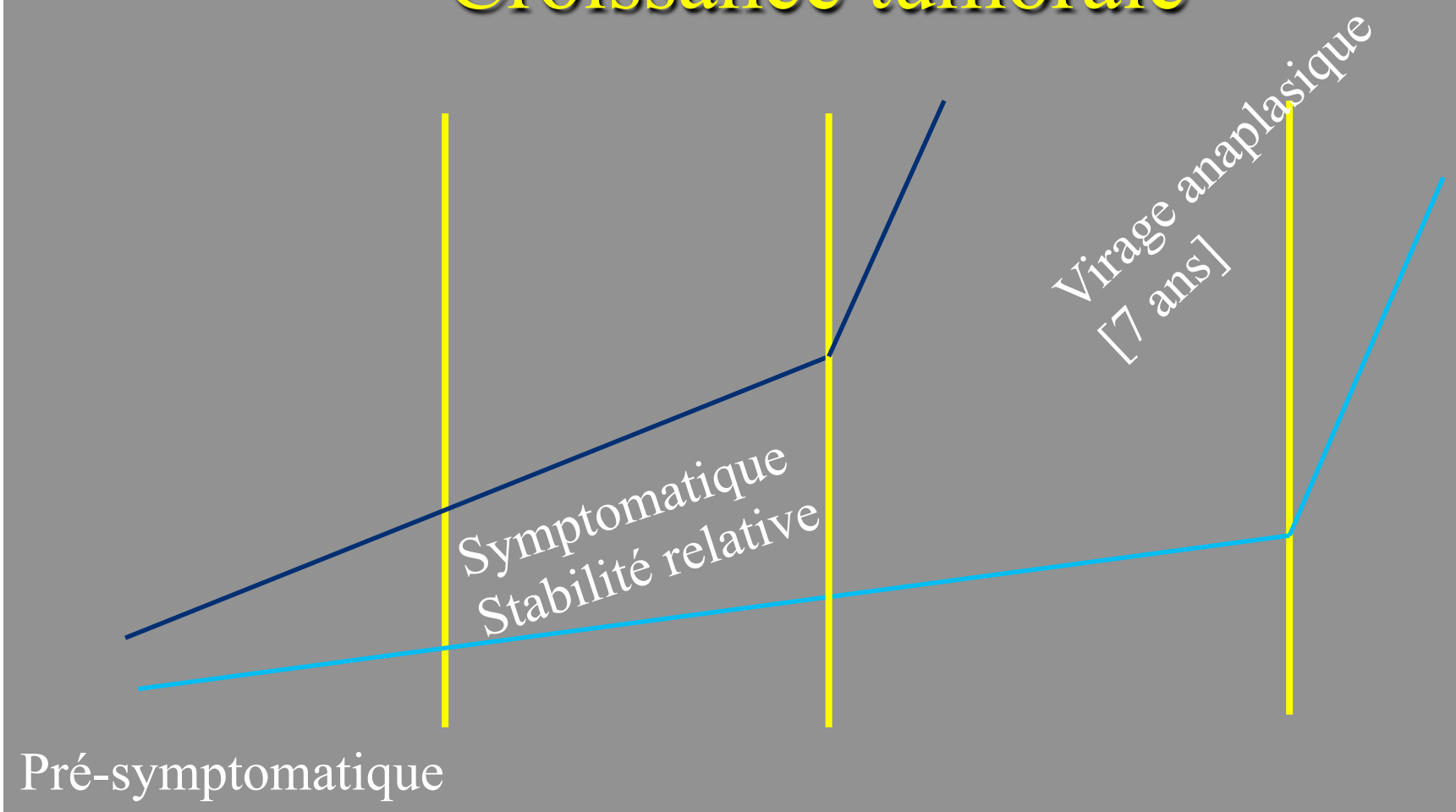

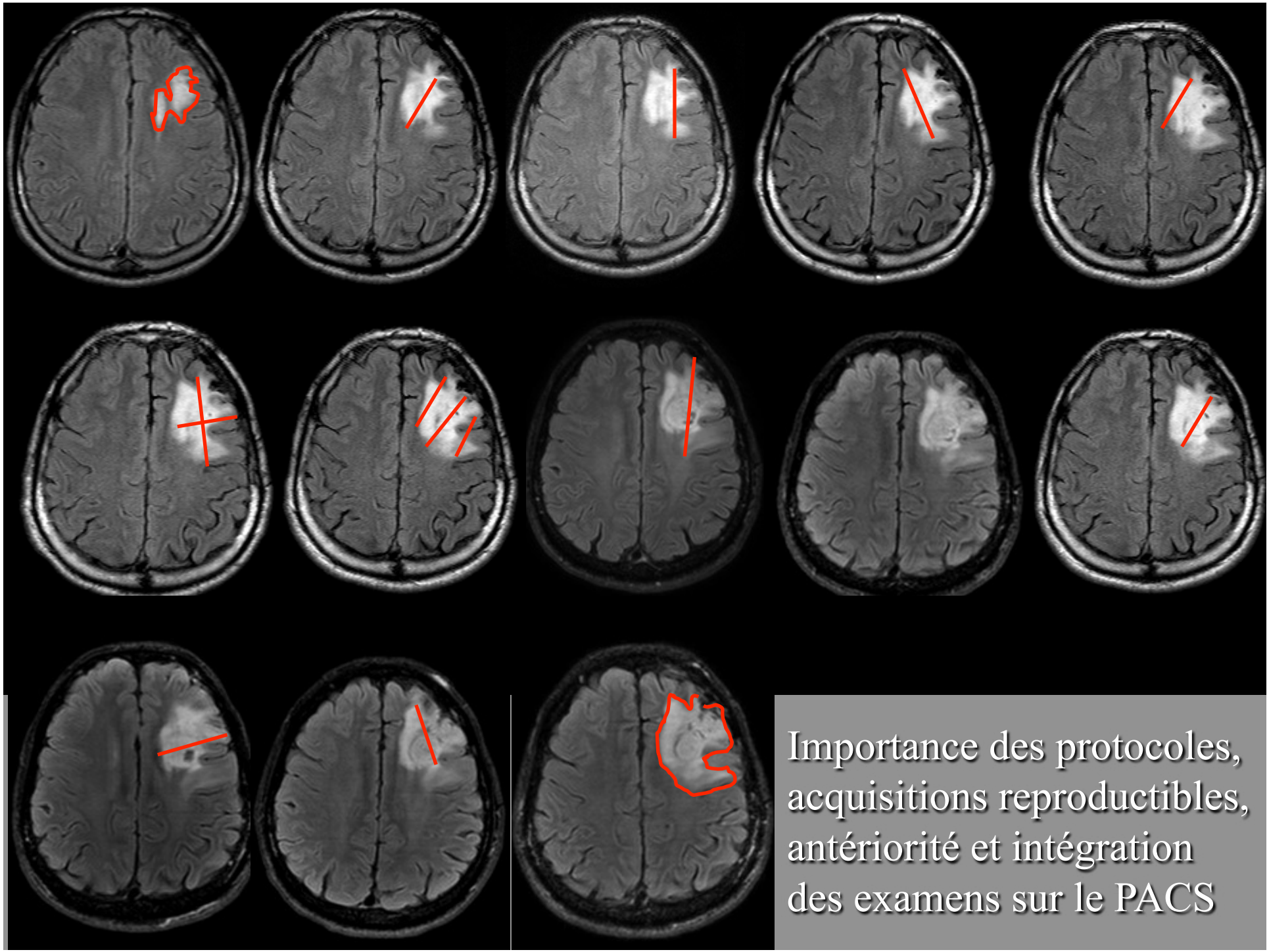

Importance des protocoles, acquisitions reproductibles, antériorité et intégration des examens sur le PACS

Patient non traité

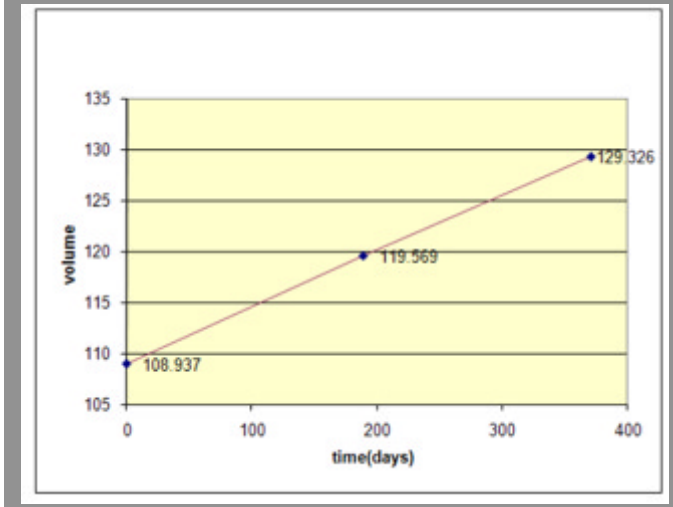

Patient suivi puis opéré



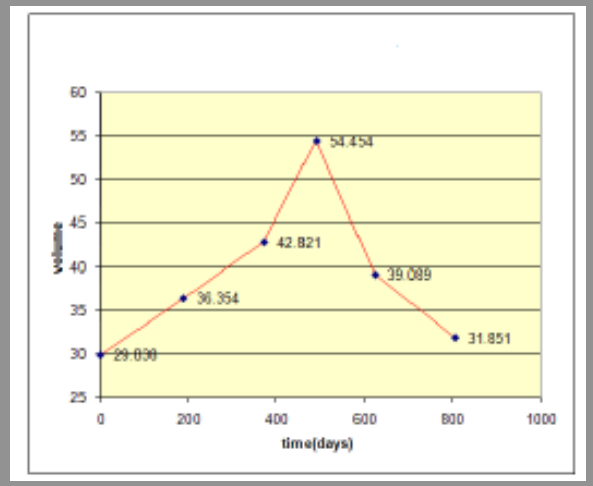

Patient suivi puis chimiothérapie

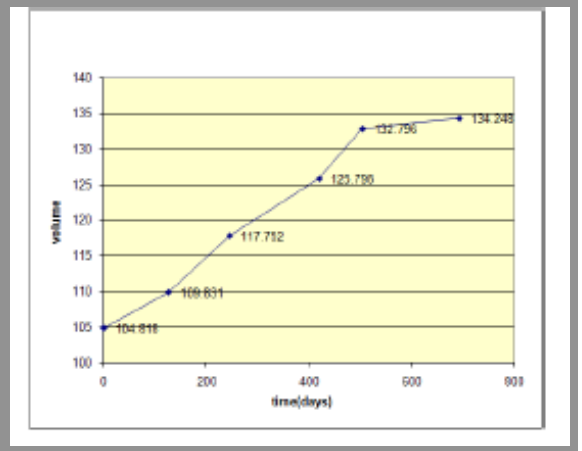

Evolution of brain tumor and stability of geometric invariants
K. Tawbe, F. Cotton and L. Vuillon; Unt J Telemed Appl 2008

Les gliomes de bas grade (sauf le grade I) évoluent tous vers l'anaplasie.

La pente de croissance est en moyenne de 4 mm par an [1] [entre 1-2 mm et 12-14 mm par an].

Plus la pente est importante, plus les lésions évoluent rapidement vers l'anaplasie.

Le ratio choline/créatine est corrélé à la pente tumorale.

[1] *Mandonnet et al, continuous growth of mean tumor diameter in a subset of grade II gliomas; Annal neuro 2003*

Valeur prédictive du virage:
association ratio choline/créatine et codélétion 1p19q

Patients	Ratio Chol/Cr >2,4	Absence de Co-deletion 1p-19q	Virage
1	1	1	1
2	1	1	1
3	1	1	1
4	1	1	1
5	0	1	0
6	0	1	0
7	1	0	0
8	0	0	0
9	0	0	0
10	0	0	0
11	0	0	0
12	0	0	0
13	0	0	0
14	0	0	0

Suivi des gliomes de bas grade

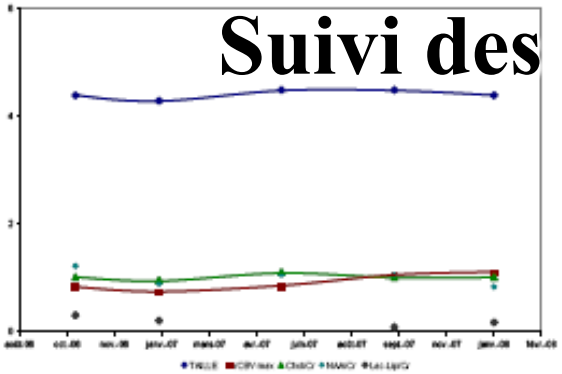

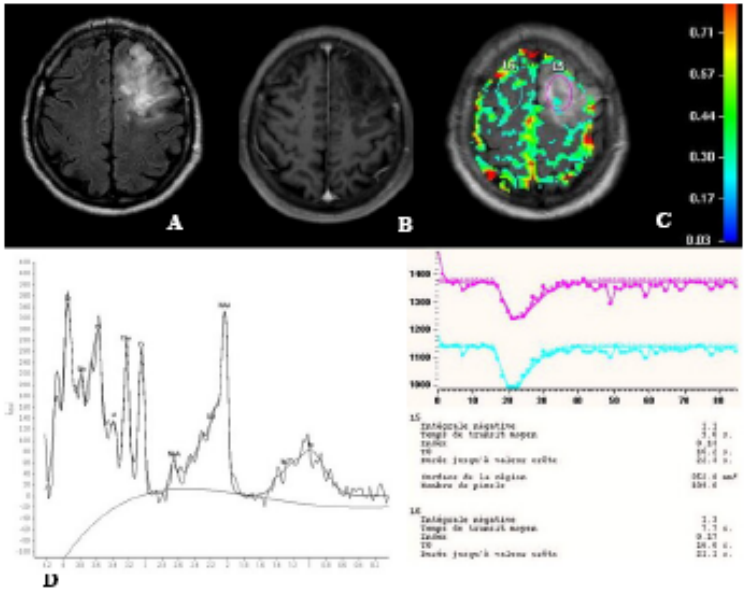

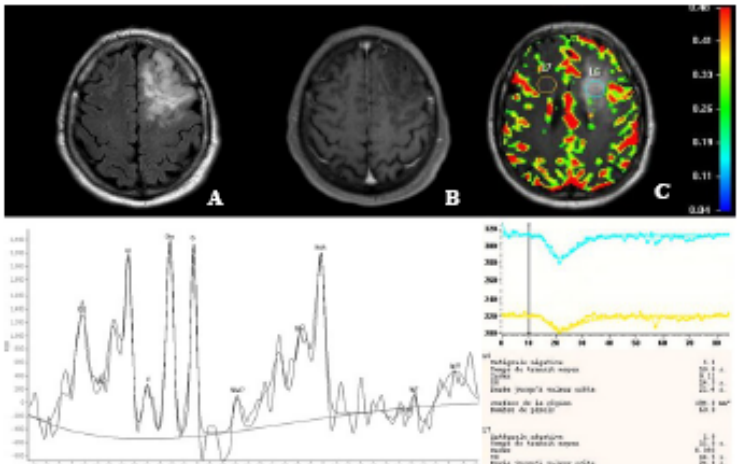

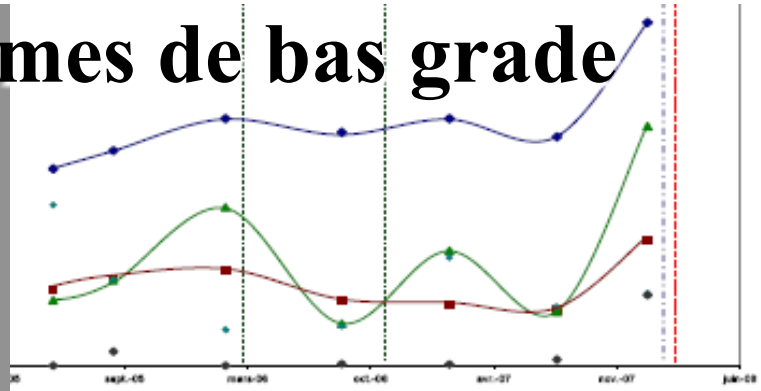

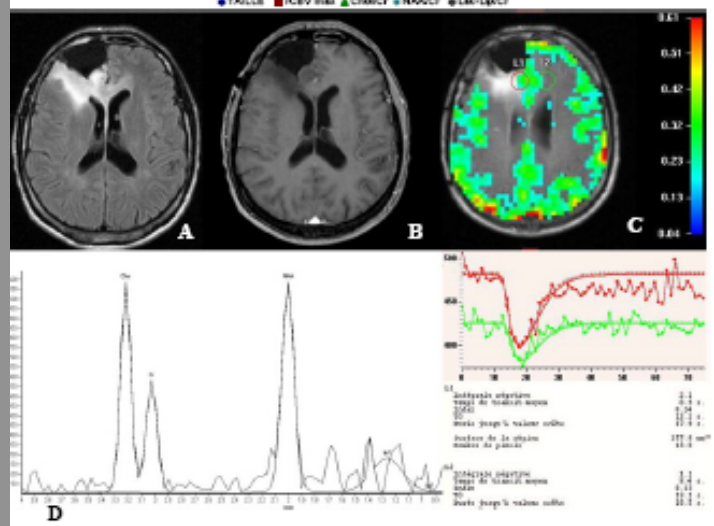

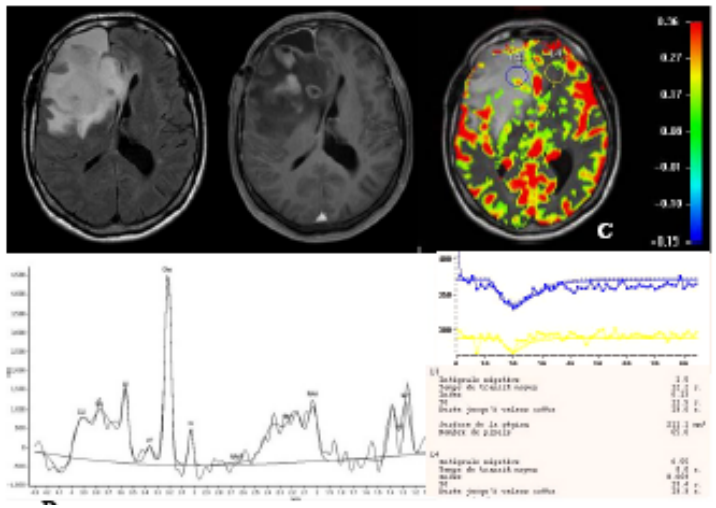

Quand suivre ces gliomes

1- IRM annuelle pour les astrocytomes pilocytiques

2- IRM au moins tous les 6 mois recommandée

3- IRM rapprochée si apparition d'une prise de contraste, modification de la perfusion ou augmentation du ratio choline/créatine supérieur à 2 alors surveillance rapprochée tous les 3 mois

II- APPLICATIONS EN NEUROONCOLOGIE

2- Diagnostic différentiel entre gliomes de haut grade et lésions présentant une rupture de la BHE

⇒ Métastases

⇒ Lymphomes

⇒ Forme pseudo-tumorale de SEP (vu ce matin)

Gliome de haut grade versus métastase

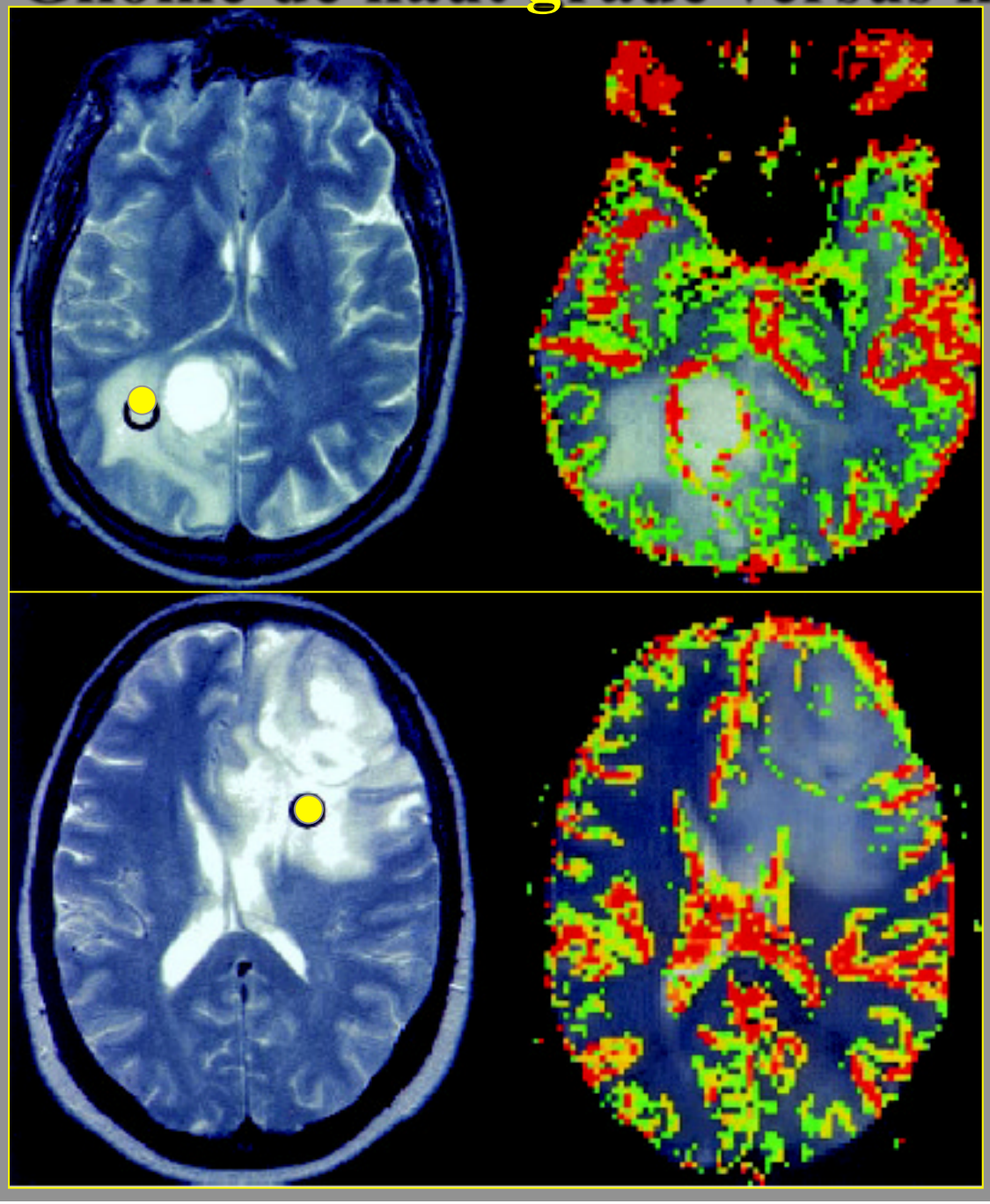

GBM

rCBV = 2.34

Métastase d'un
Carcinome pulmonaire

rCBV = 0.39

Métastase d'un carcinome épidermoïde

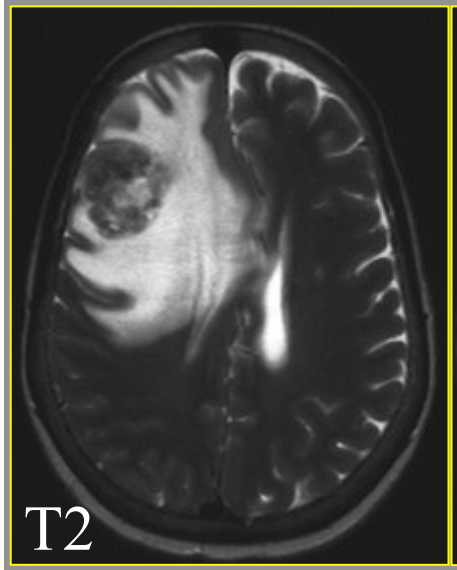

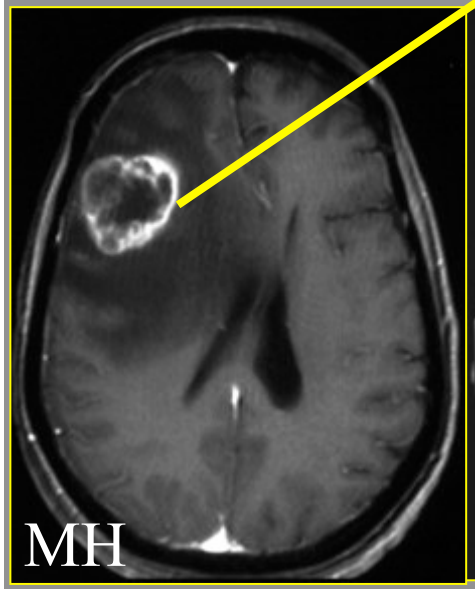

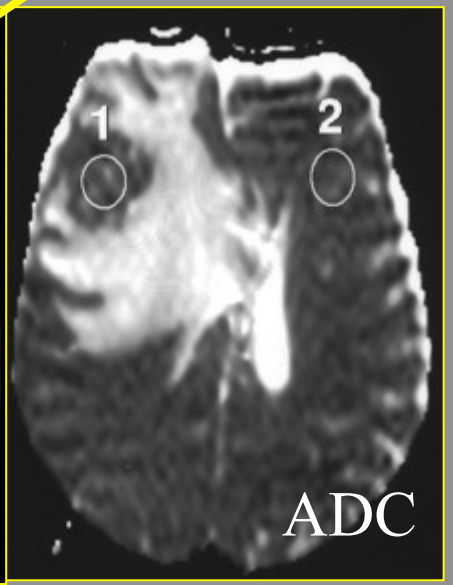

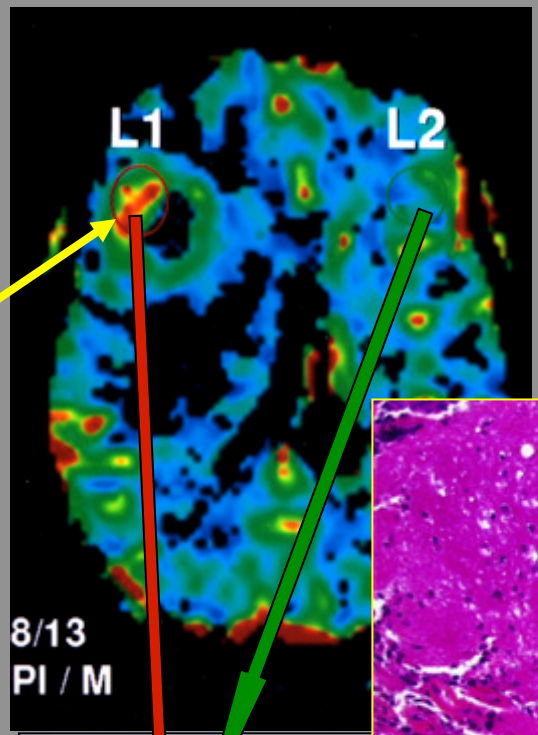

HPS * 200
(Hemalun
Phloxine Safran)

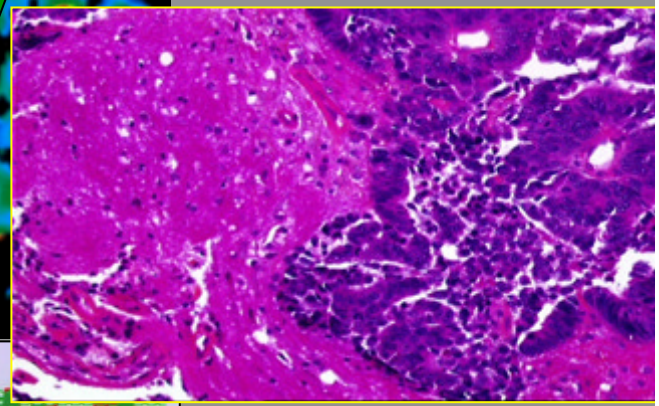

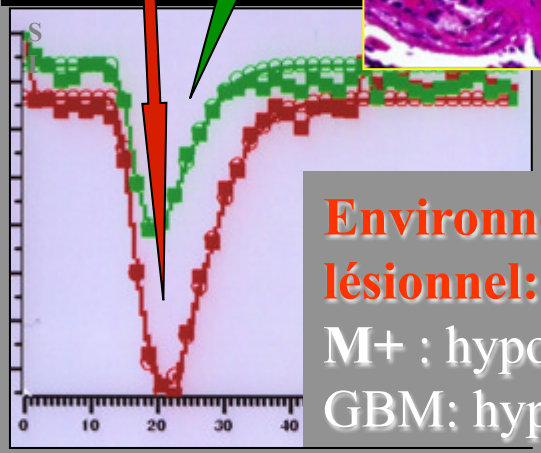

Environnement péri lésionnel:

M+ : hypo signal; CDA ↑↑↑

GBM: hyper signal et CDA ↑

Glioblastome

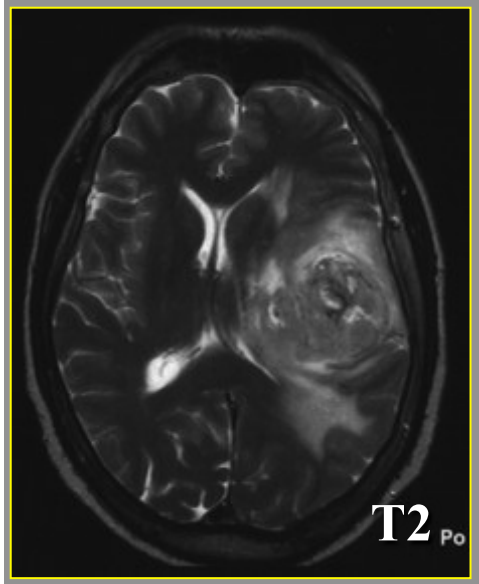

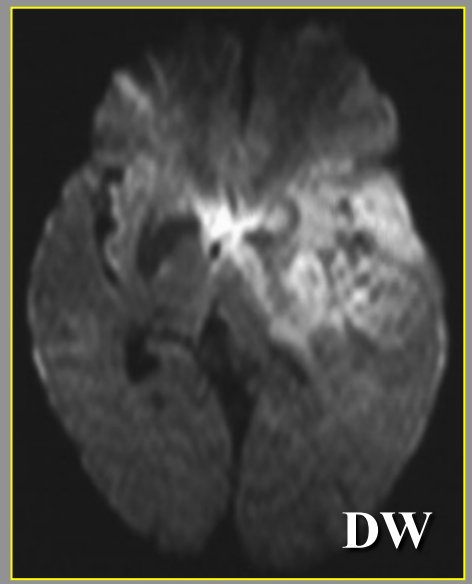

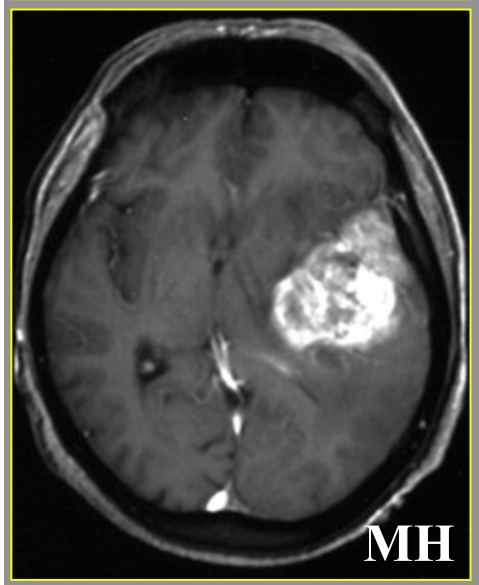

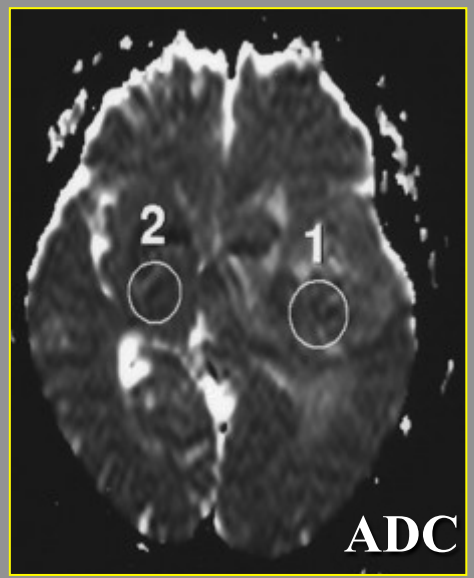

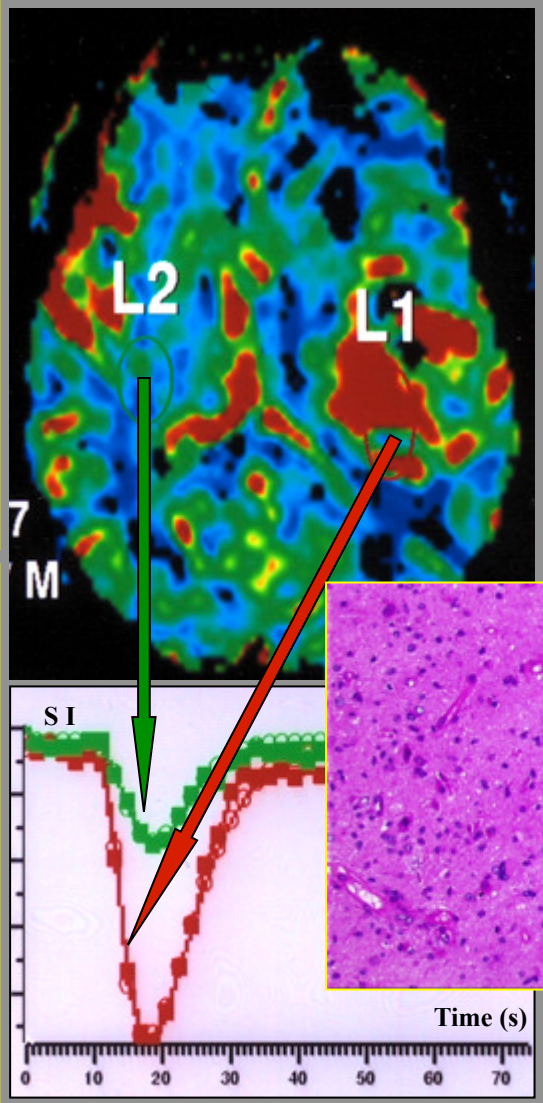

HPS * 200

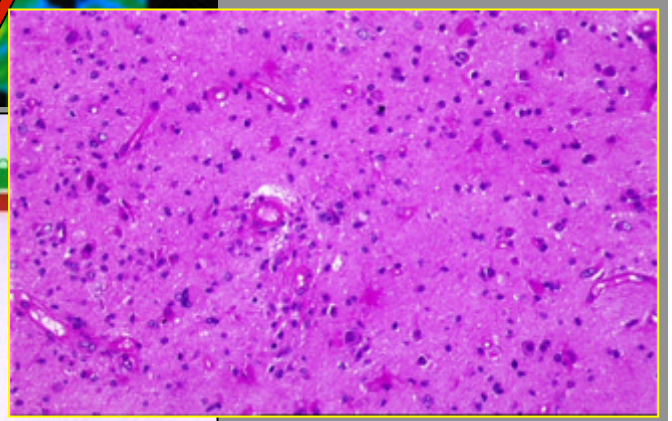

Diagnostic différentiel avec les lymphomes

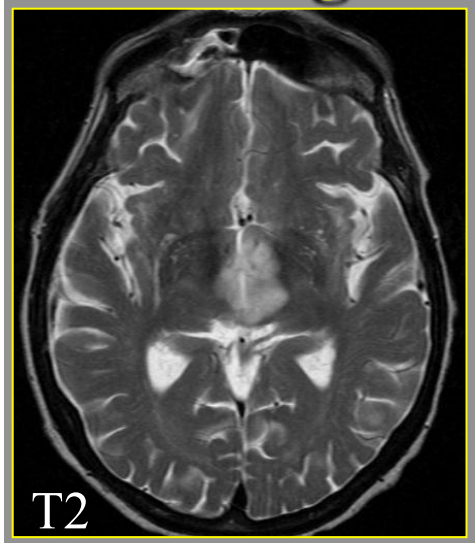

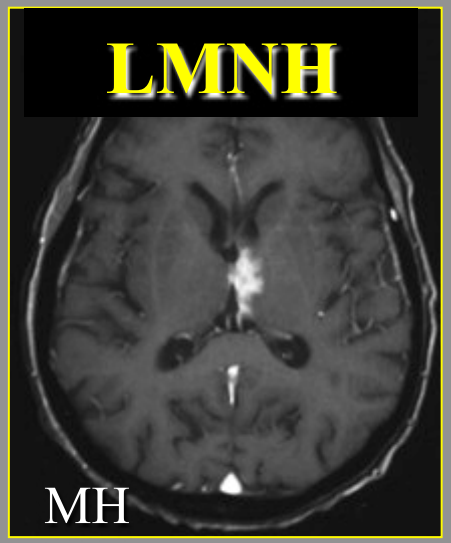

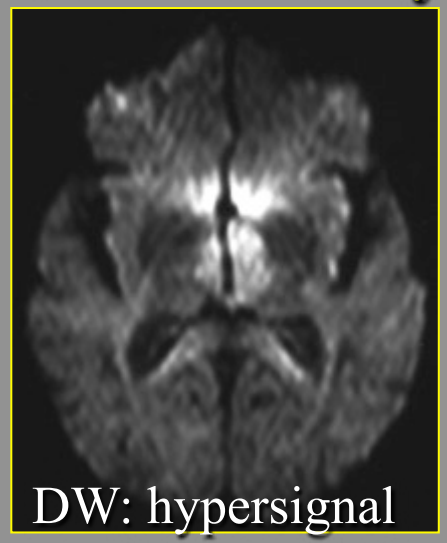

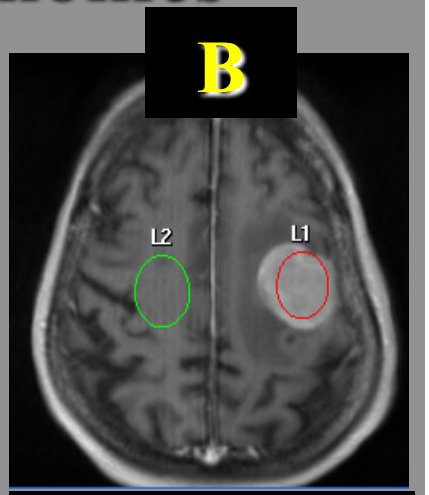

1 rCBV bas (1,43 ± 0,64) malgré la rupture de la BHE

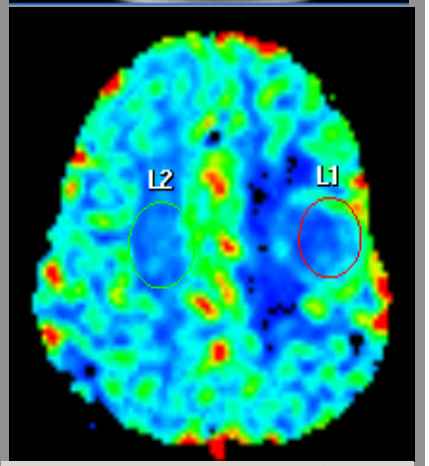

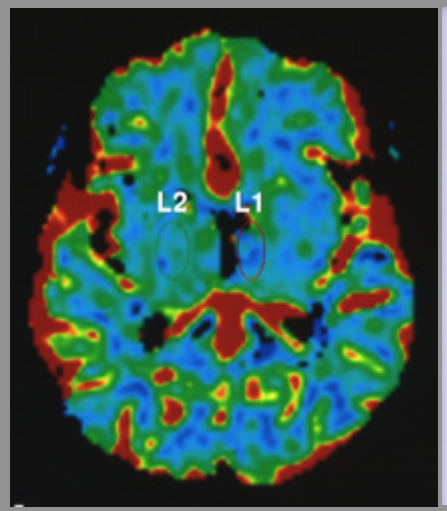

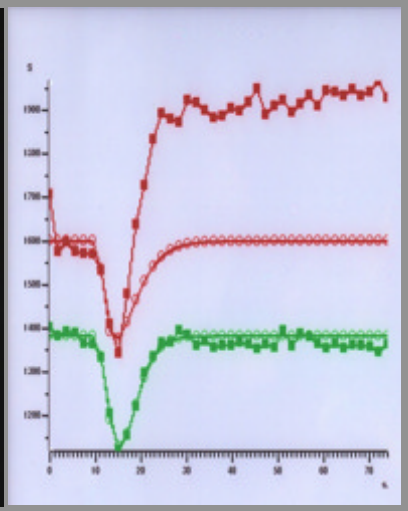

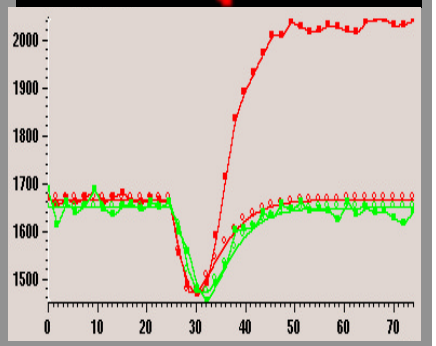

2 Courbe:
remontée au-dessus de la ligne de base > 30% de l'intensité du signal avant un plateau (10 s)

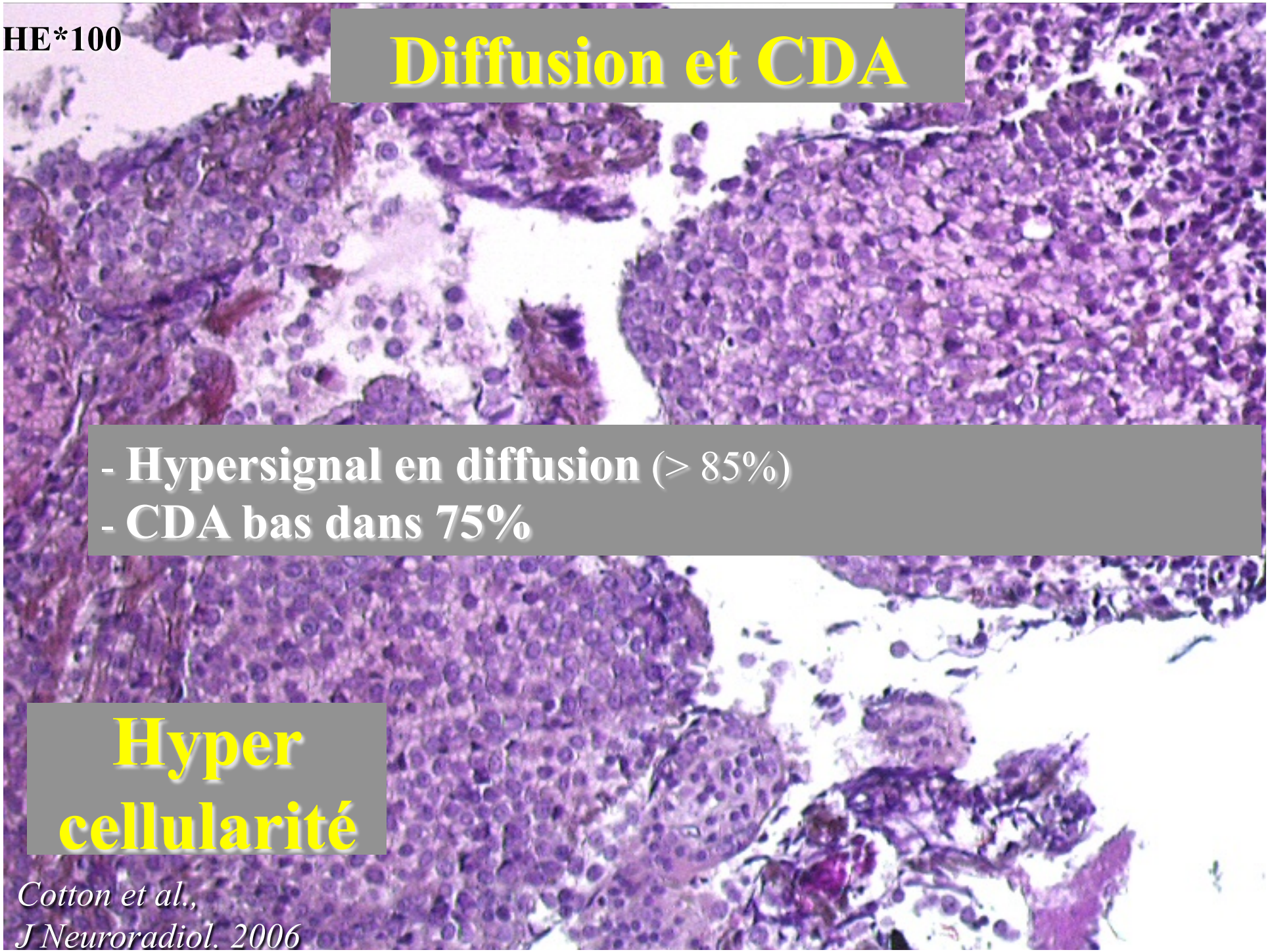
HE*100
Diffusion et CDA
- Hypersignal en diffusion (> 85%)
- CDA bas dans 75%
Hyper cellularité
Cotton et al.,
J Neuroradiol. 2006

Lymphome cérébral primitif à grande cellules B

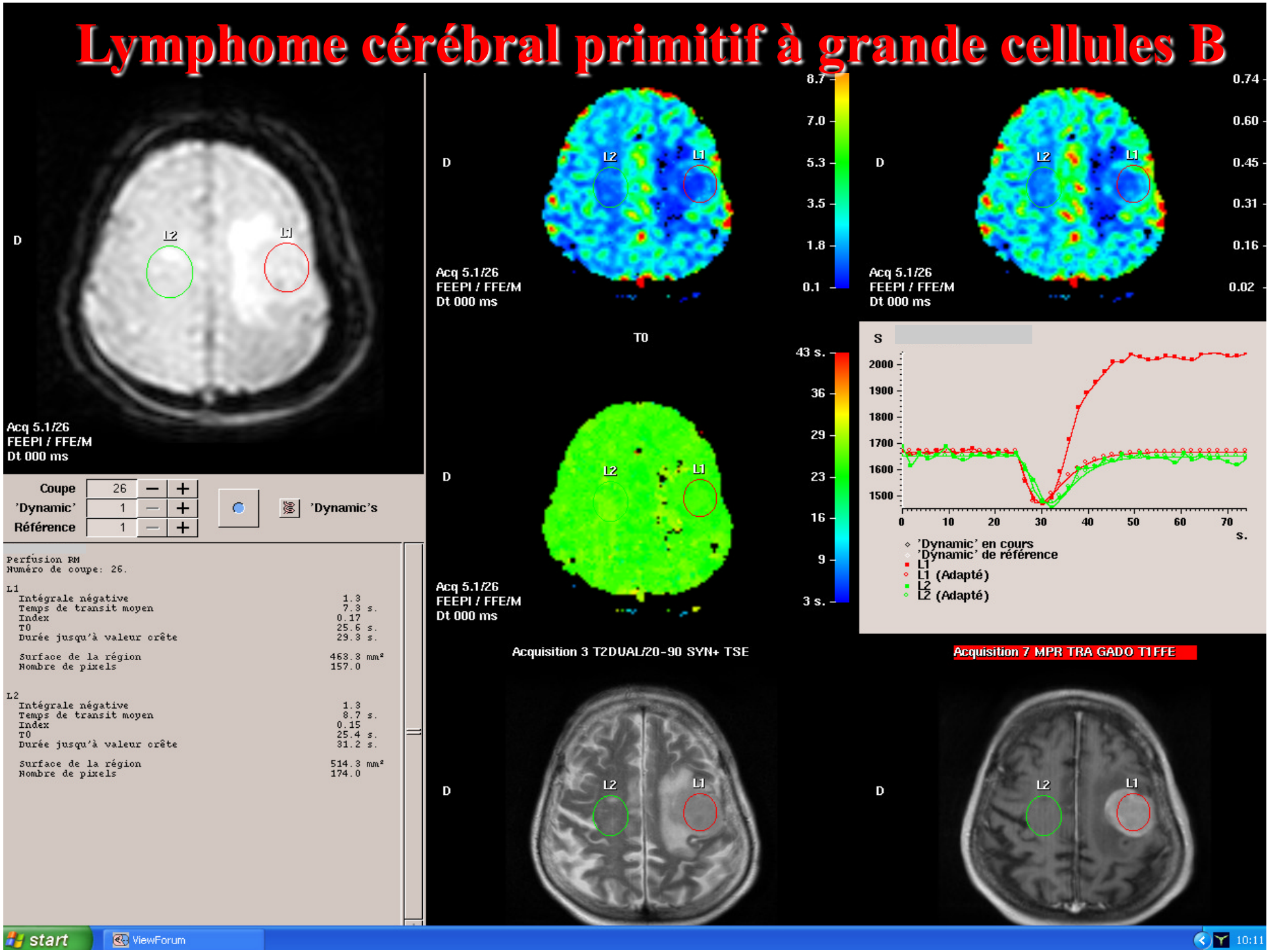

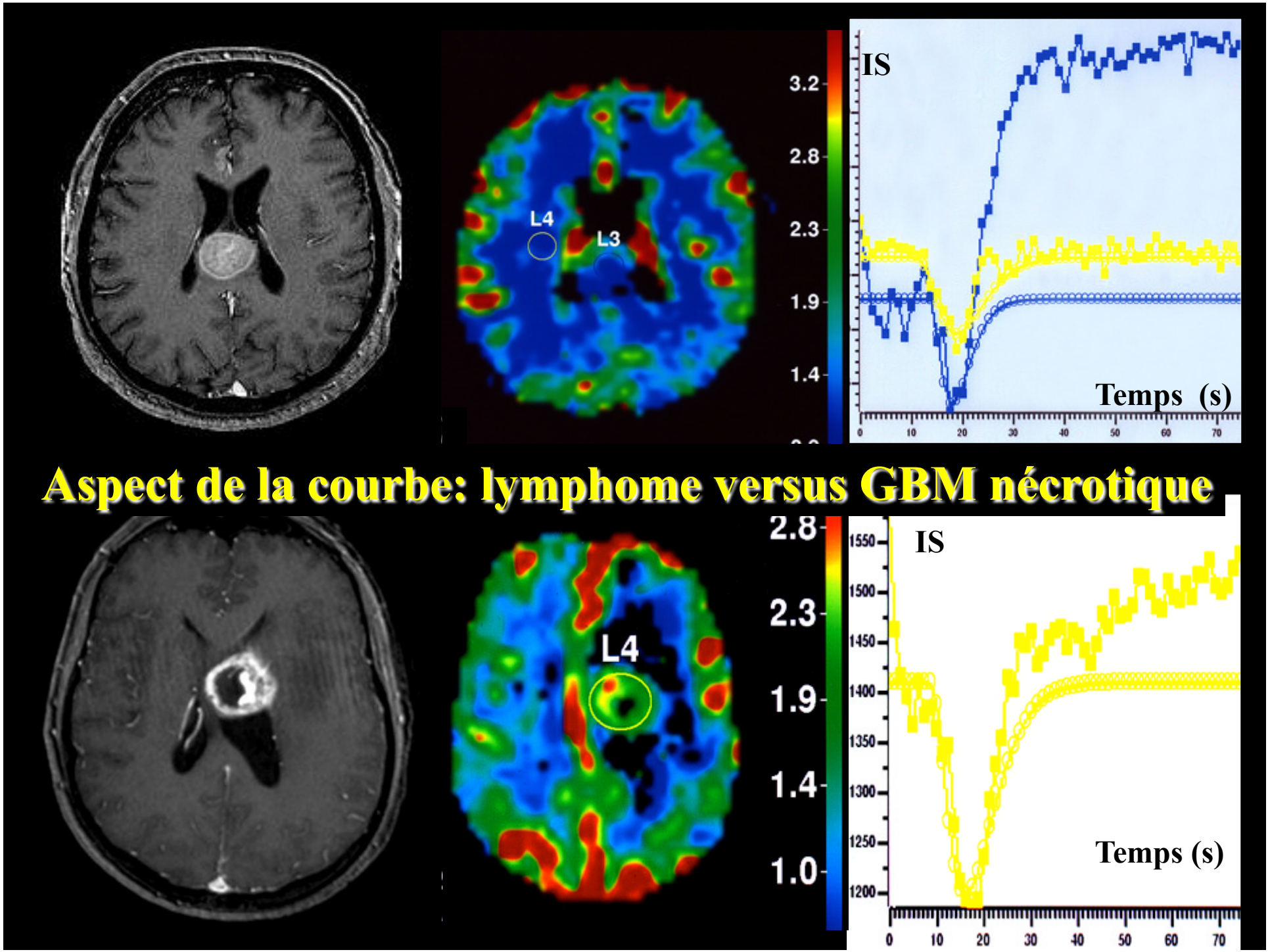
L4
L3
3.2
2.8
2.3
1.9
1.4
IS
Temps (s)
0
10
20
30
40
50
60
70
Aspect de la courbe: lymphome versus GBM nécrotique
L4
2.8
2.3
1.9
1.4
1.0
IS
1550
1500
1450
1400
1350
1300
1250
1200
Temps (s)
0
10
20
30
40
50
60
70

Le profil spectroscopique des lymphomes est parfois similaire aux métastases (pas de NAA, choline elevée, pic de lactate). L'importance du pic de lipide est néanmoins très évocateur de métastase.

Les données de la perfusion permettent de trancher: valeurs du rCBV augmentées dans les métastases et normales dans le lymphome.

II- APPLICATIONS EN NEUROONCOLOGIE

3- Ciblage, intérêt potentiel de la perfusion et spectroscopie

Ciblage

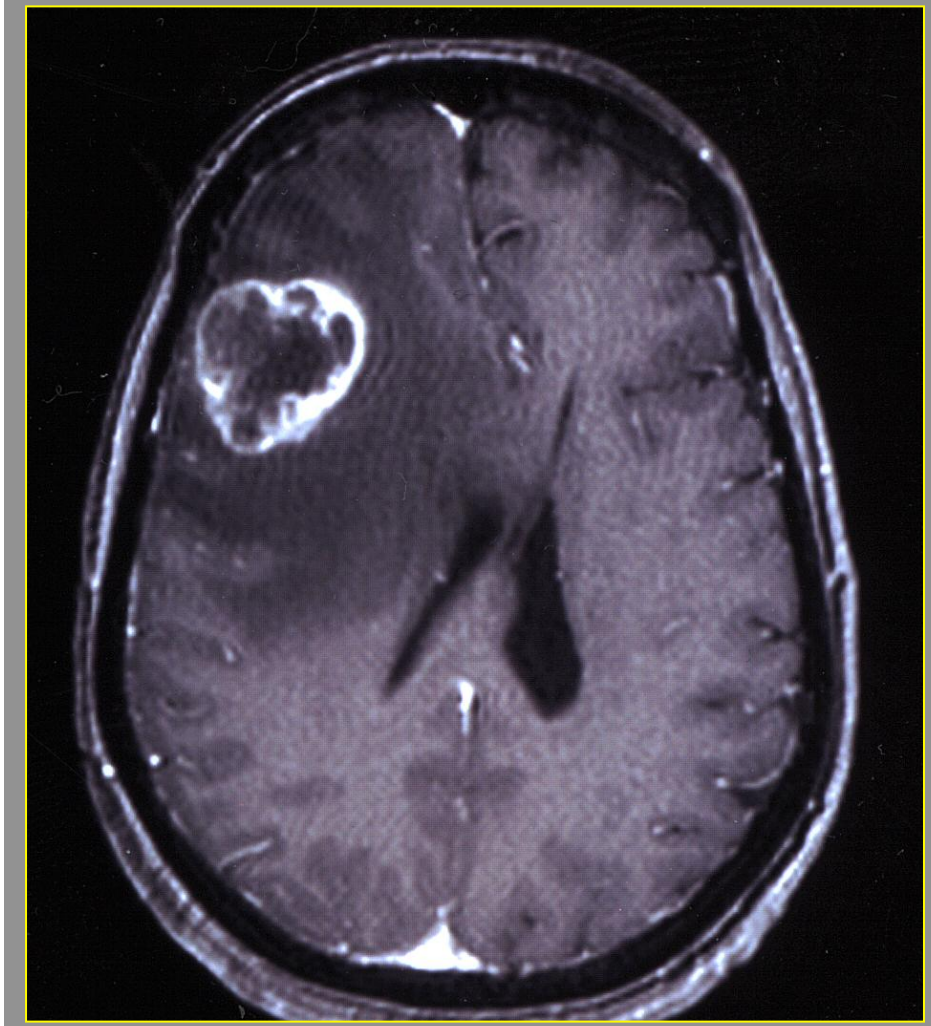

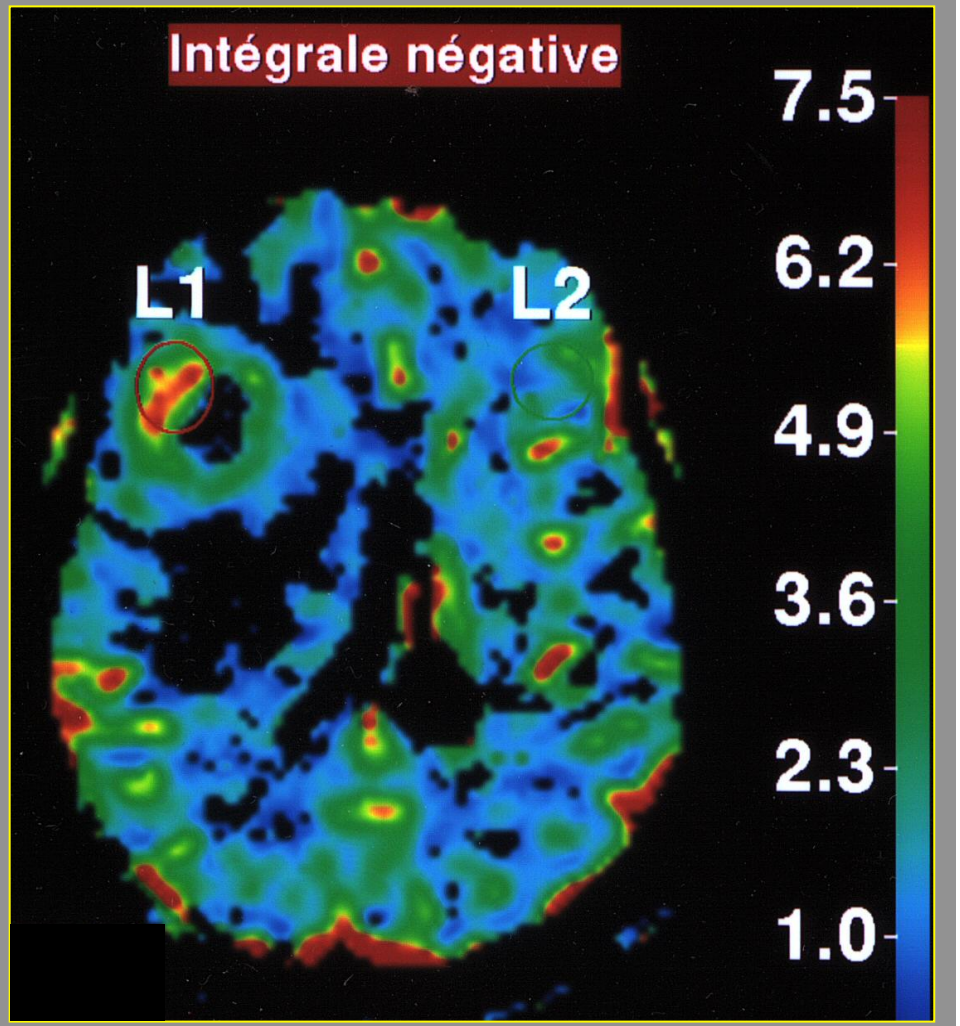

« Ciblage » en radiothérapie

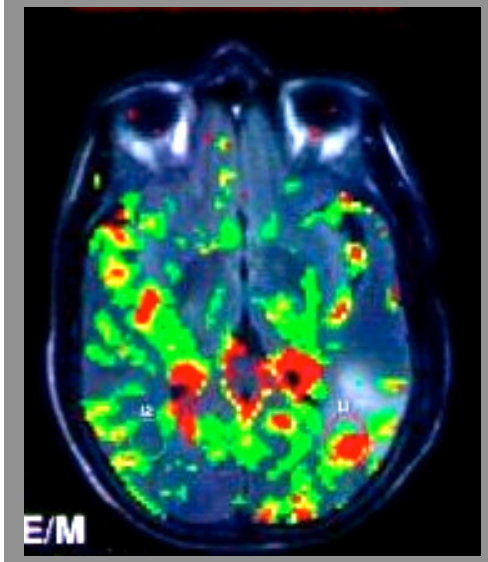

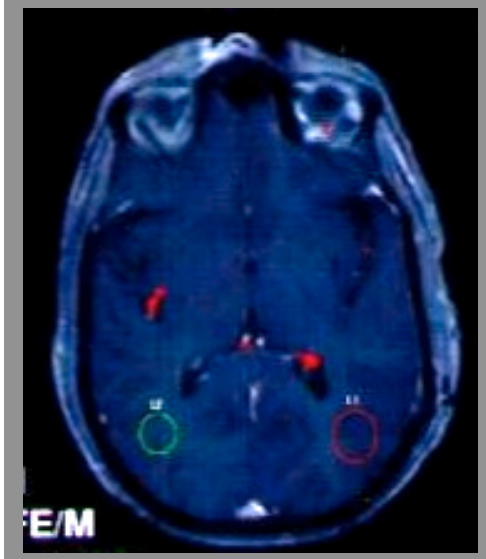

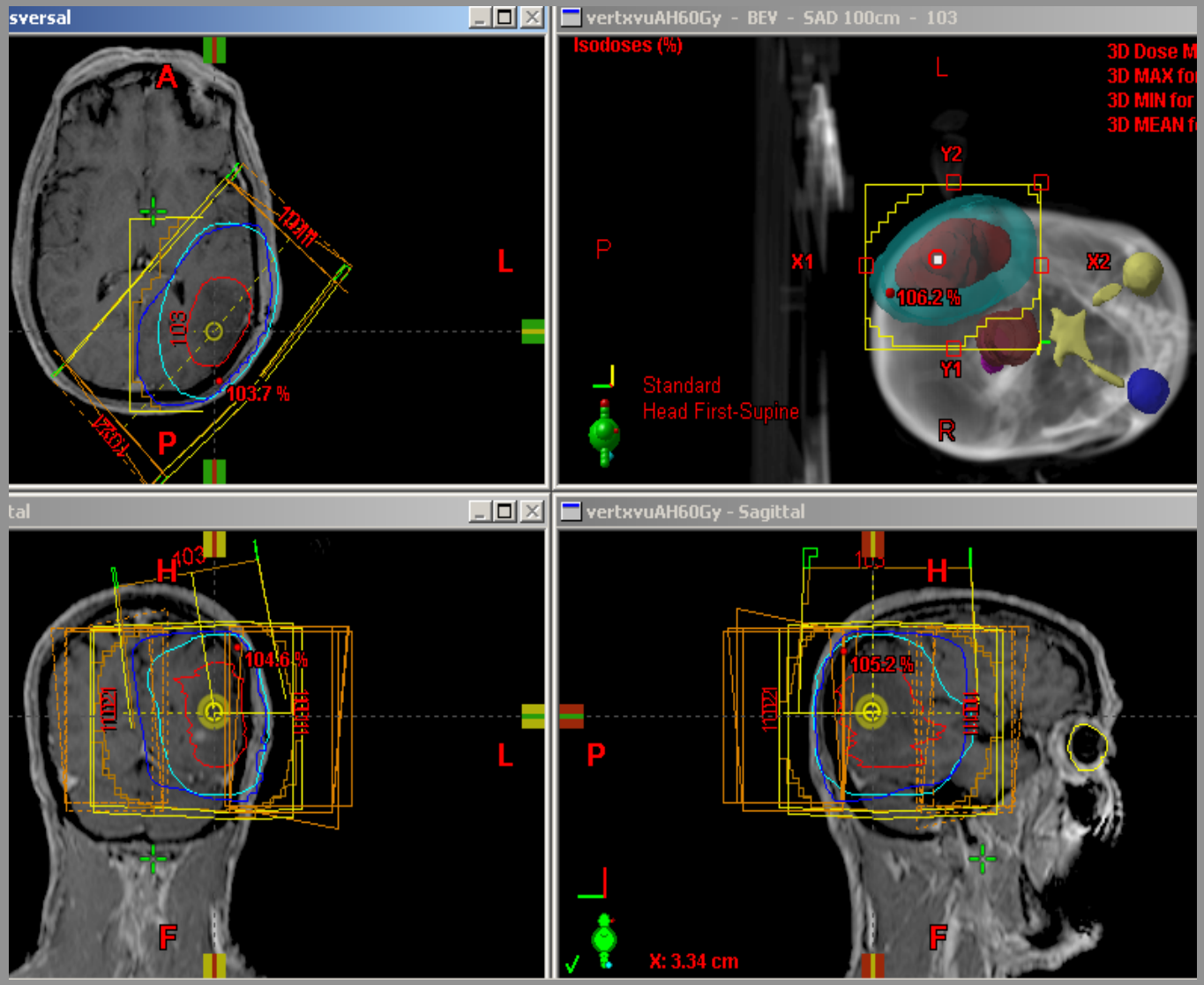

Mémoire du DIU de neuro-oncologie, Dr A D'Hombres

II- APPLICATIONS EN NEUROONCOLOGIE

4- Suivi

- Nécrose versus abcès, infection
- Récidive versus radionécrose
- Transformation des gliomes de bas grade

Abcès versus nécrose

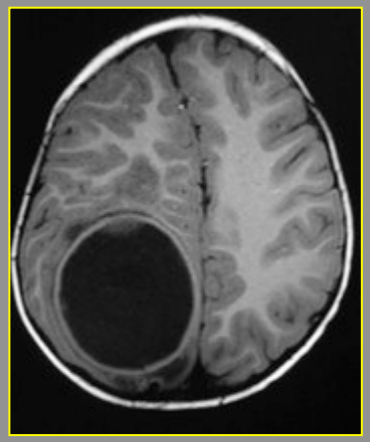

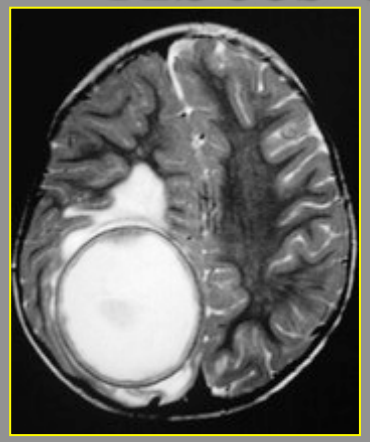

Abcès

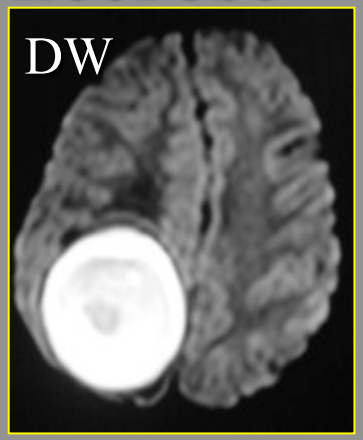

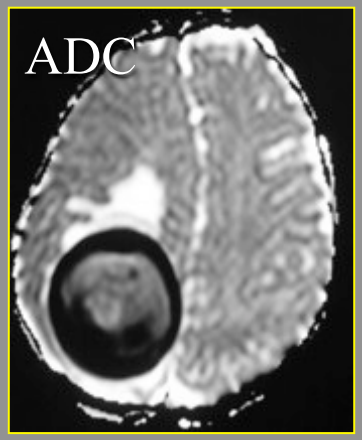

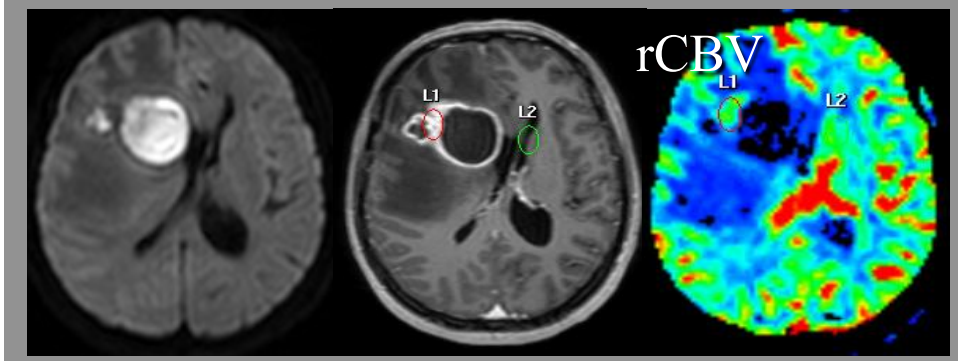

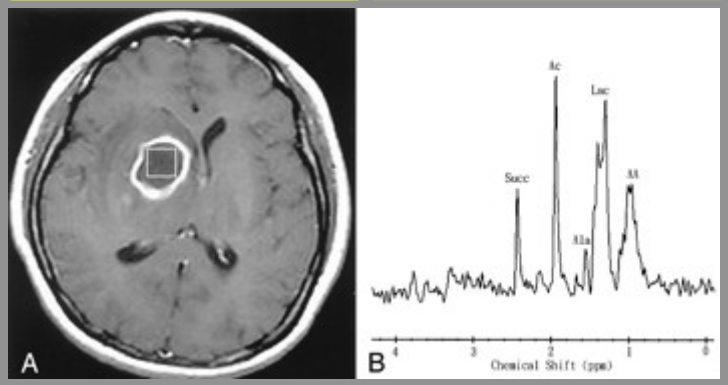

Nécrose tumorale

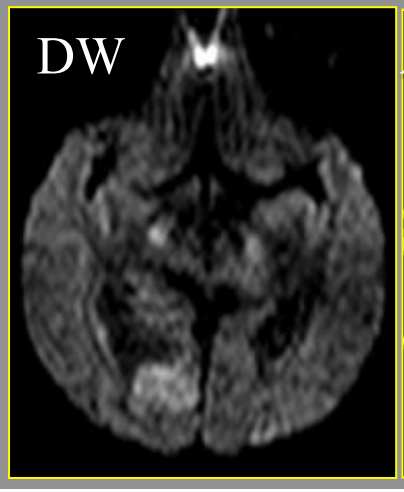

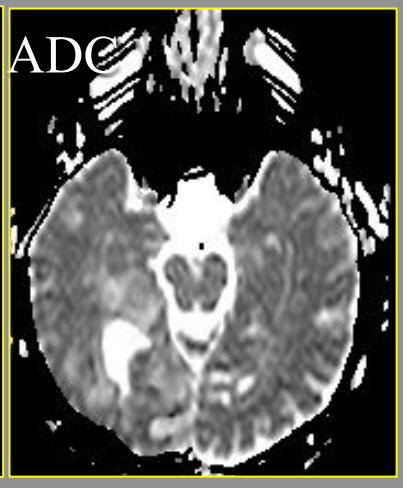

Complications de la radiothérapie

Rollin et al., Neuroradiol. 2006

radionécrose

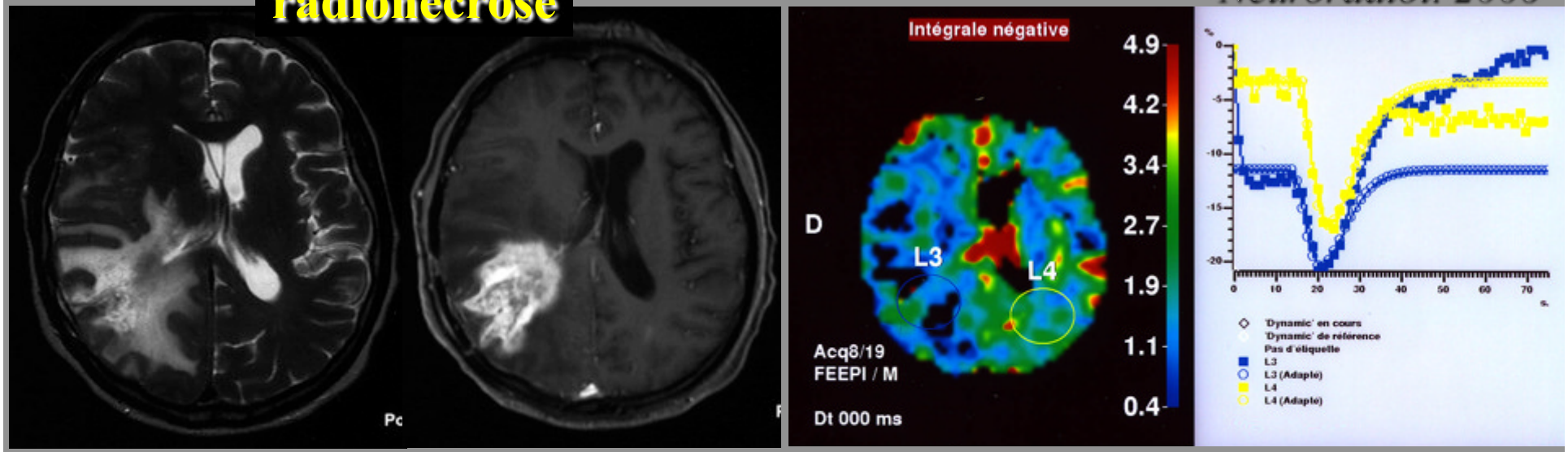

- rCBV bas (<1.5) avec importante rupture de la BHE

Leucoencéphalopathie post-radique

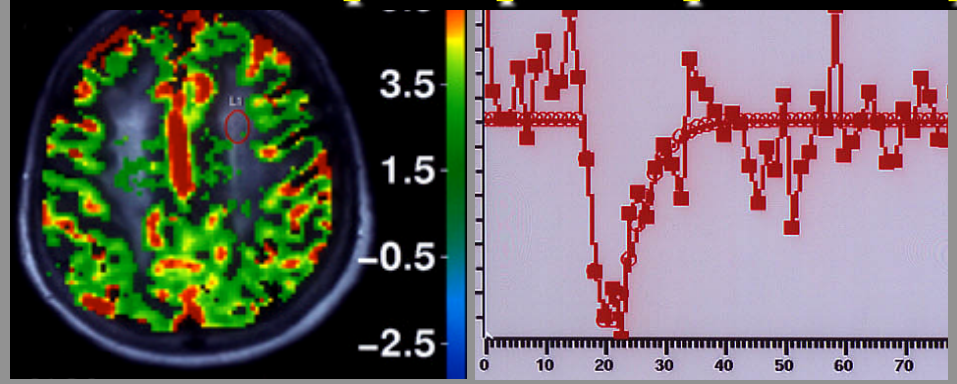

rCBV est bas (<1)

Homme de 62 ans, traité par radiochimiothérapie (Temodal) pour un gliome anaplasique. Réapparition d'une lésion nécrotique faisant craindre une récidive. Bilan IRM complémentaire ?

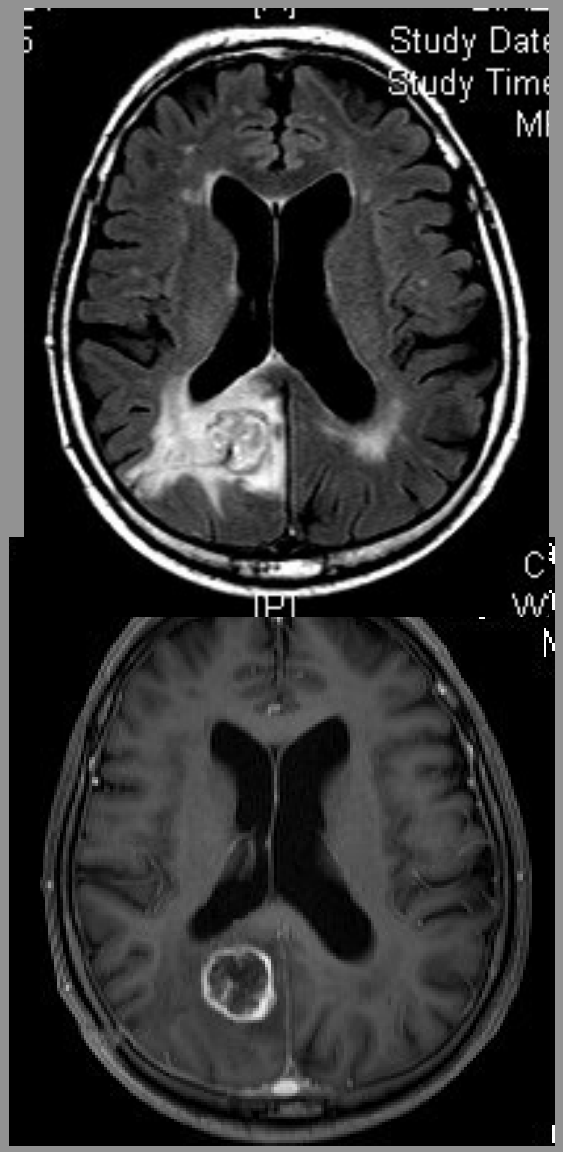

Radionécrose

Pic de lipide majeur effaçant tous les autres pics

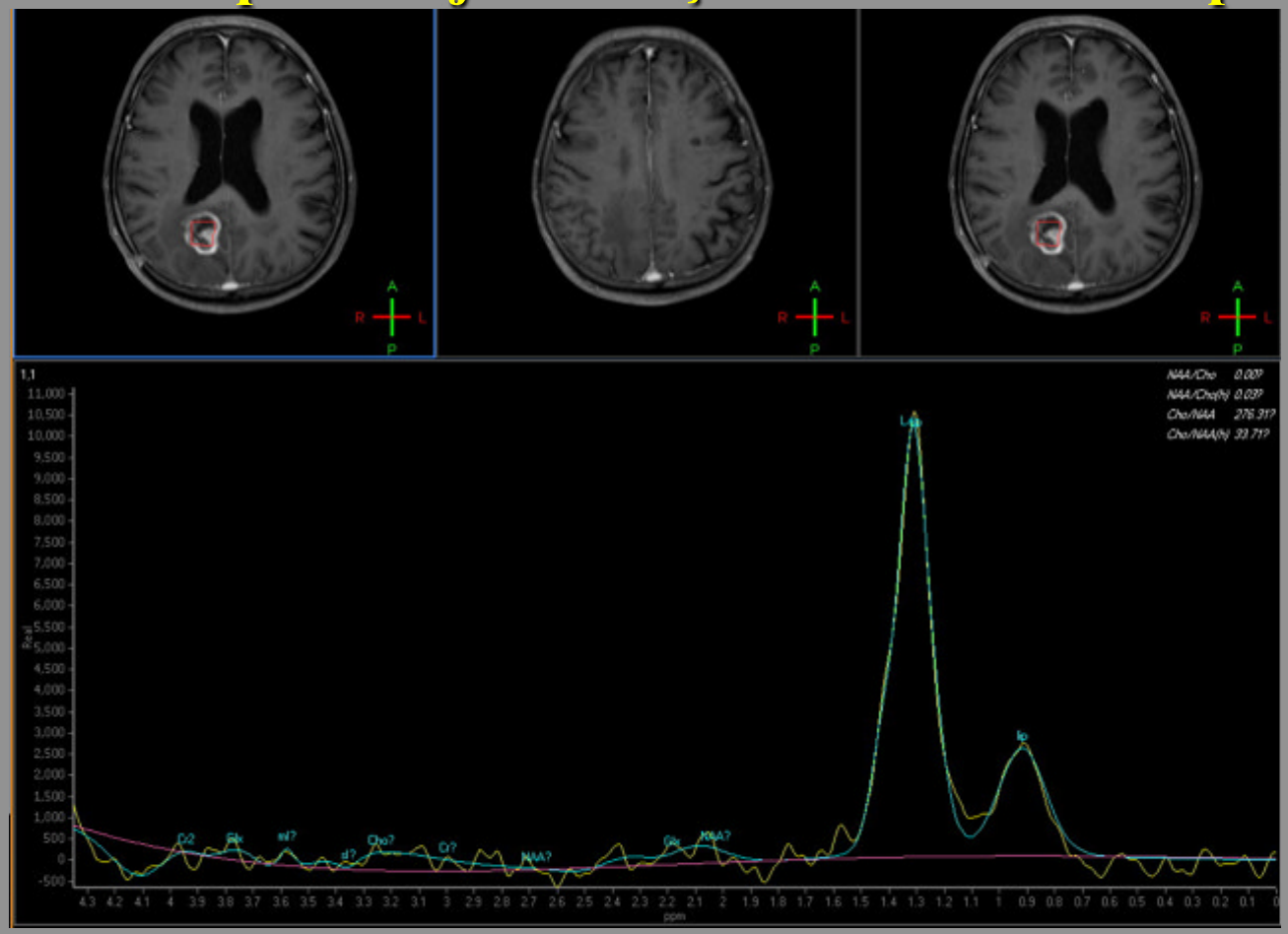

IV- Cas particuliers

Astrocytome pilocytique, Grade 1

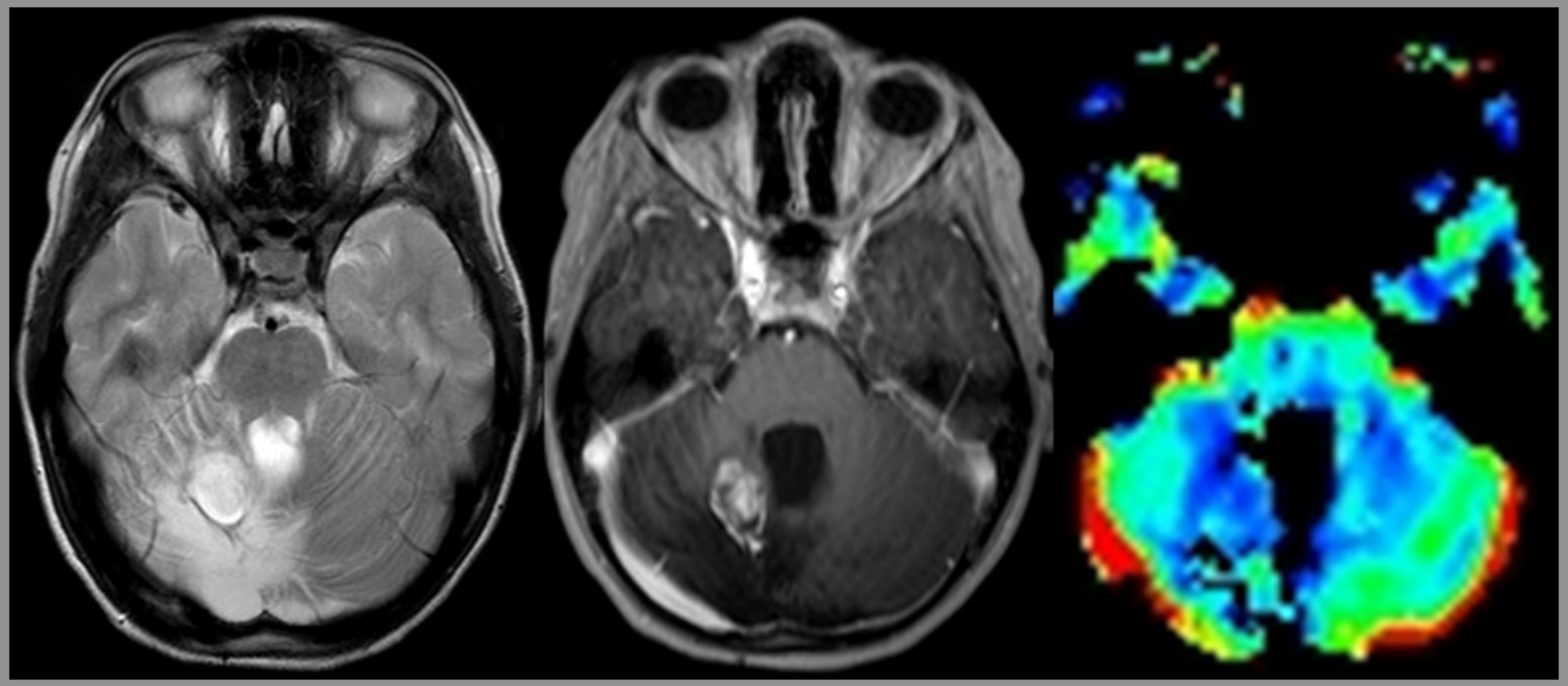

lésion volontiers nodulokystique
PC nodulaire habituelle

Lésions kystiques avec nodule mural

Hémangioblastome ou astrocytome pilocytique

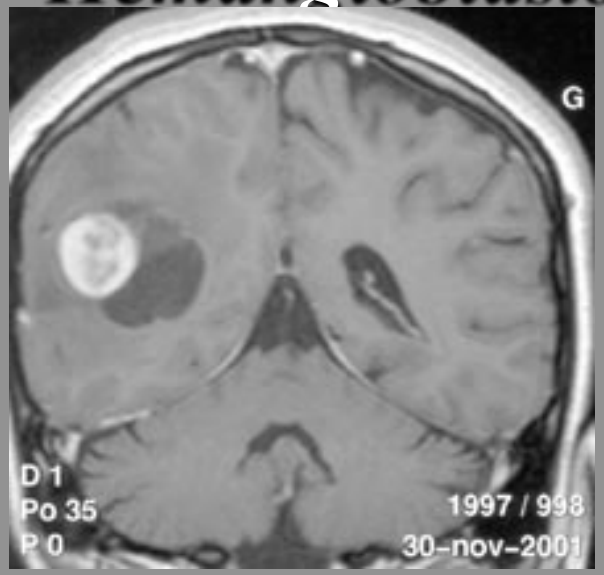

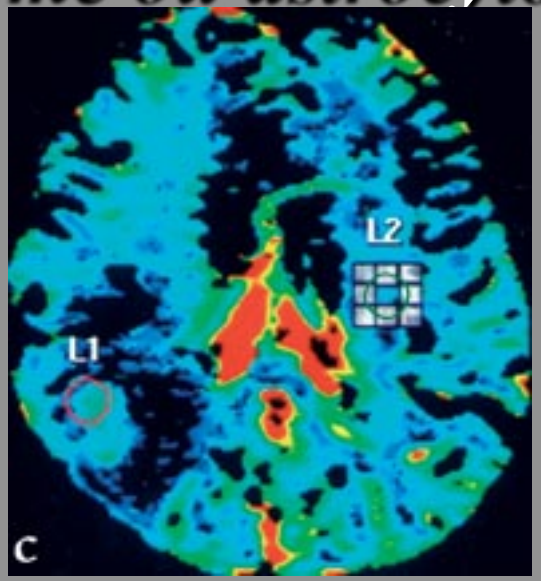

rCBV normal:
Astrocytome pilocytique

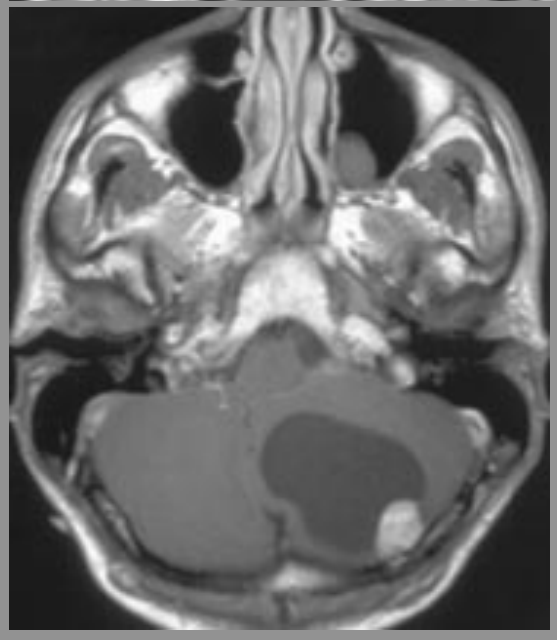

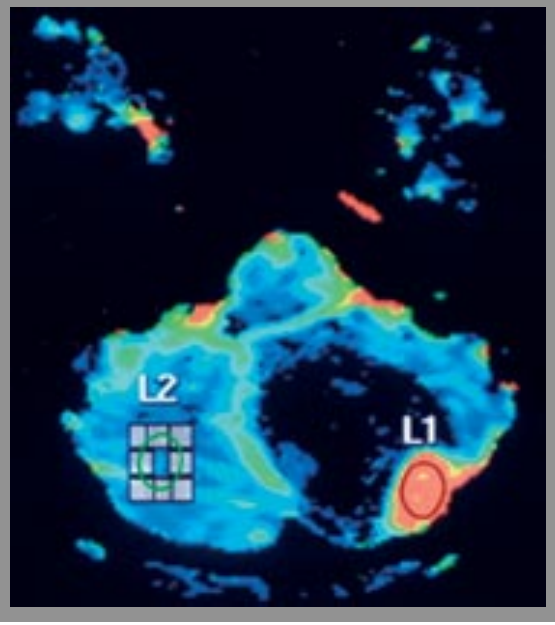

rCBV augmenté:
Hémangioblastome

Equipe Grenoble

JF Le Bas, S. Grand
J de radiologie 2006

Homme de 64 ans, ayant présenté deux crises d' épilepsie

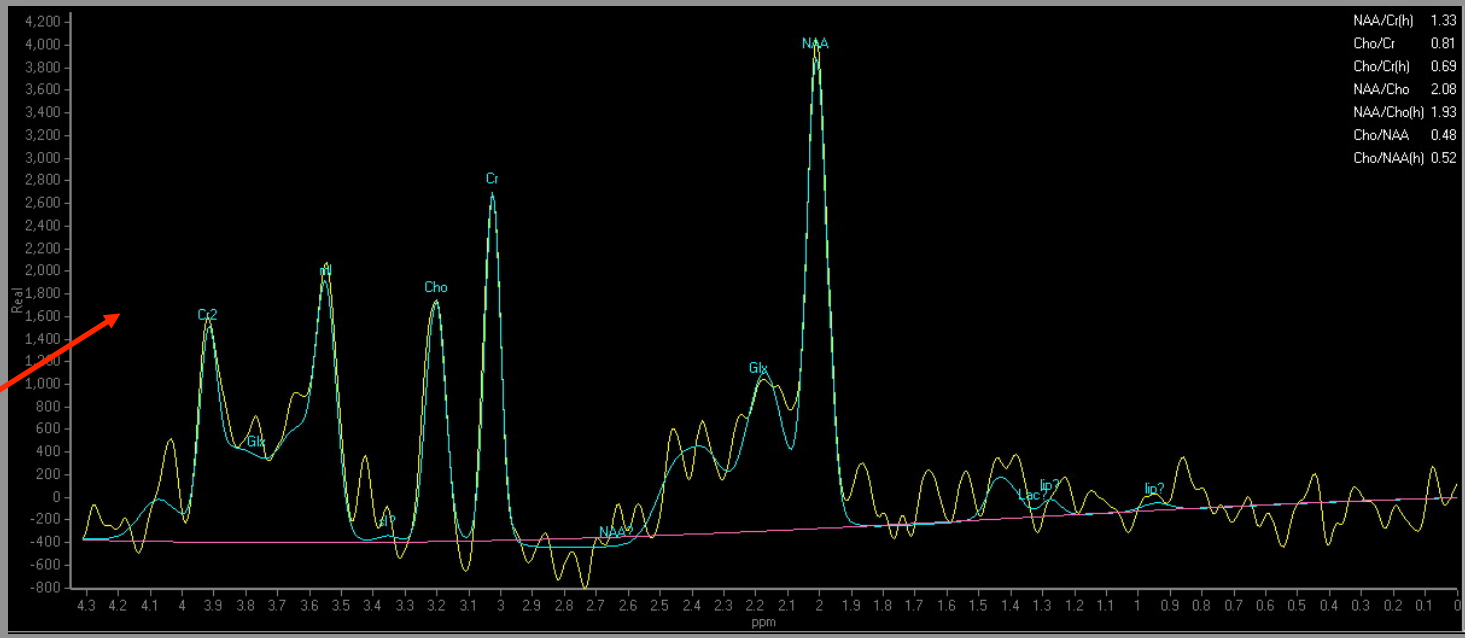

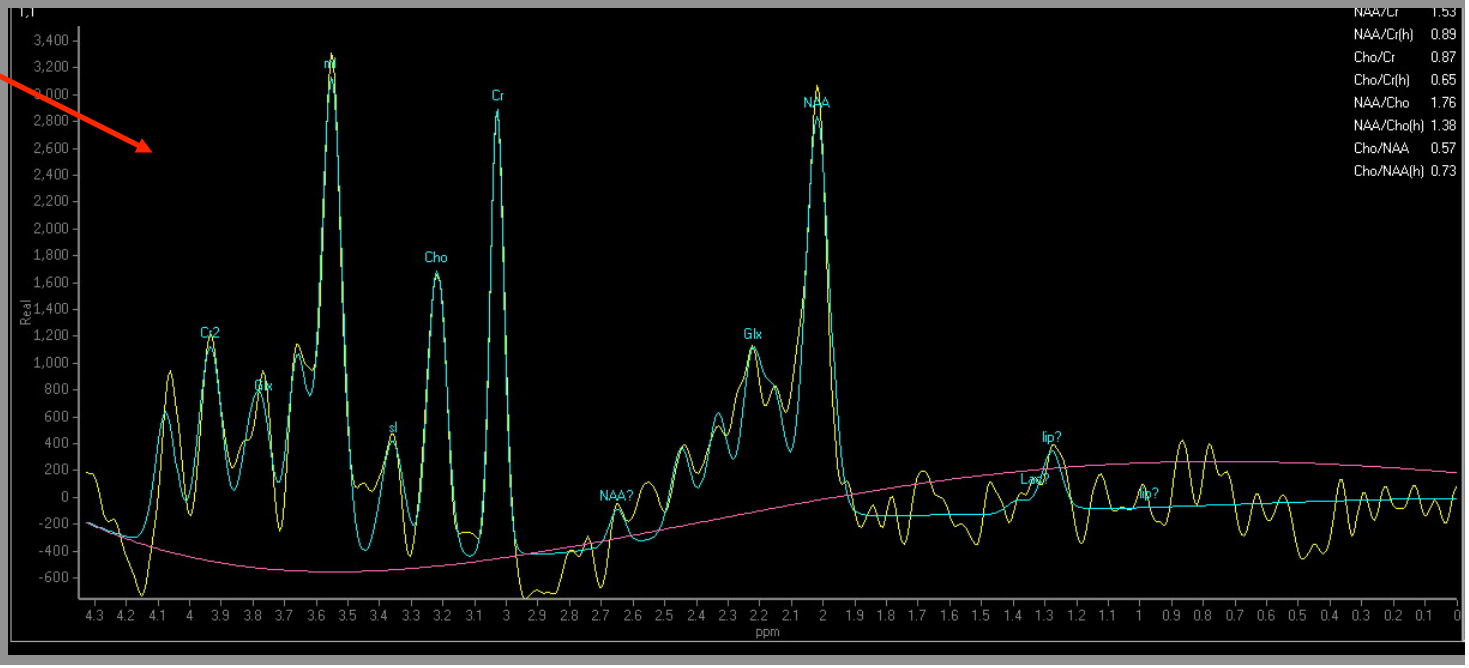

GLIOMATOSE

La spectroscopie apparaît supérieure à la perfusion pour évaluer la gliomatose : faux abaissement de la choline par **élévation de la créatine**, élévation importante du **myoinositol**.

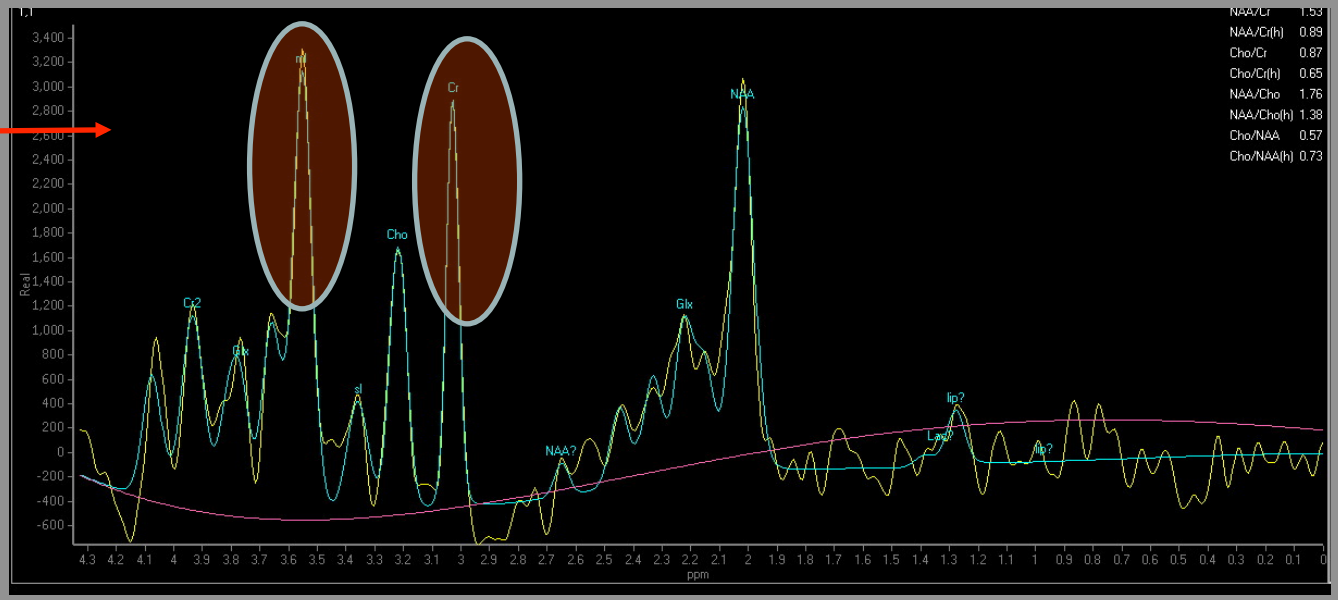

L'élévation de la choline est corrélée au grade et inversement proportionnelle à la survie.

Quelques messages

1- L'imagerie multimodale apporte des éléments déterminants pour la caractérisation des gliomes.

2- L'interprétation de l'imagerie doit tenir compte de l'évolution naturelle de ces lésions.

3- Un patient présentant un gliome avec dans la lésion une élévation du ratio choline/créatine supérieur à 2 et un rCBV supérieur à 2 par rapport au côté sain a un risque élevé de présenter un virage anaplasique dans les 2 ans suivants.

4- Le diagnostic parfois difficile entre métastase, lymphome et gliome de haut grade se fait par l'analyse du couple perfusion/spectroscopie

5- le diagnostic différentiel entre astrocytome pilocytique et hémangioblastome est basé sur les données de la perfusion

Journée de la SFR-RA du samedi 24 mars 2012
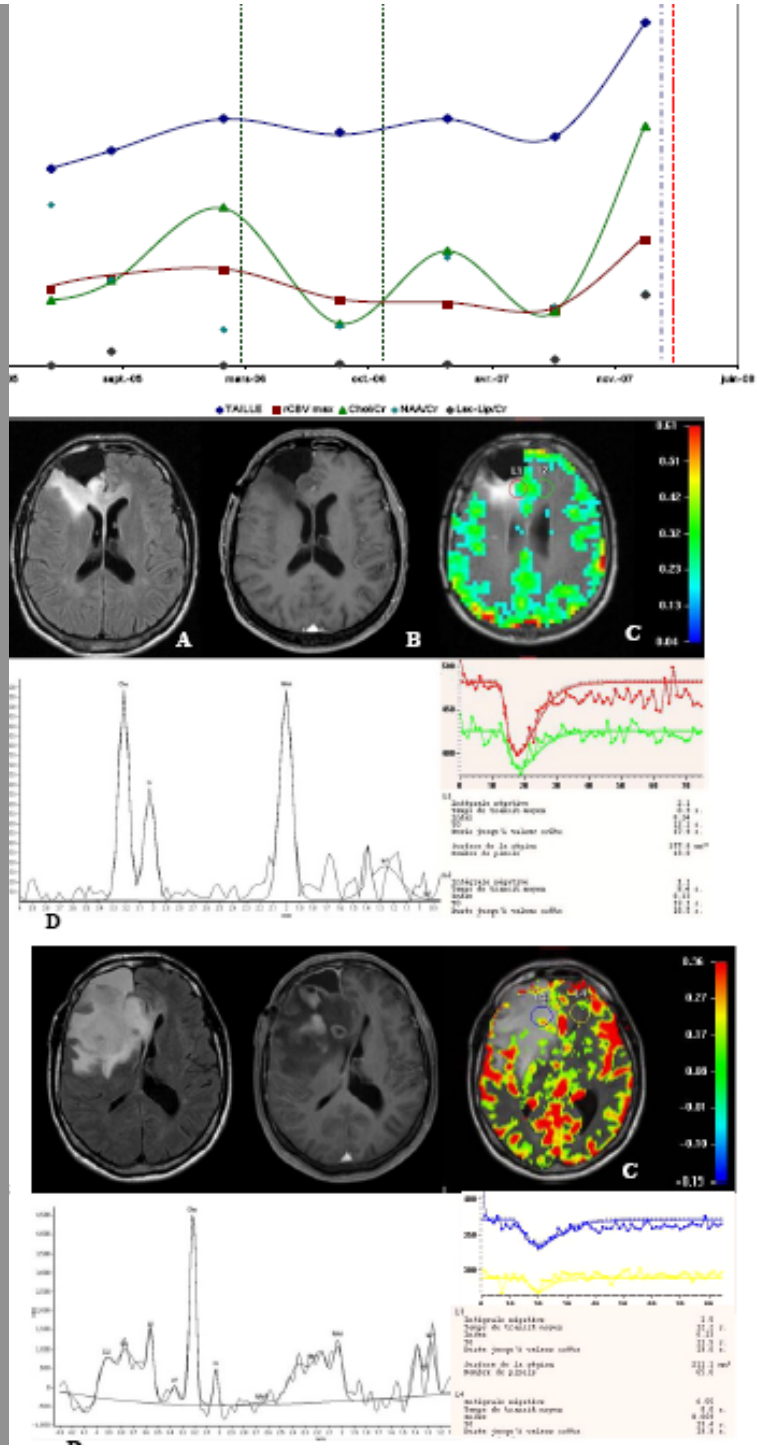
Je vous remercie