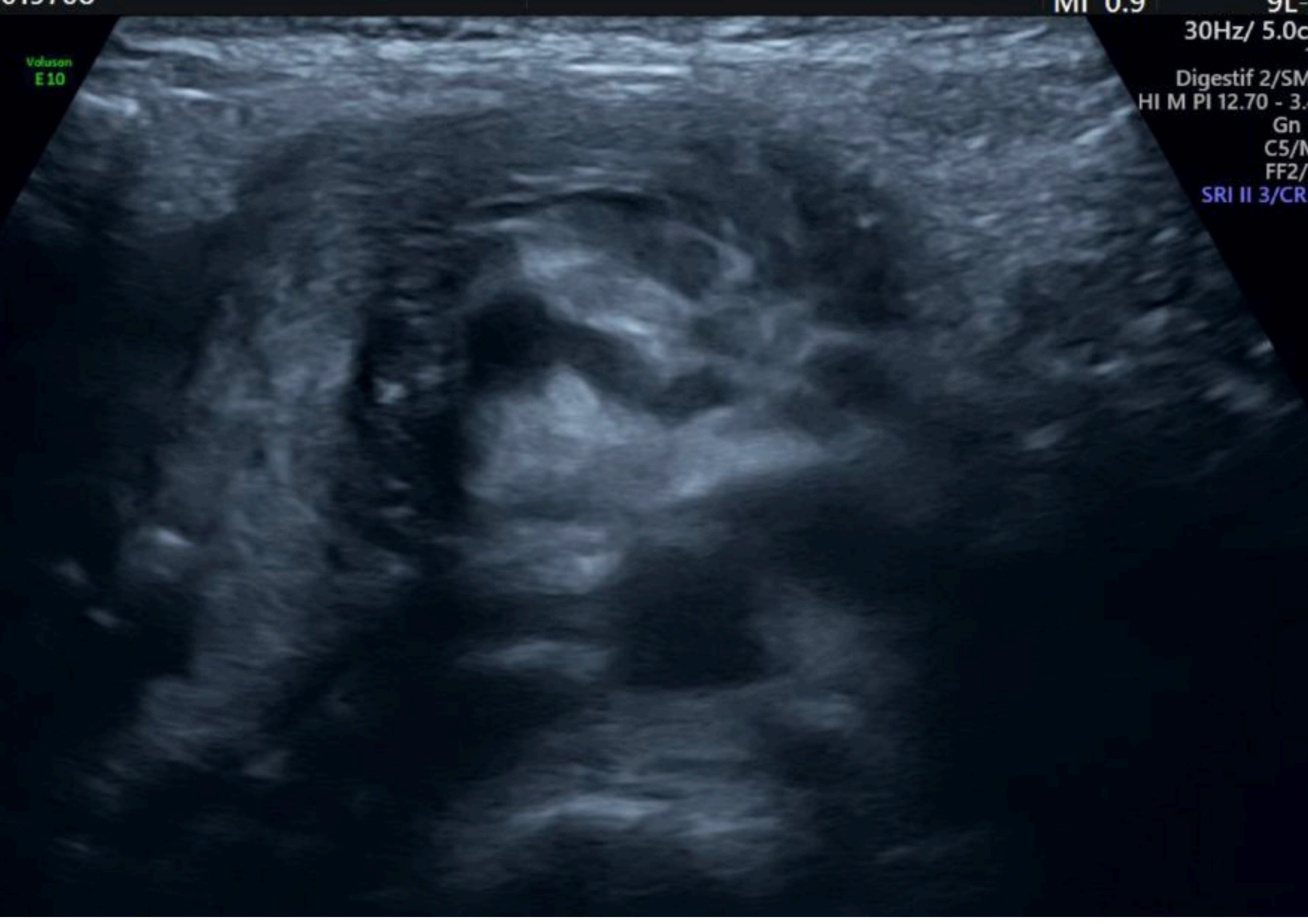

ERYAN

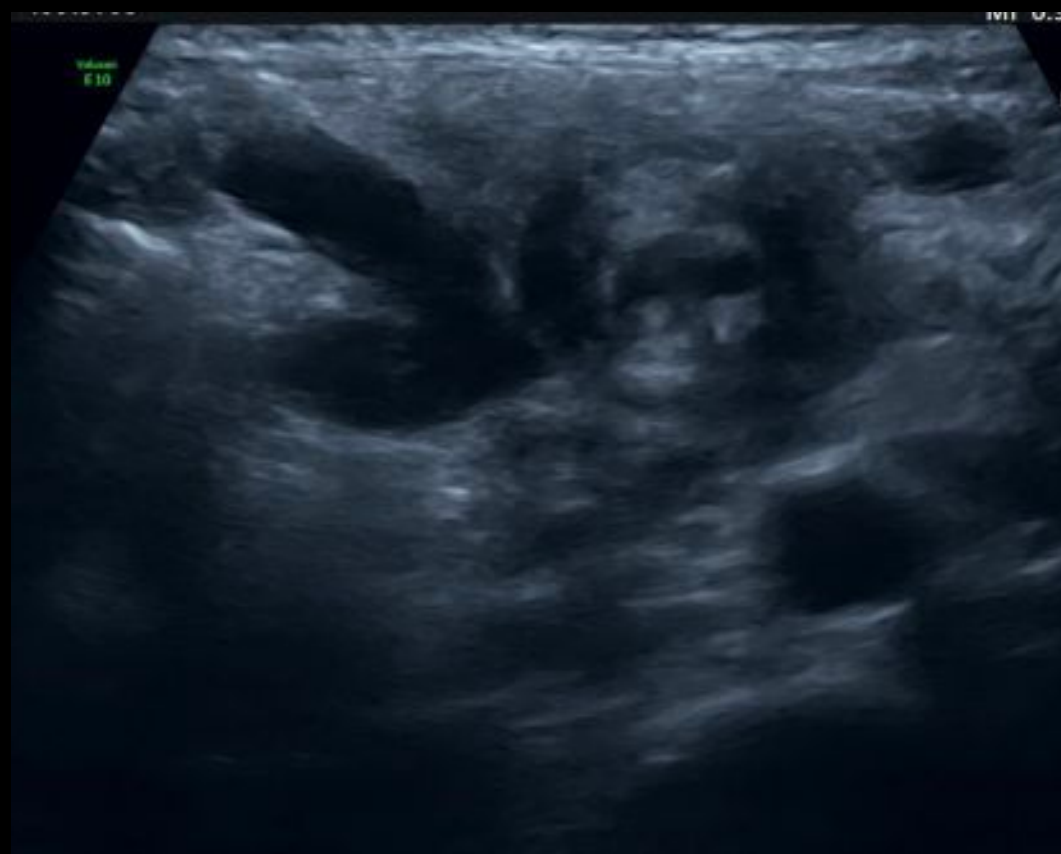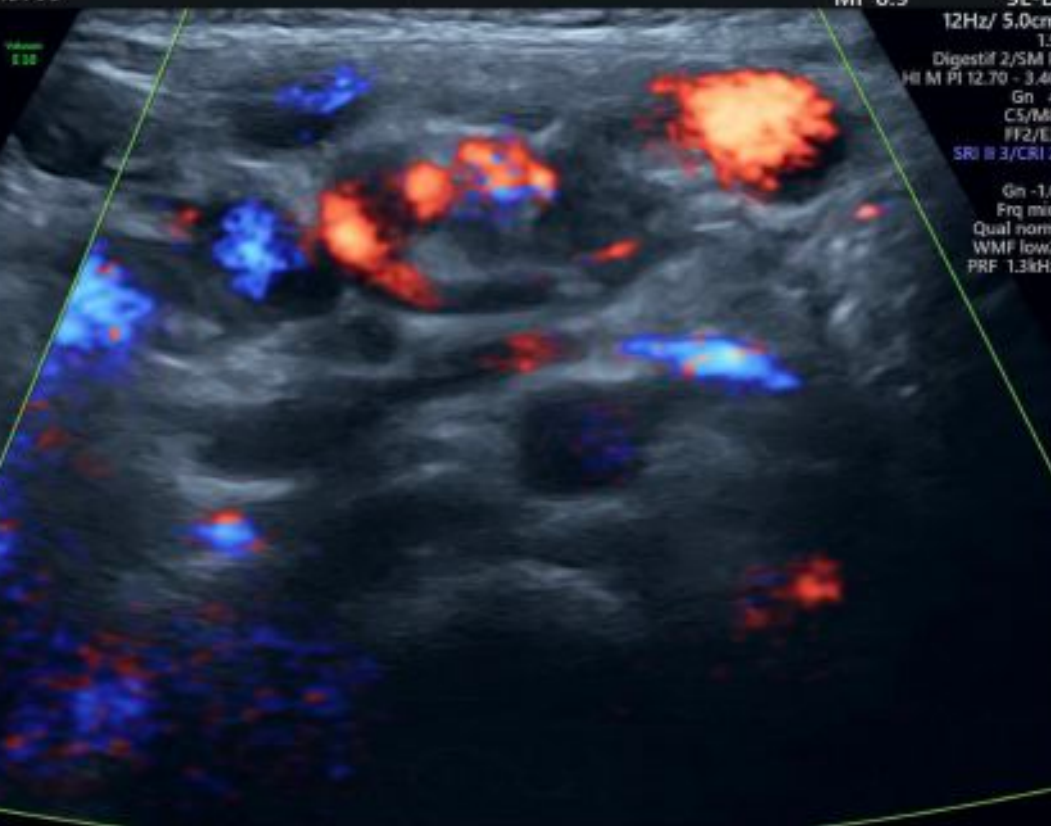
Enfant de 2 ans 1/2

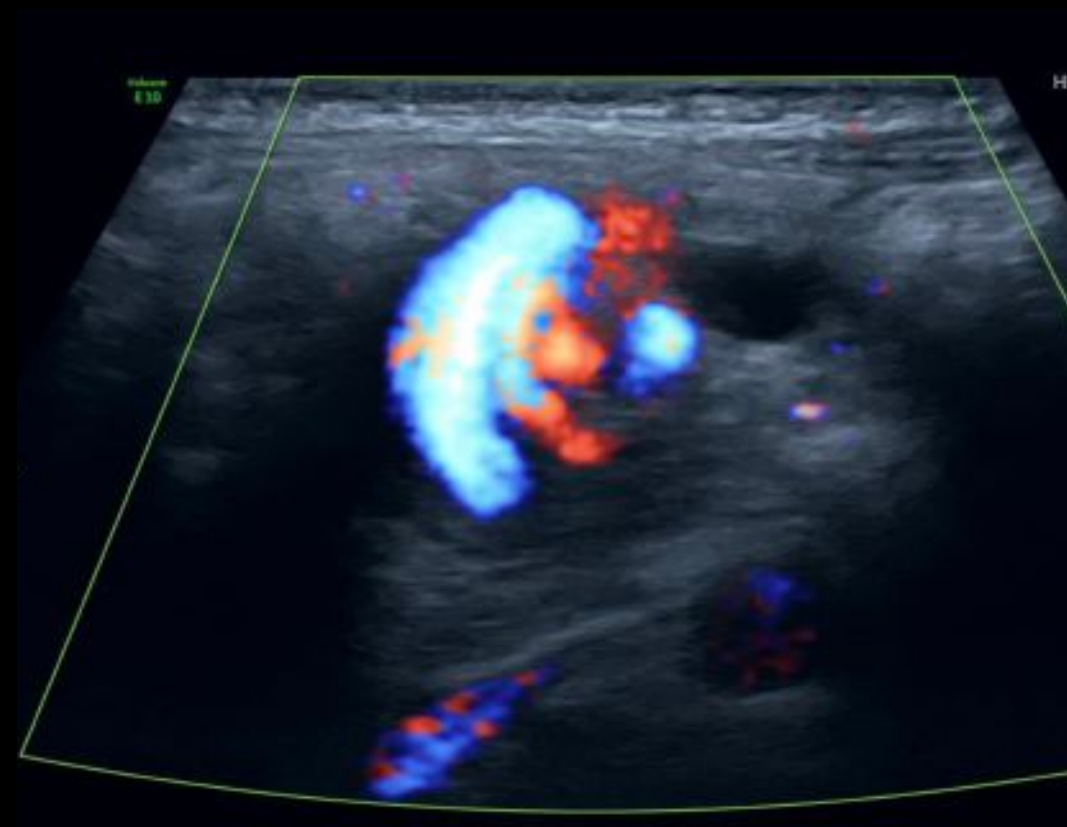
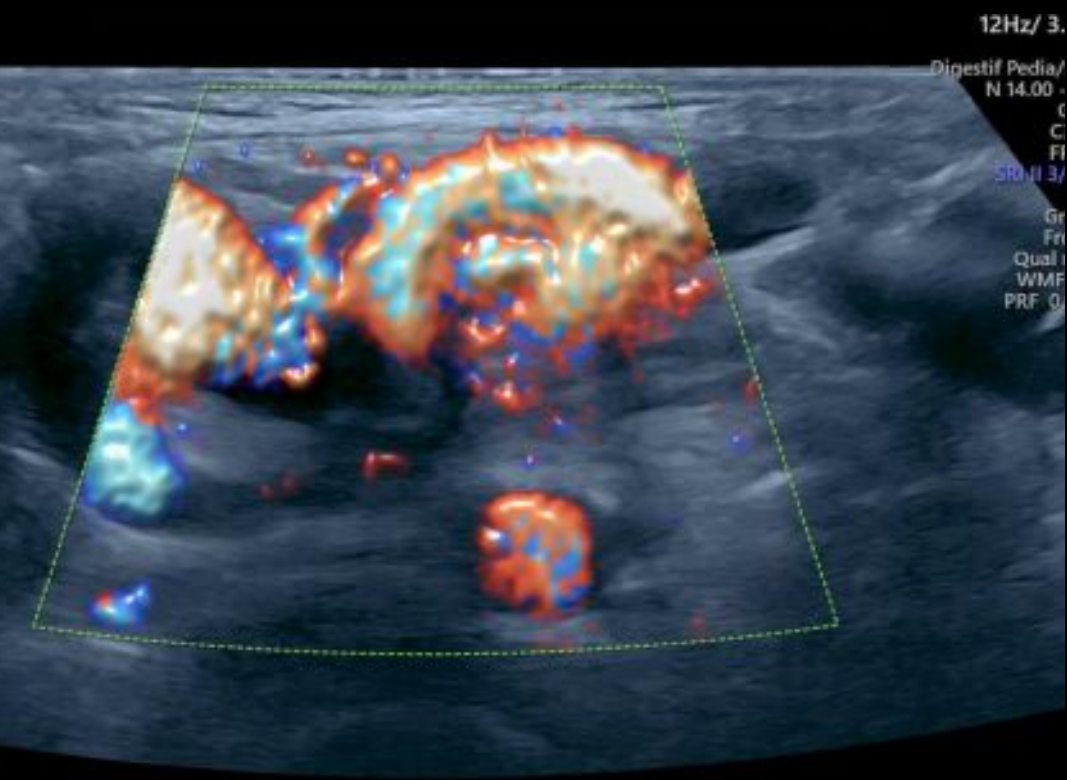
- **Douleurs abdominales chroniques**
- **Constipation**
- **Vomissements épisodiques depuis plusieurs mois**

Voluson
E10



19/08





Avis chirurgical :

- Abdomen ballonné
- Hospitalisé pour surveillance

Exploration chirurgicale:

- Coelioscopie
- Convertie en Laparotomie:
 - . Dévolvulus
 - . Cure de méésentère incomplet
 - . Section de bride de Ladd

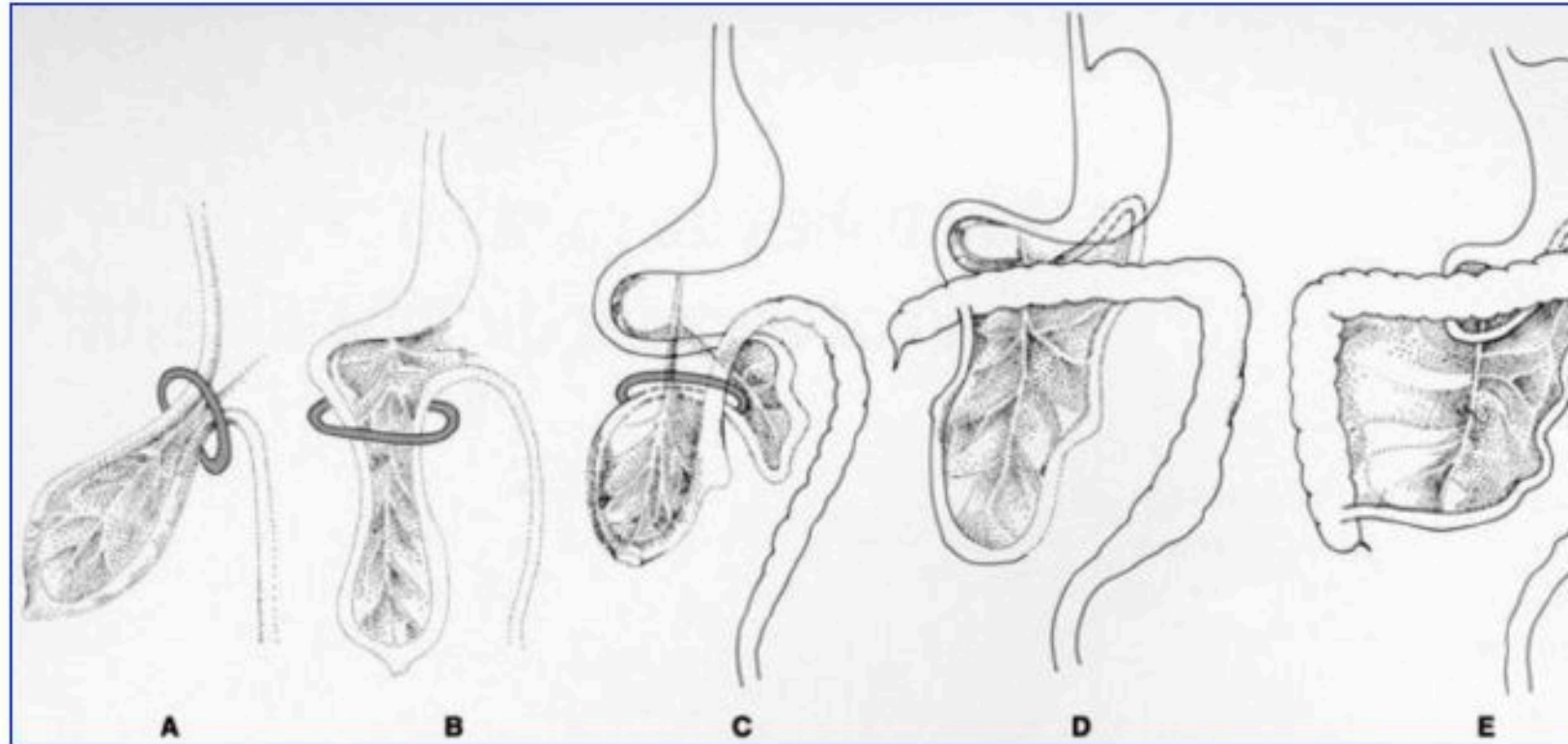


Fig 1 :

Embryologie de la rotation intestinale (d'après Smith).

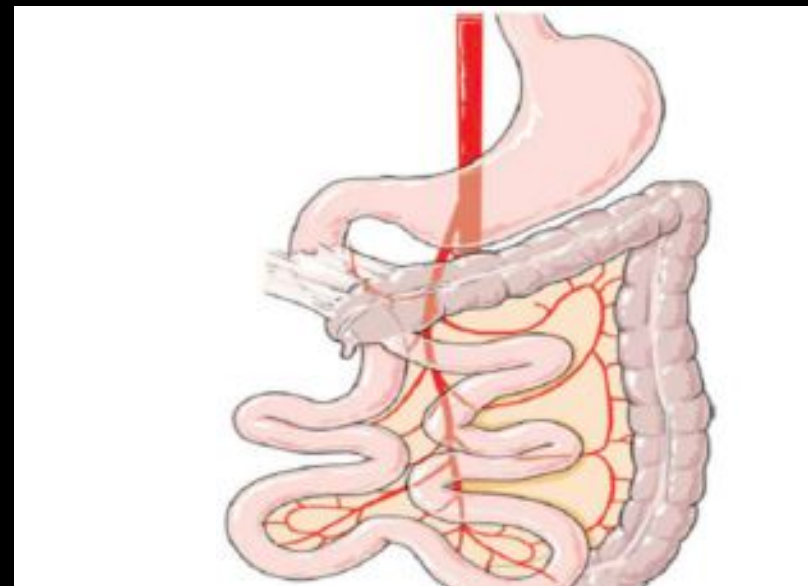
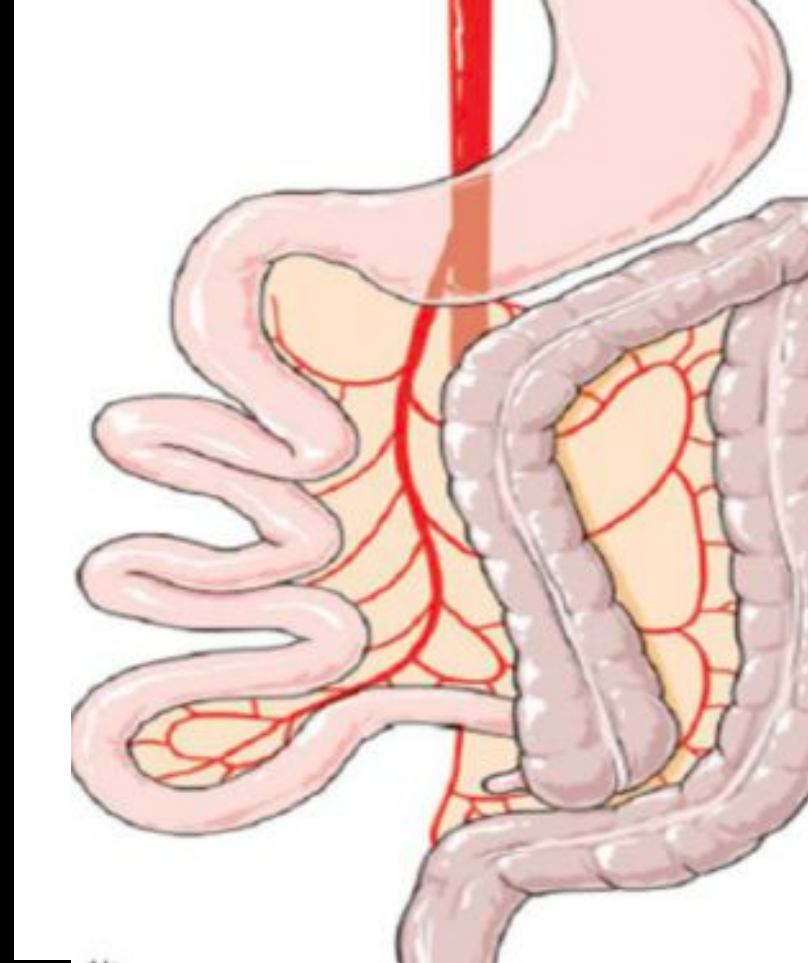
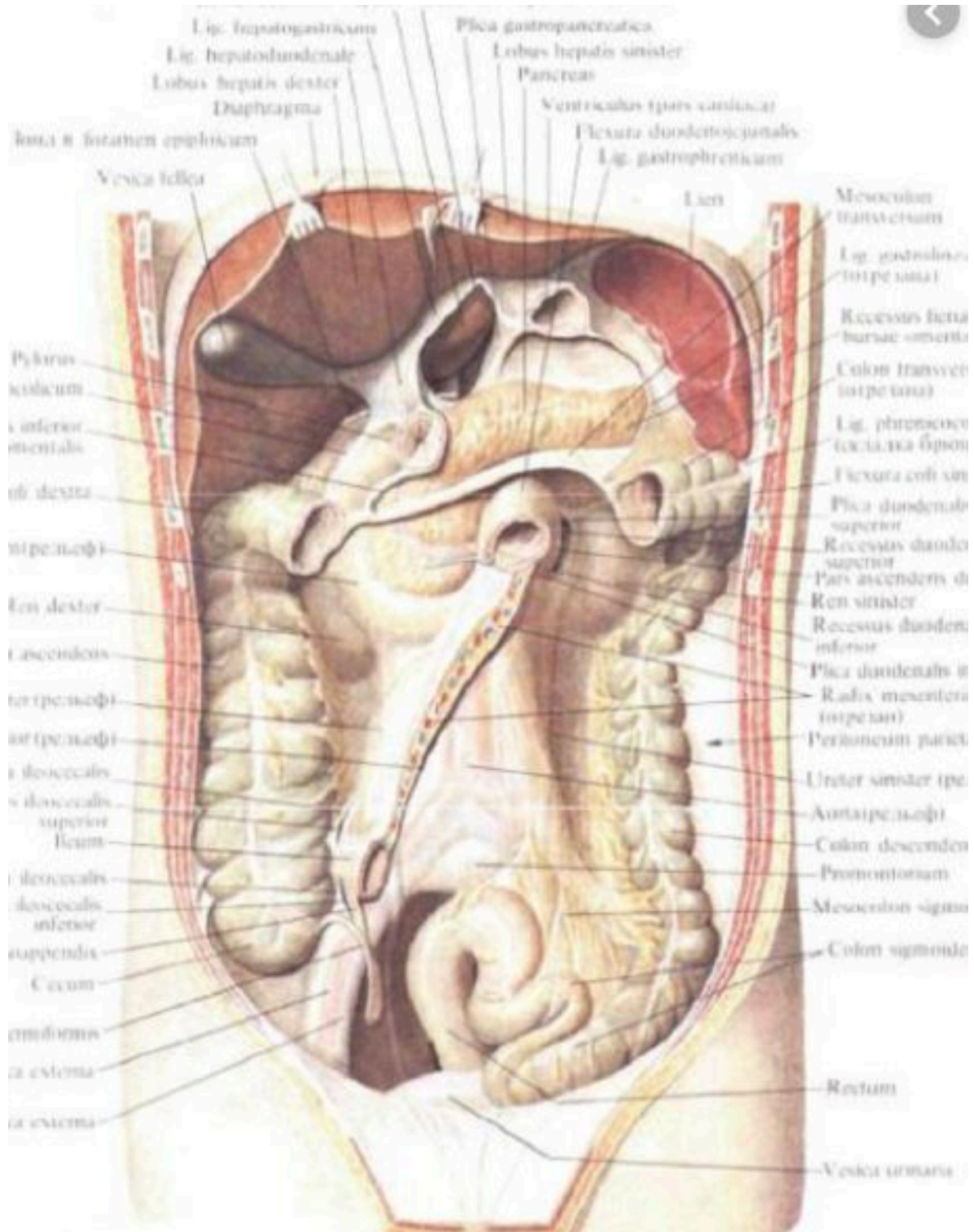
A. Disposition initiale avant la sixième semaine.

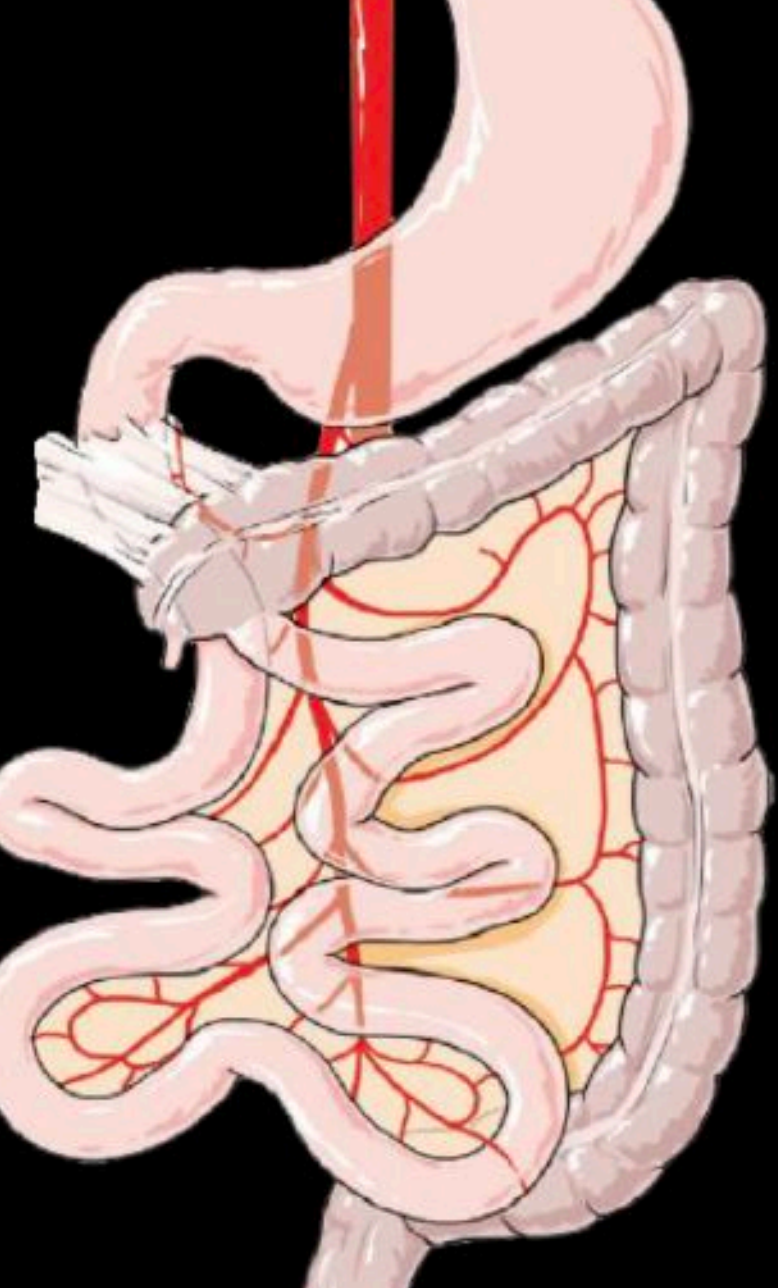
B. Rotation de 90°.

C. Rotation de 180°.

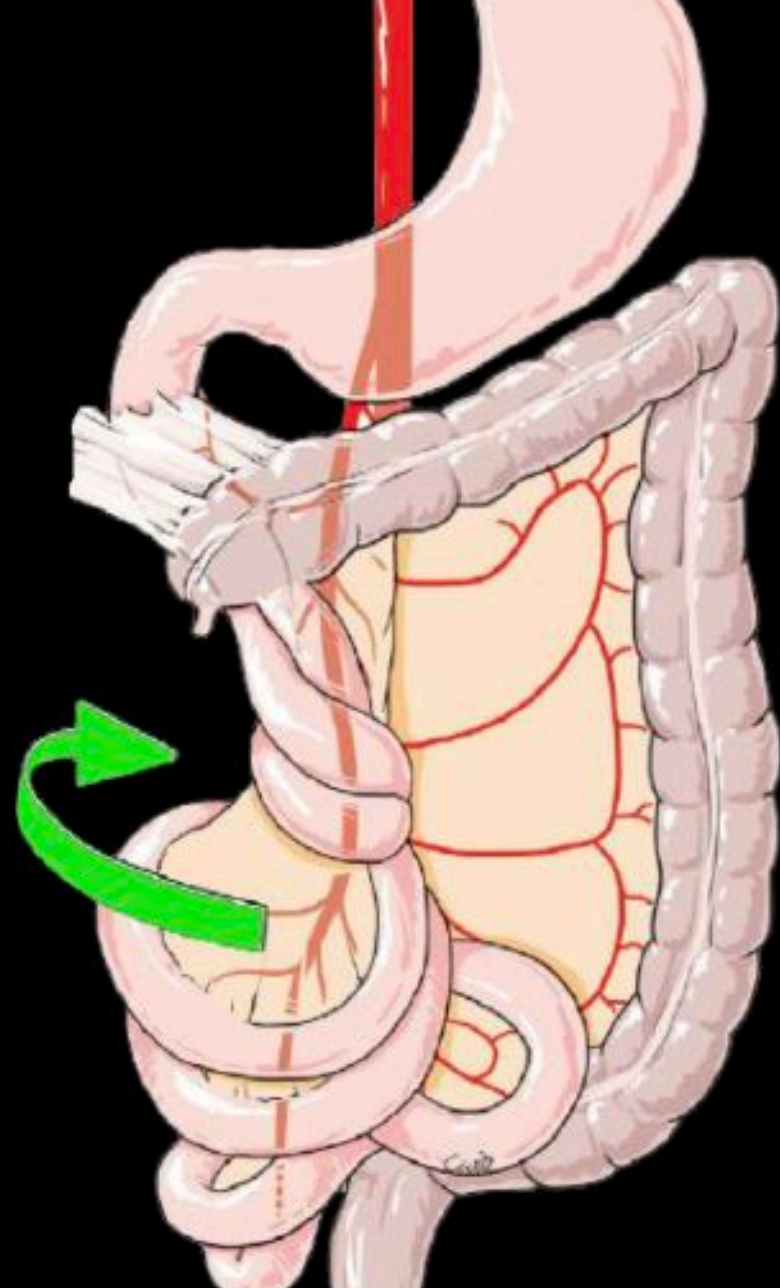
D. Rotation de 270°

E. Disposition définitive.





Malrotation



Volvulus



