



# IRM de la Maladie d'Alzheimer et des Maladies Apparentées

*Réalités cliniques*

Alexandre Krainik

Clinique Universitaire de Neuroradiologie et d'IRM – CHU Grenoble

Grenoble Institut des Neurosciences

# Neuro-imagerie et MAMA


---

## Objectifs

- → Connaître la démarche diagnostique
- → Connaître les recommandations en neuro-imagerie
- → Connaître les avantages et les limites de la neuro-imagerie

# Introduction

---




A. Alzheimer (1864-1915)

- Démence : syndrome clinique
  - Affaiblissement intellectuel global : mémoire et/ou autres fonctions
  - Habituellement chronique (> 6 mois) → handicap
  - Causes nombreuses (sujet âgé : M. d'Alzheimer ++)
- Épidémiologie
  - Prévalence : 24-33% > 85 ans
  - MA : 600 000 pers.
  - MAMA : 860 000 pers. > 65 ans en 2004 → 1 200 000 pers. en 2020
- Diagnostic différentiel
  - Confusion mentale
  - Dépression
- Traitement
  - Possibilité de stabilisation si diagnostic précoce : Troubles Cognitifs Légers
    - Inhibiteurs de l'acétylcholinestérase (donepezil, rivastigmine,...)
    - Antagoniste récepteur NMDA (memantine), ...
  - Pop. < 1 million → Pop. «totale» → Enjeu santé publique, dépistage, prévention,...?

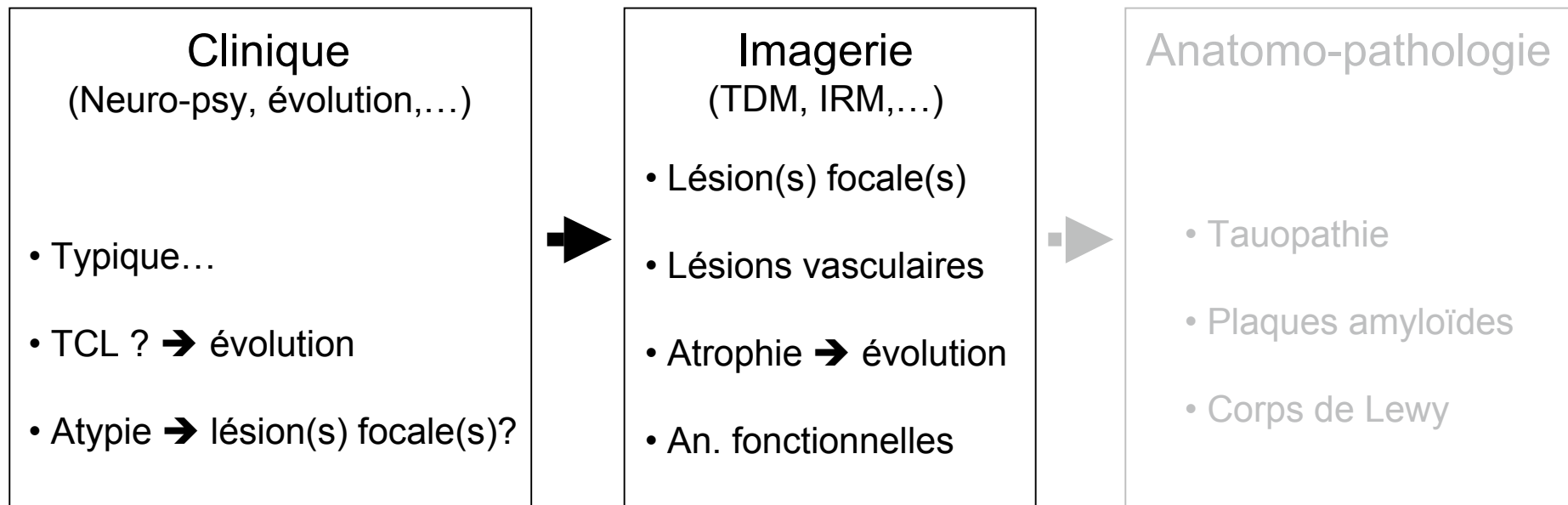
*Blennow Lancet 2006*

# Approche diagnostique

## Troubles cognitifs (Plainte mnésique)



Blenow *Lancet* 2006



Autres : dosages LCR (Total-tau, phosphorylated-tau, A $\beta$ 42)

# Neuro-imagerie clinique : recommandations 2008

---

- Imagerie initiale systématique
- Objectifs
  - Éliminer un processus expansif intracrânien
  - Identifier des lésions vasculaires
  - Recherche une atrophie cérébrale
- IRM : T1, T2 (FLAIR), T2\* ; plan frontal → hippocampe
- Sinon TDM sans IV
- TEMP, TEP si doute DFT ; DATscan si doute DCLewy



# Neuro-imagerie et MAMA

---

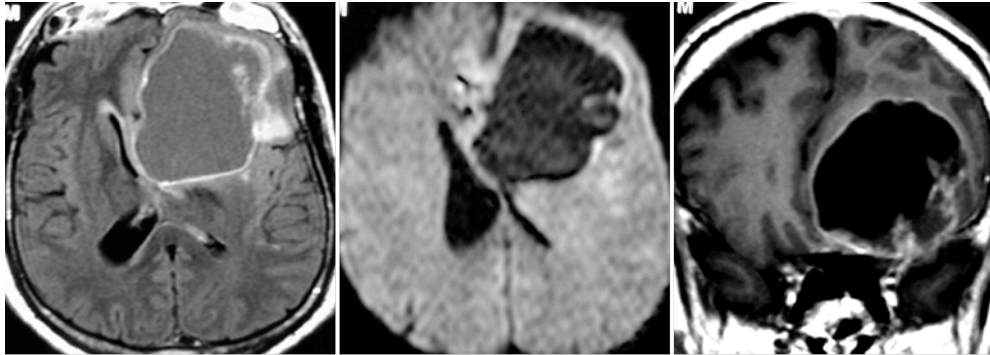
## Démarche diagnostique

- → Démence « chirurgicale » ?
- → Démence « médicale » ?
- → Démence « neurodégénérative » ?

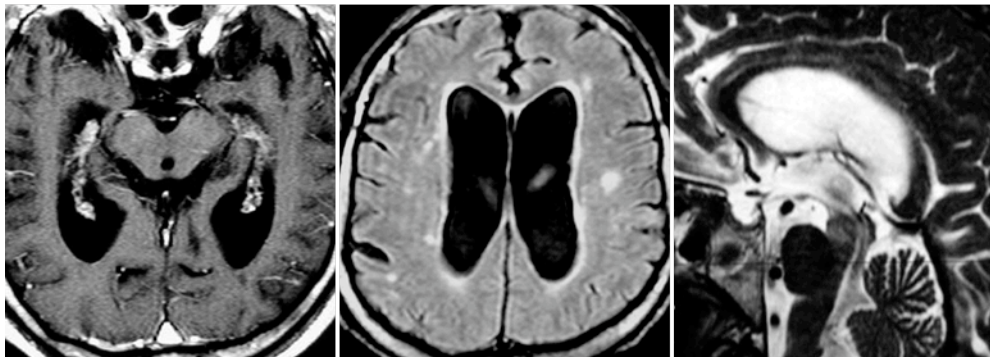
# Rechercher une démence « chirurgicale »

---

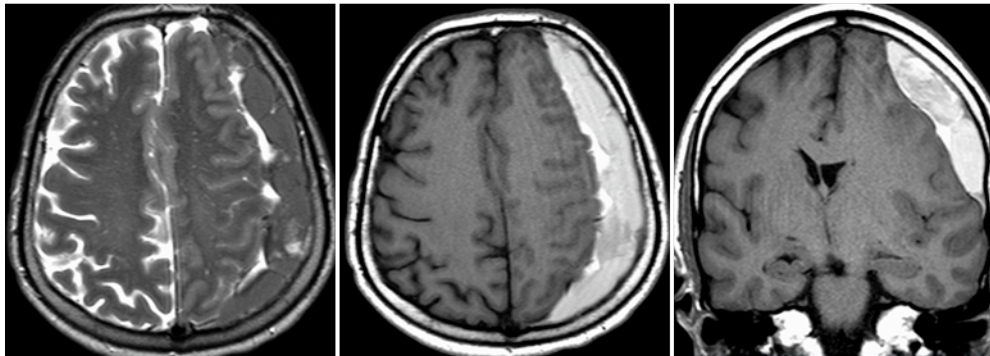
Tumeur



HCA



HSD

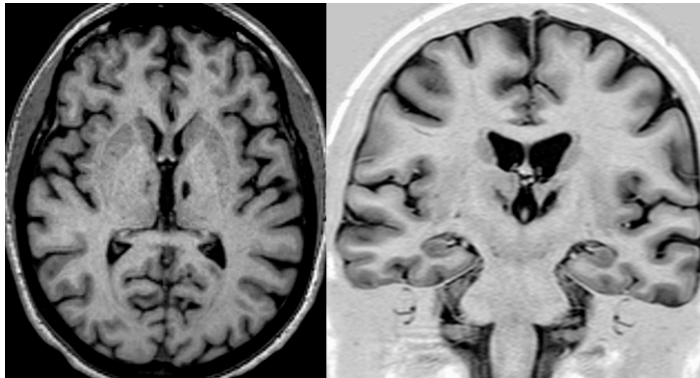


# Rechercher une démence « médicale »

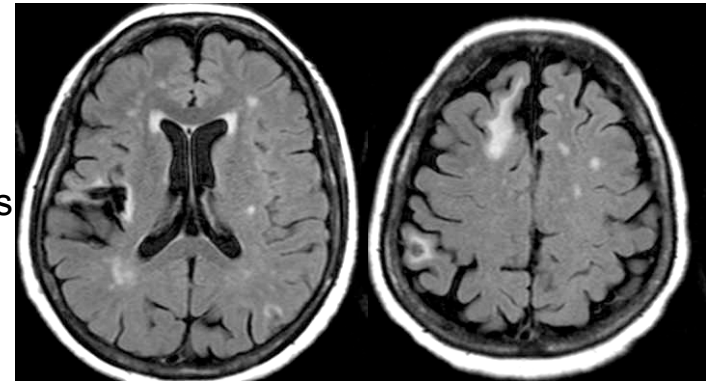
---

- Vasculaire : multi-lacunaire, CADASIL,...
- Infection (BK, VIH, Creutzfeld-Jacob nv, syphilis,...)
- Inflammation (MAI, SEP, ...)
- Traumatique
- Tumorale : S. paranéoplasique, LMNH, ...
- Toxique : Alcool, carence (Gayet-Wernicke),...

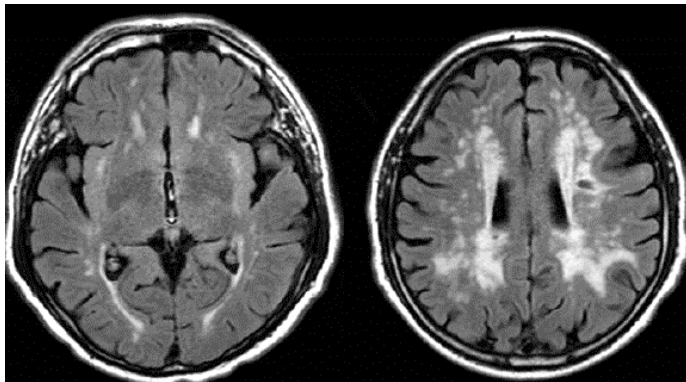
AVC  
bi-thalamique



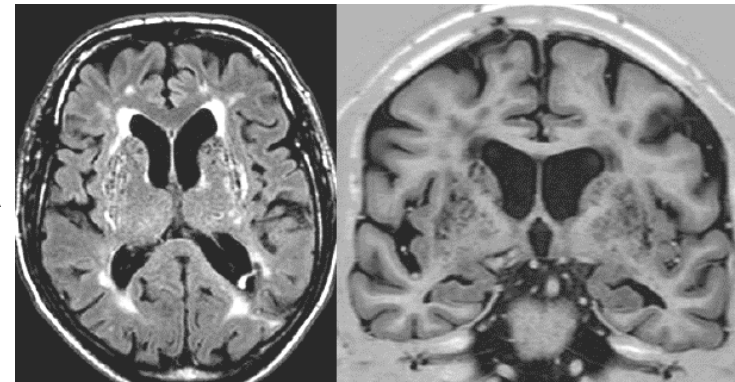
AVC  
multiples



CADASIL



HTA





# Microangiopathie

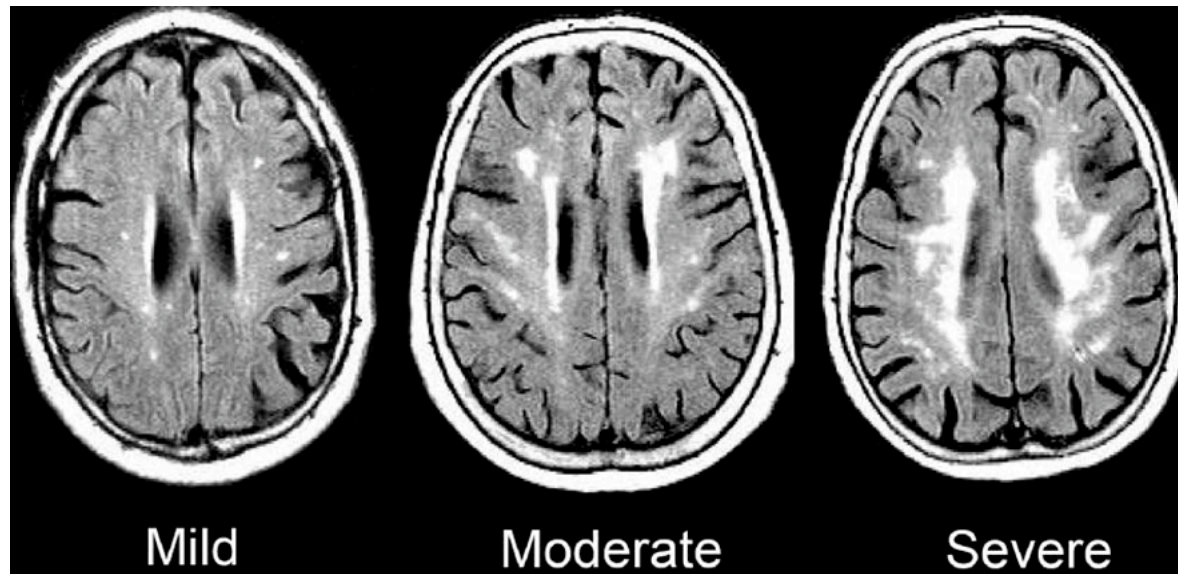
---

Echelle de Fazekas AJNR 1987

Grade 1 (mild changes) = single lesions <10 mm and/or areas of “grouped” lesions <20 mm in any diameter

Grade 2 (moderate changes) = single hyperintense lesions 10-20 mm, and hyperintense areas linked by no more than “connecting bridges” >20 mm in any diameter

Grade 3 (severe changes): both single and confluent hyperintense areas of  $\geq 20$  mm in any diameter)



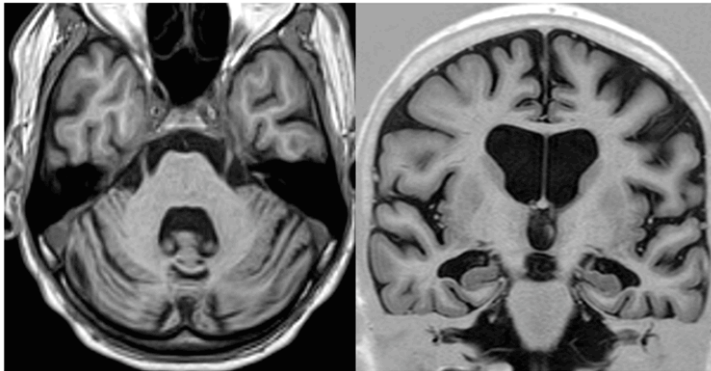
Inzitari BMJ 2009

# Rechercher une démence « médicale »

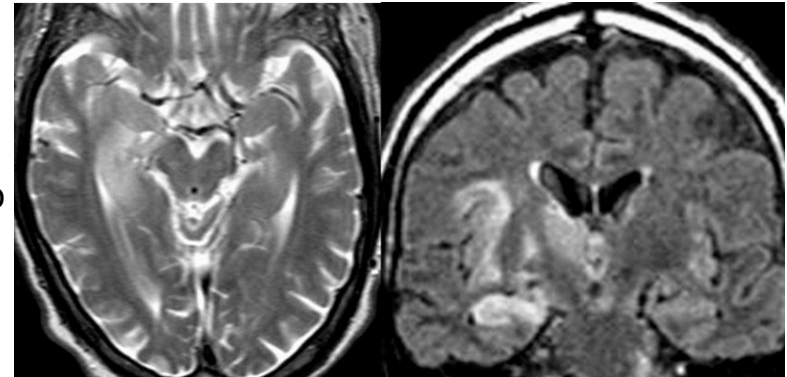
---

- Vasculaire : multi-lacunaire, CADASIL,...
- Infection (BK, VIH, Creutzfeld-Jacob nv, syphilis,...)
- Inflammation (MAI, SEP, ...)
- Traumatique
- Tumorale : S. paranéoplasique, LMNH, ...
- Toxique : Alcool, carence (Gayet-Wernicke),...

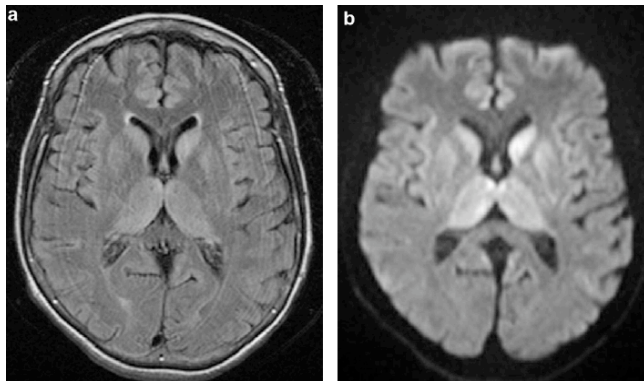
OH



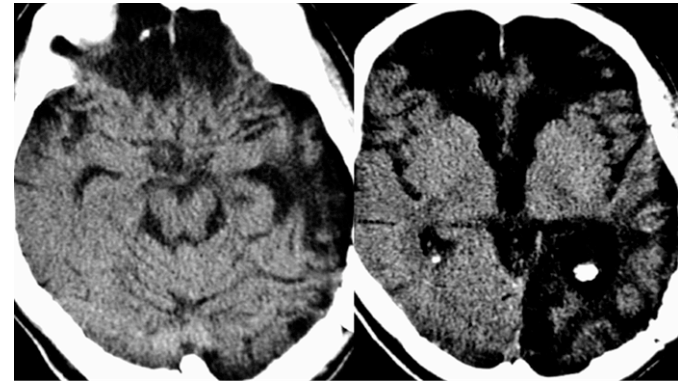
EL Paranéo



MCJ



Trauma



Nougaret, *J Neuroradiol* 2007

# Rechercher une démence « neurodégénérative »

---

- Maladie d'Alzheimer
- Dégénérescence à prédominance Fronto-Temporale (APP, DS,...)
- Maladie à Corps de Lewy
- Paralyse supra-nucléaire progressive
- Dégénérescence cortico-basale

# Neuro-imagerie clinique : recommandations 2008

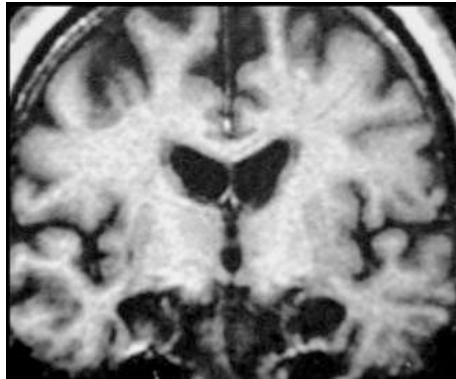
---

- Imagerie initiale systématique
- Objectifs
  - Éliminer un processus expansif intracrânien
  - Identifier des lésions vasculaires
  - Recherche une atrophie cérébrale
- IRM : T1, T2 (FLAIR), T2\* ; plan frontal → hippocampe
- Sinon TDM sans IV
- TEMP, TEP si doute DFT ; DATscan si doute DCLewy



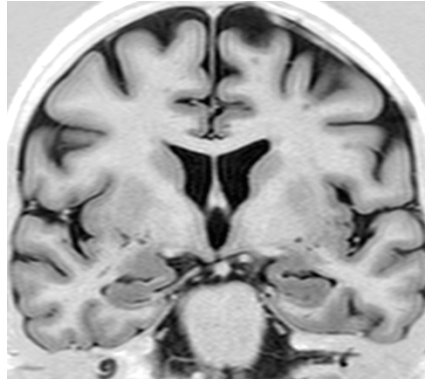
# Morphométrie de l'hippocampe

HM

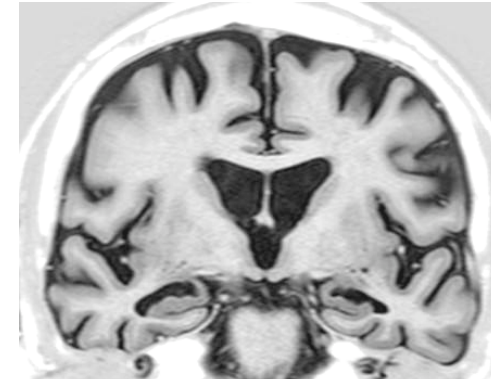


Corkin, *J Neurosci* 1997

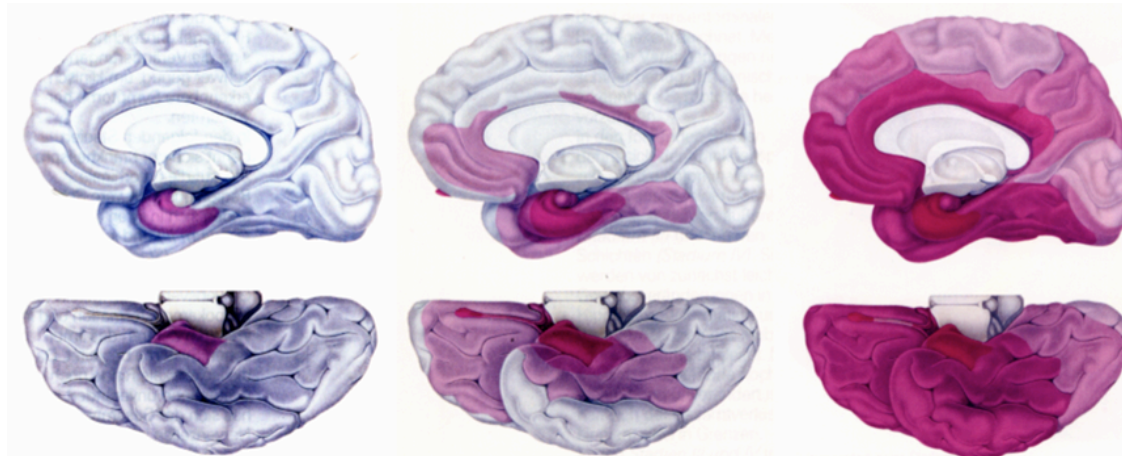
Sain



MA



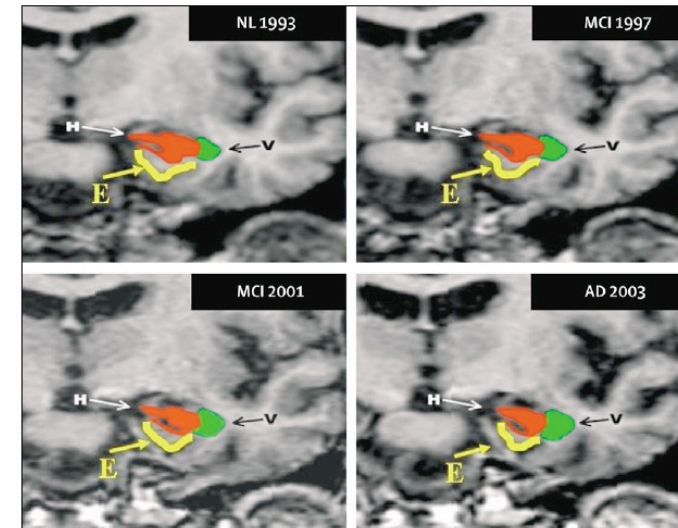
## Tauopathie - Braak



St. I-II  
Transentorhinal

St. III-IV  
Limbique

St. V-VI  
Neocortical



Blennow *Lancet* 2006

# Morphométrie de l'hippocampe

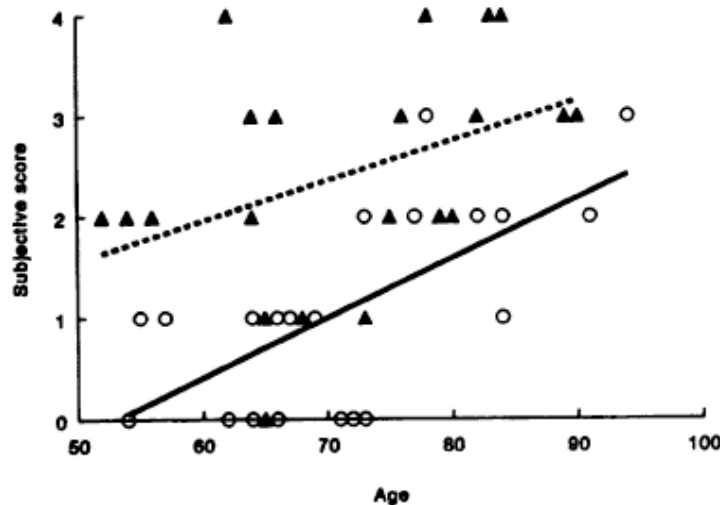
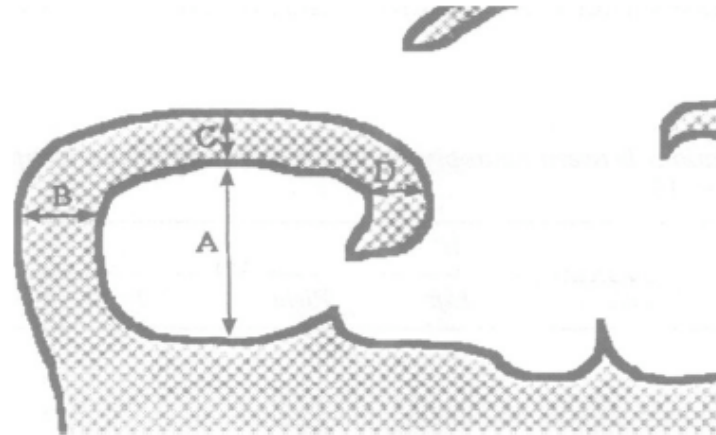
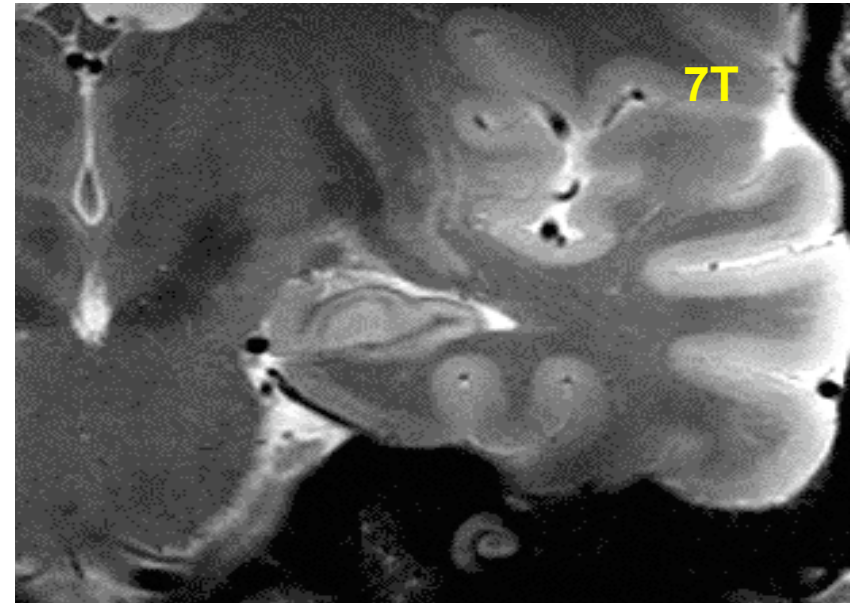


Figure 5 Scatter plot of subjective MTA score versus age in controls (open circles) and Alzheimer's disease patients (closed triangles). Regression lines are drawn in (controls —; Alzheimer's disease - - - - -).



Norris, Radboud Univ. Nijmegen

Table 1 Visual rating of medial temporal lobe atrophy

Score	Width of choroid fissure	Width of temporal horn	Height of hippocampal formation
0	N	N	N
1	↑	N	N
2	↑↑	↑	↓
3	↑↑↑	↑↑	↓↓
4	↑↑↑	↑↑↑	↓↓↓


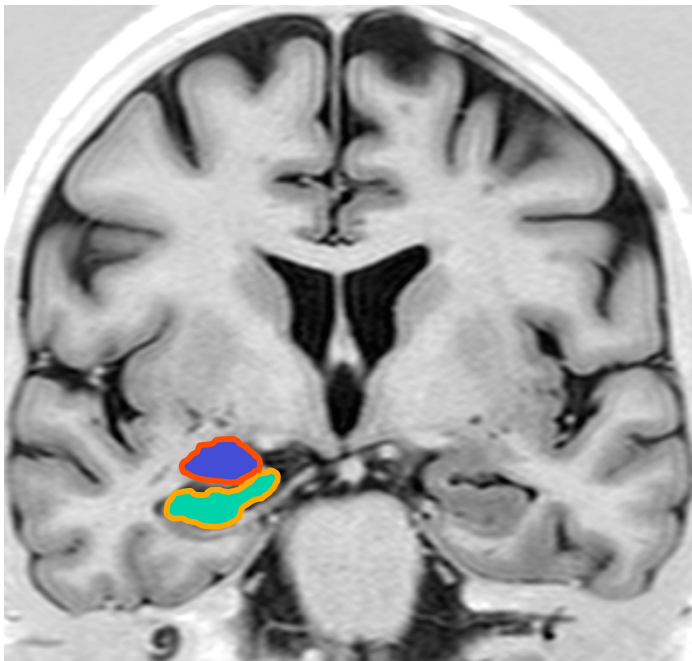
↑ = increase, ↓ = decrease. N = normal.

Scheltens JNNP 1992

# Morphométrie de l'hippocampe

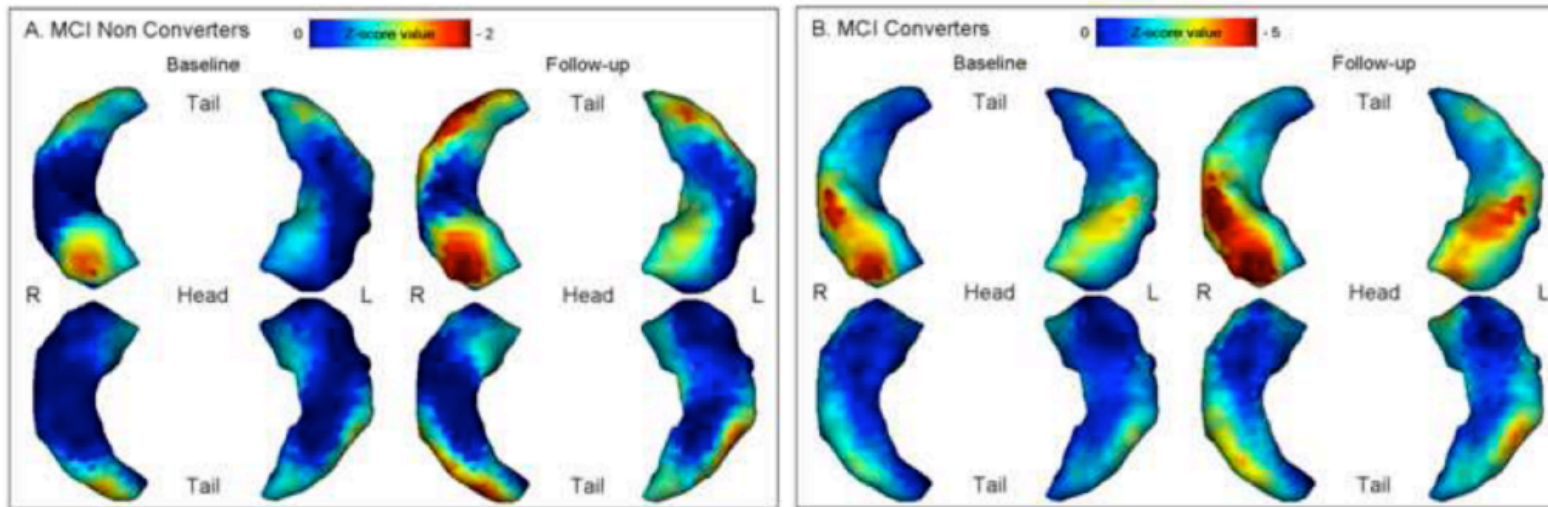
---

- Subjective → ROI manuelles → Semi-automatique

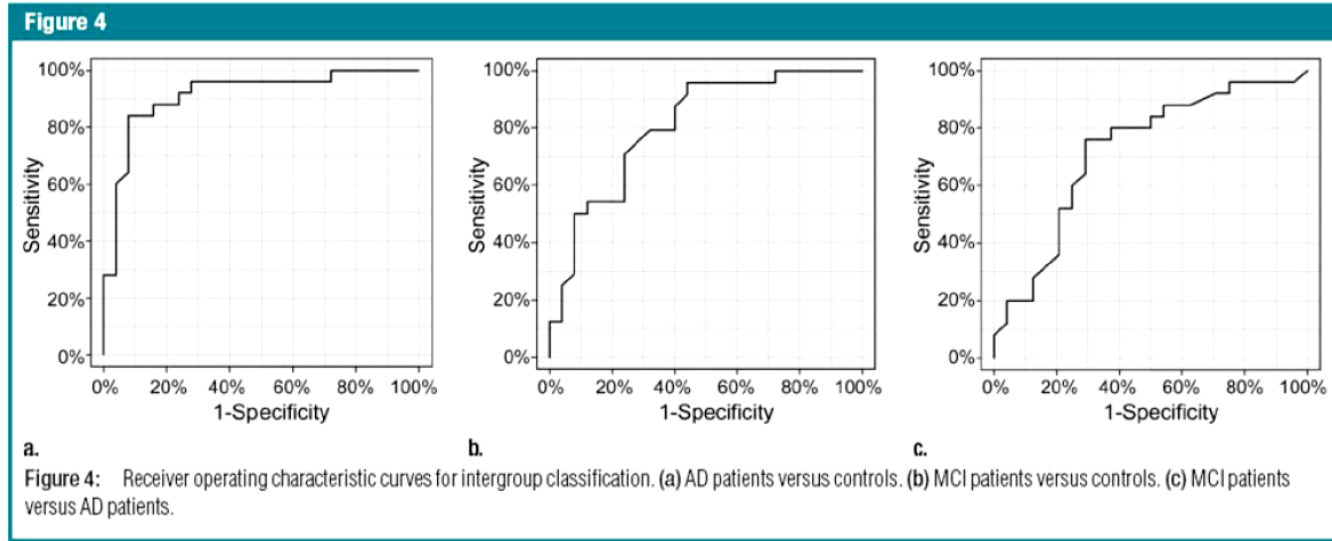
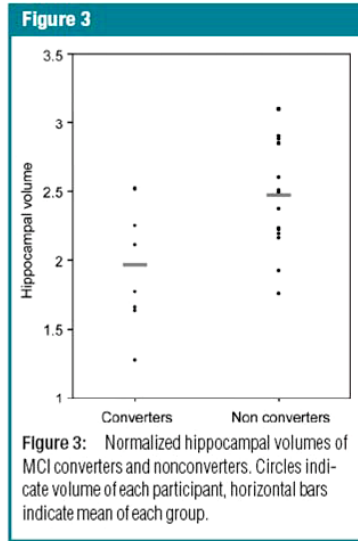


Chupin, *Neuroimage* 2007

# Morphométrie de l'hippocampe



Chetlat *Neuropsychologia* 2008

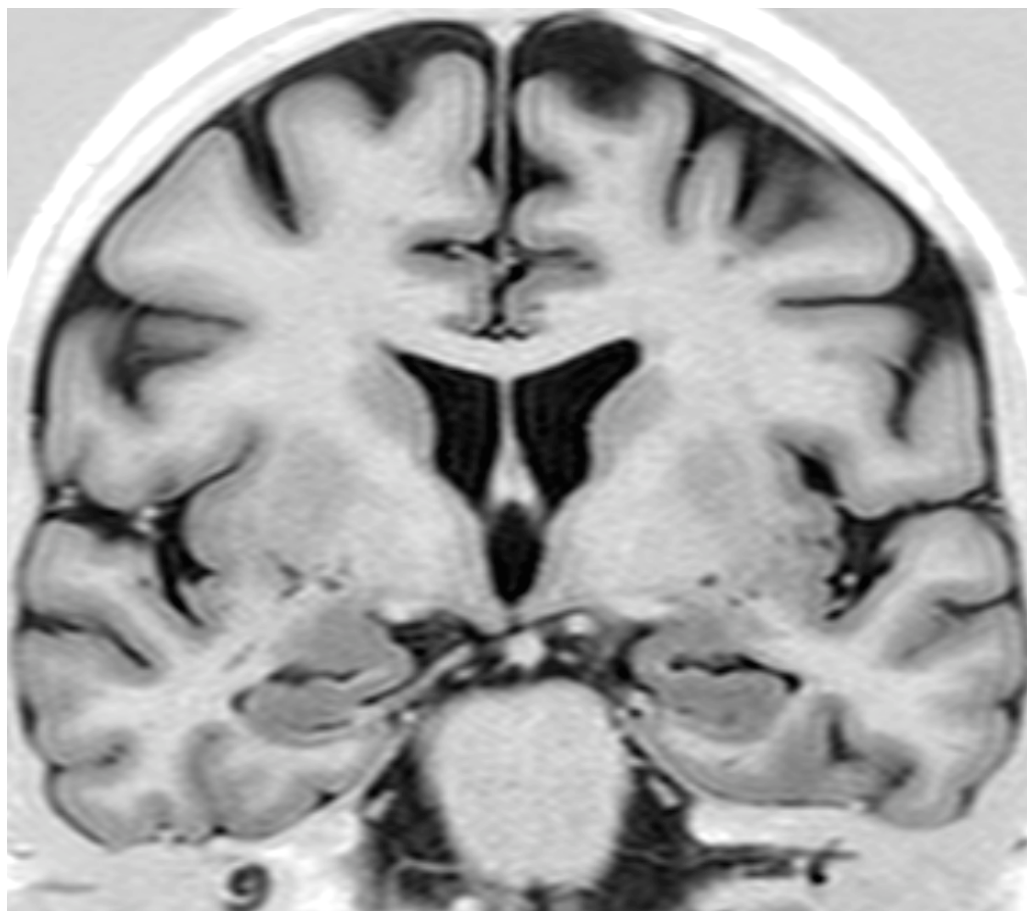


Colliot *Radiology* 2008



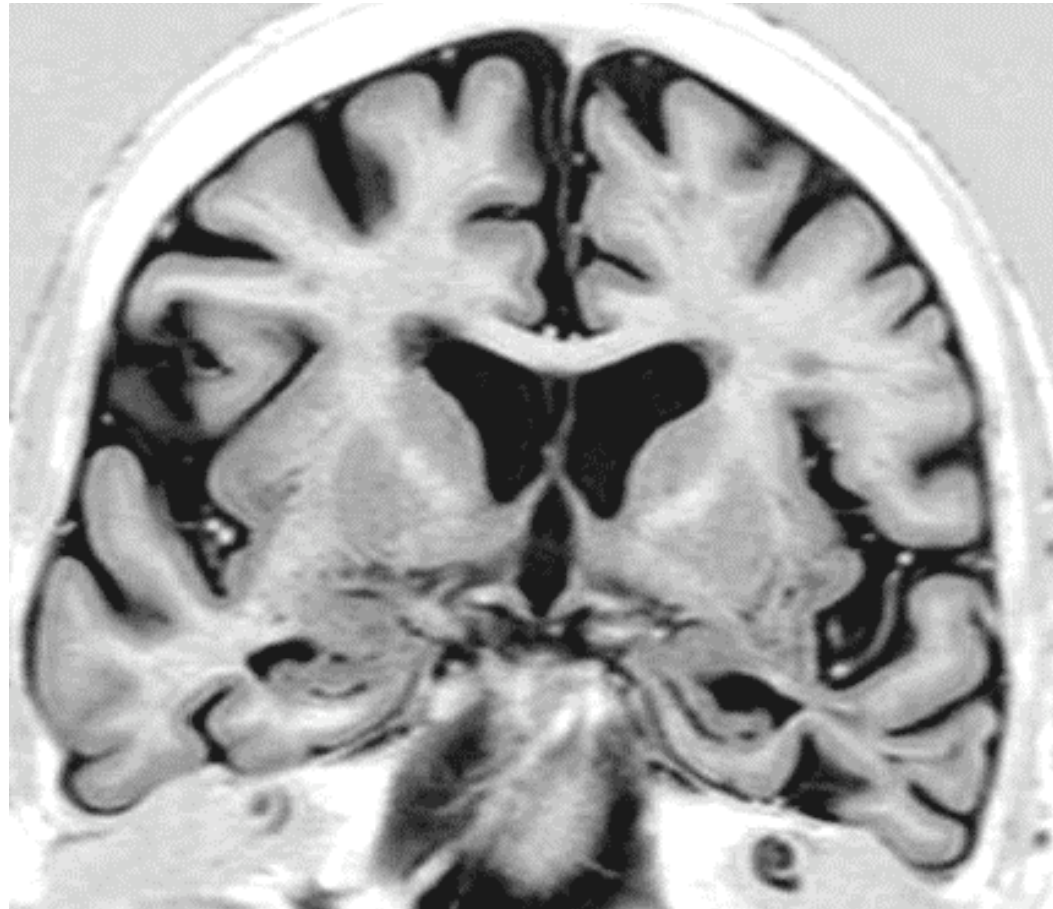
# Normal

---



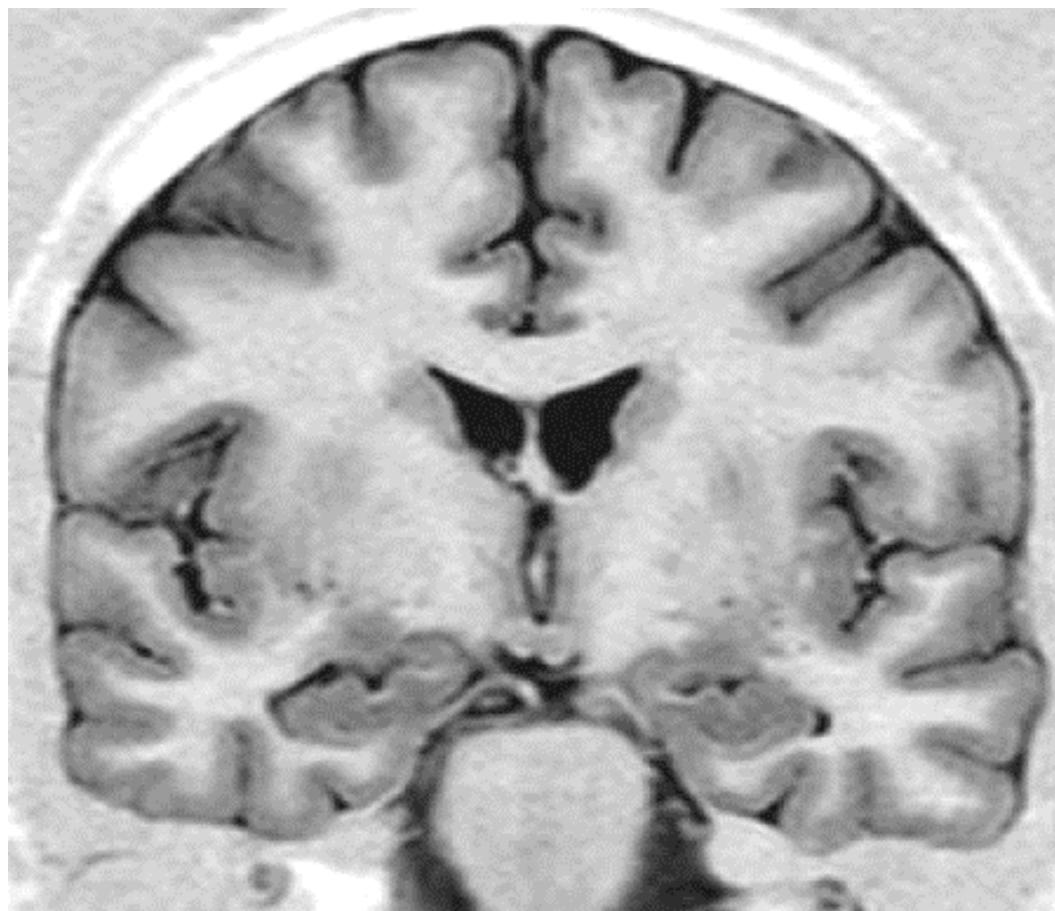
# MA

---



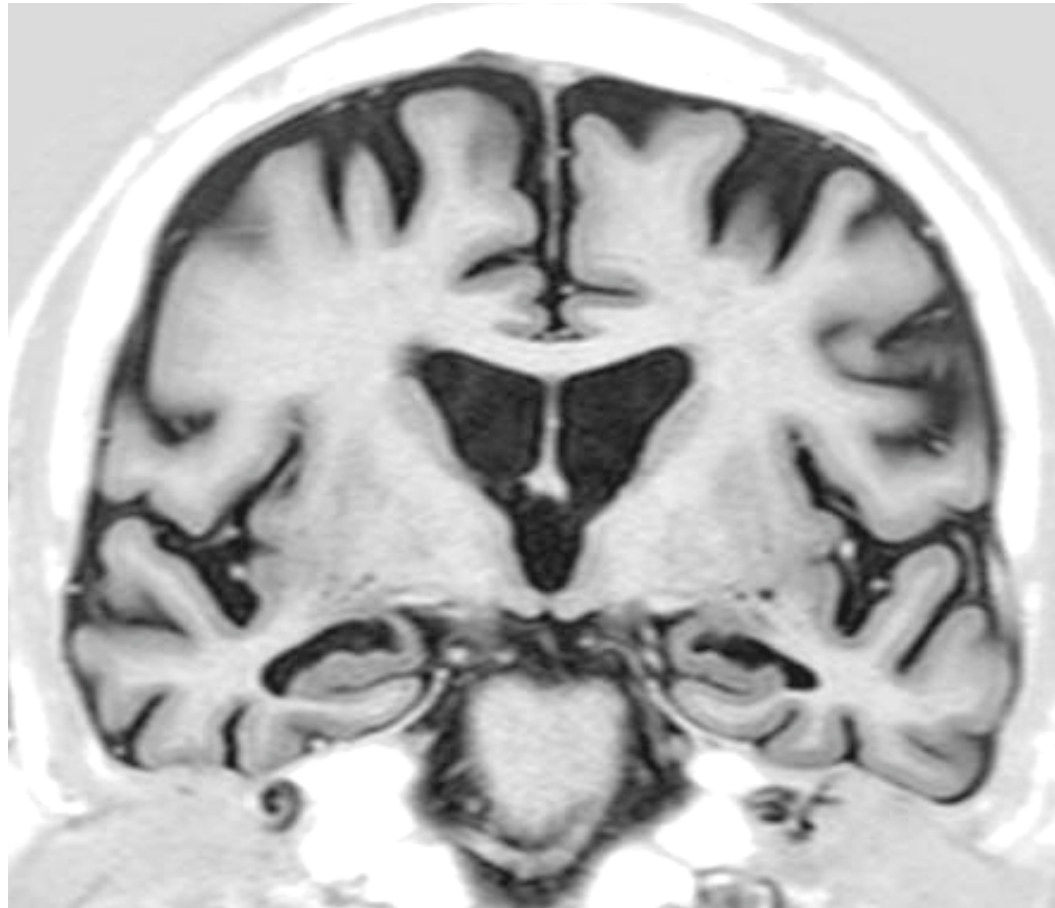
# Normal

---



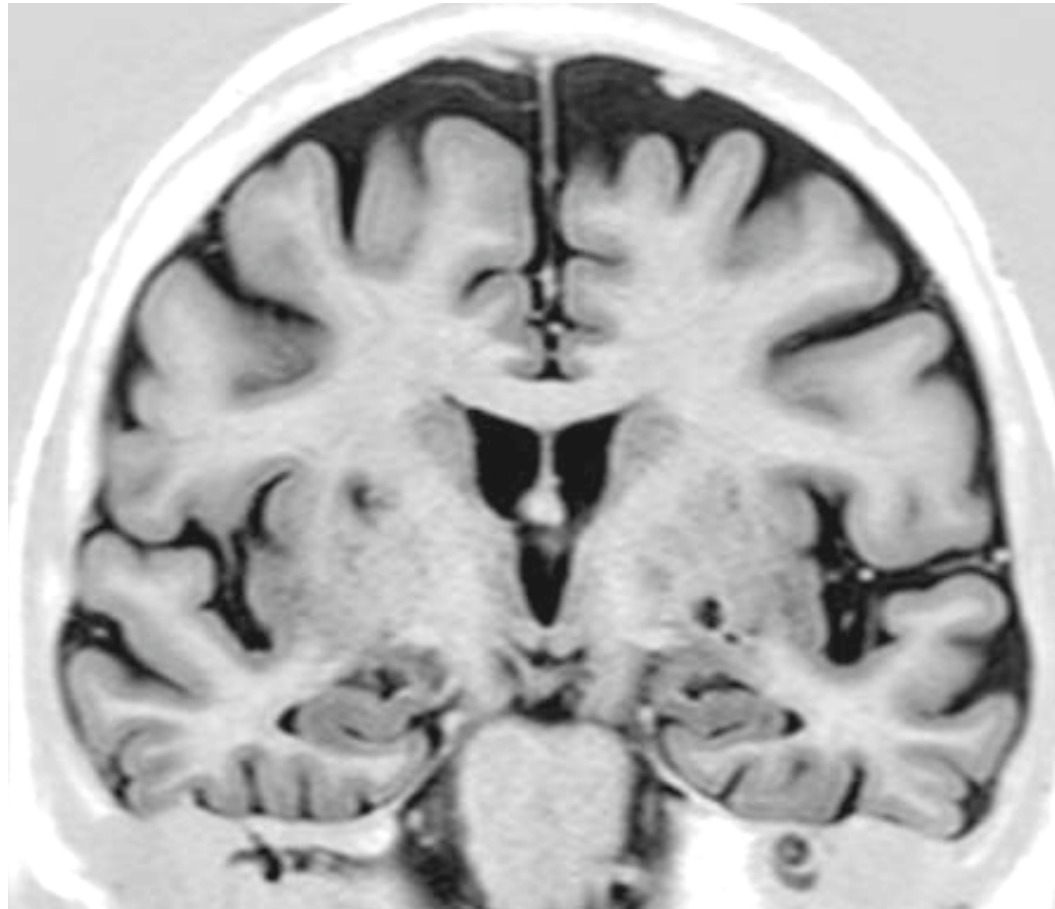
# MA

---



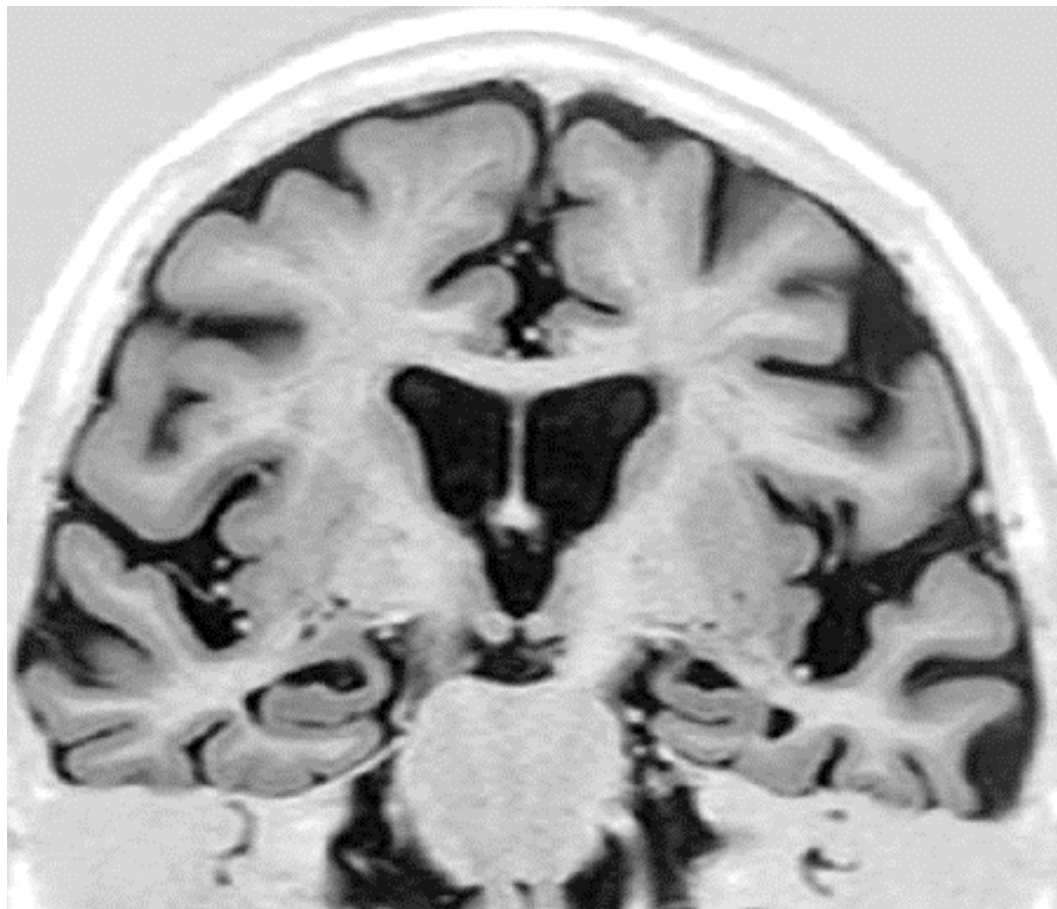
# TCL-a

---



# MA

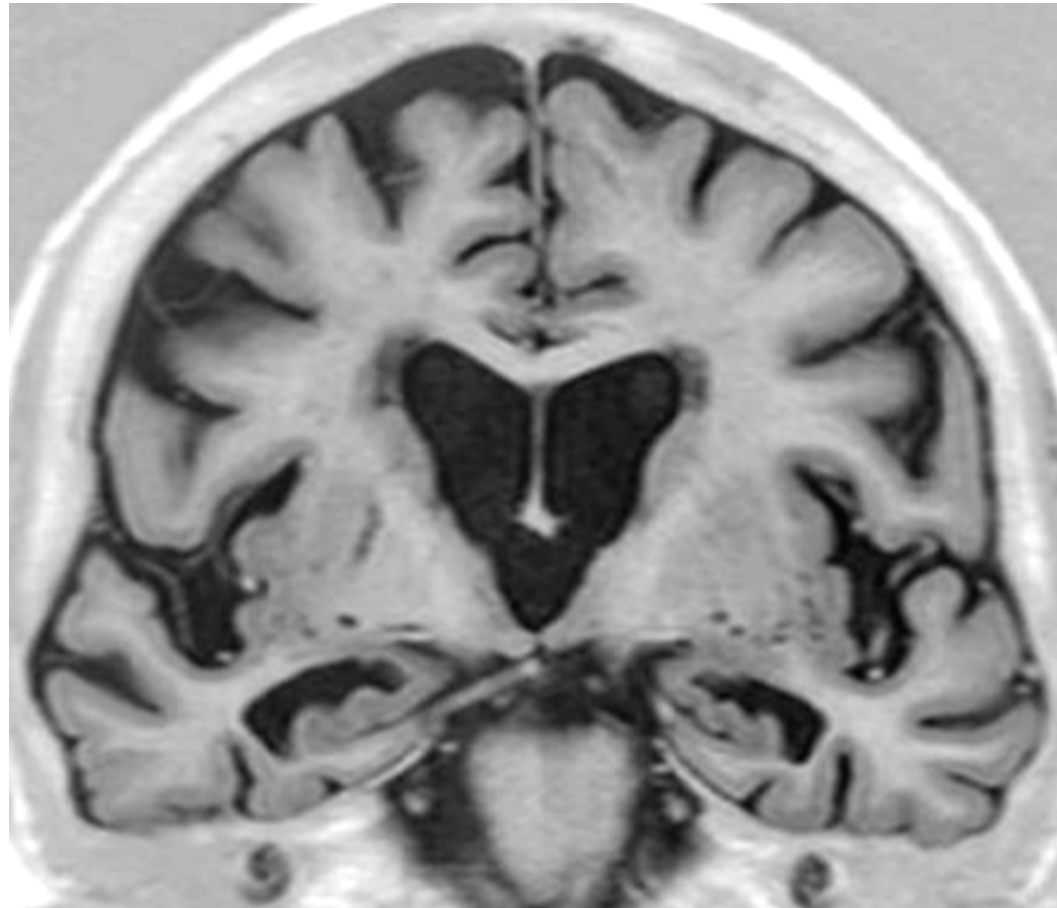
---



**L'atrophie de l'hippocampe est  
une anomalie sensible mais  
pas spécifique de la MA**

# MA

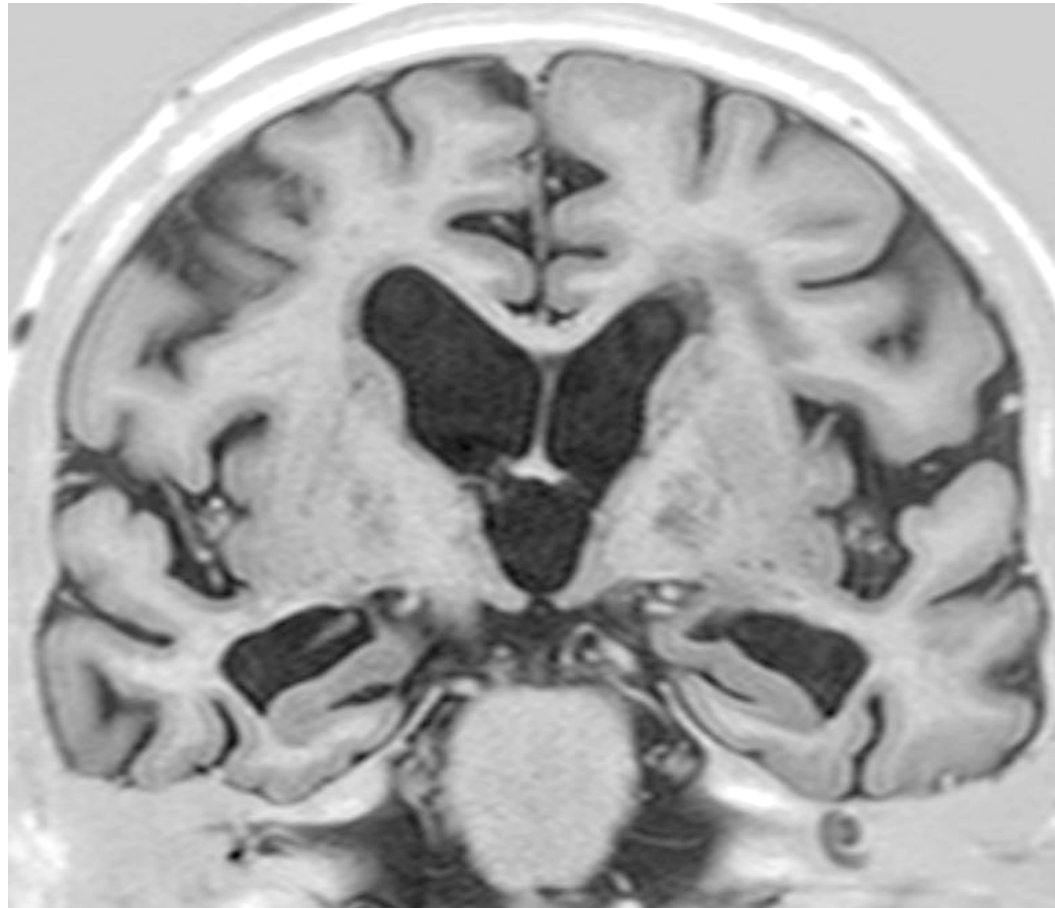
---





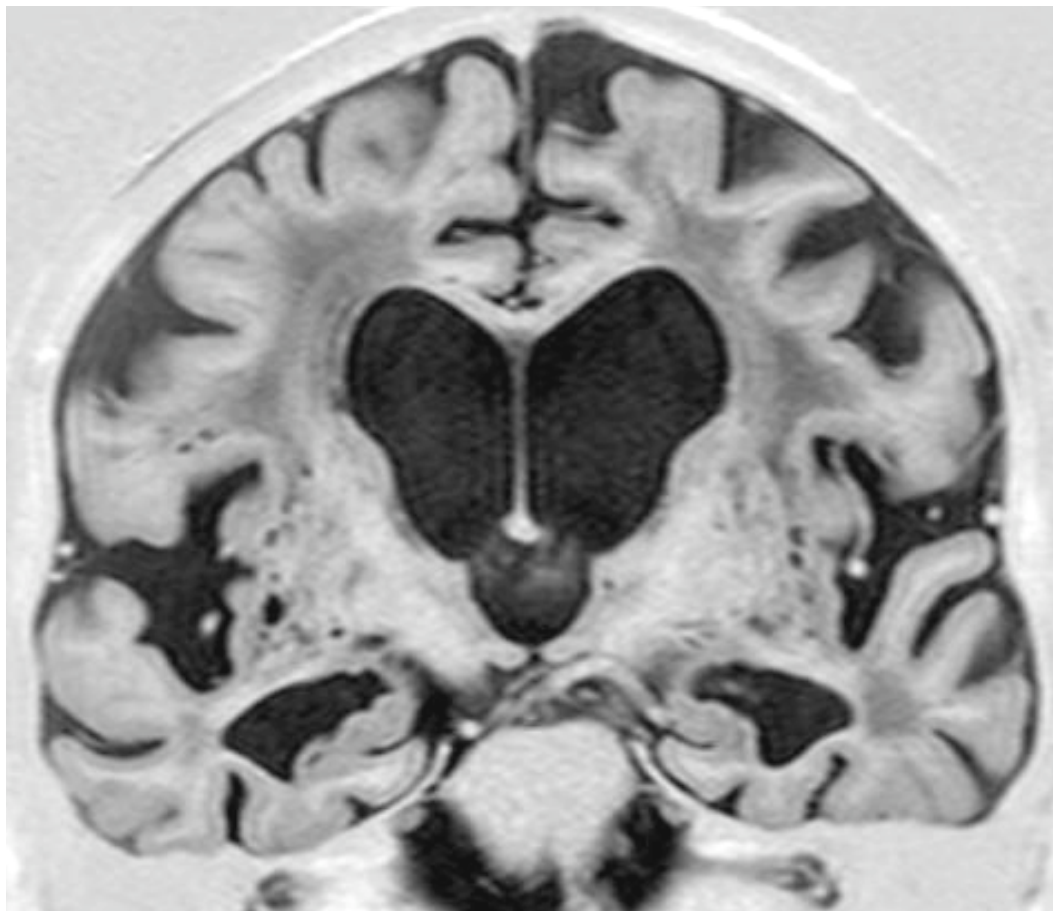
# DLFT

---



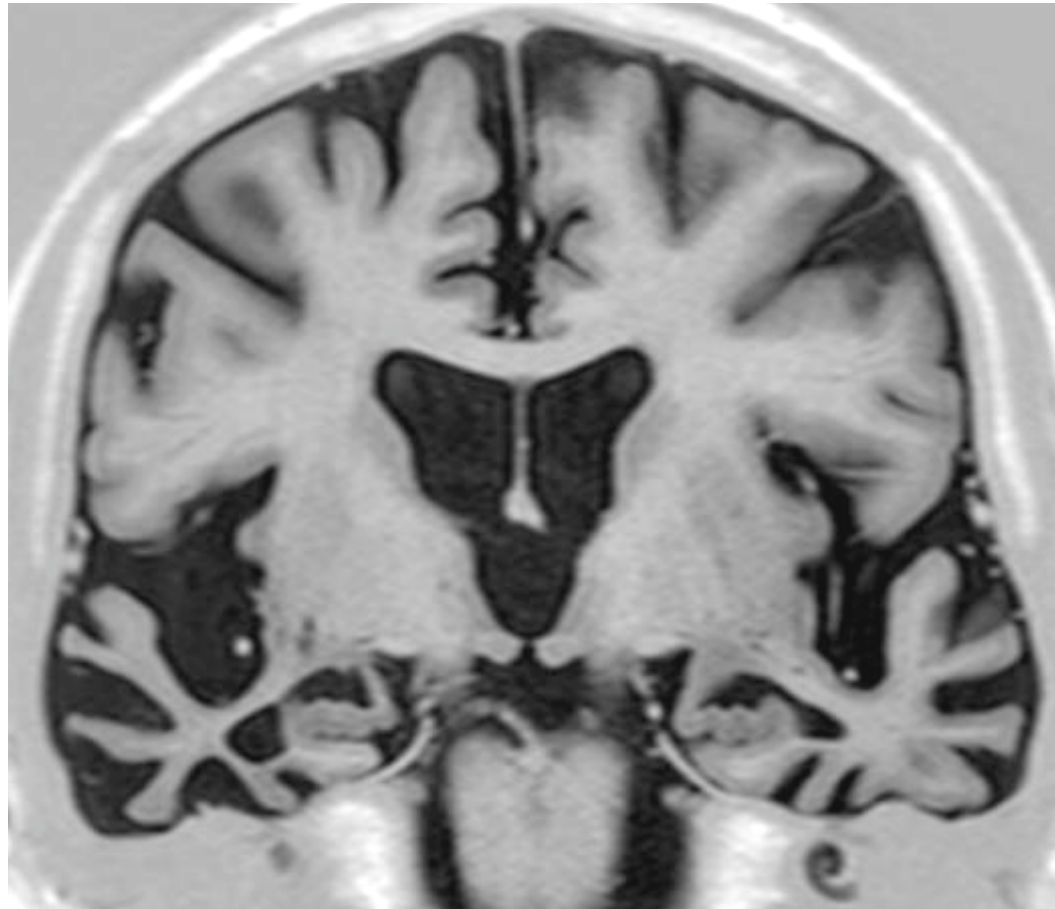
## D. Mixte

---



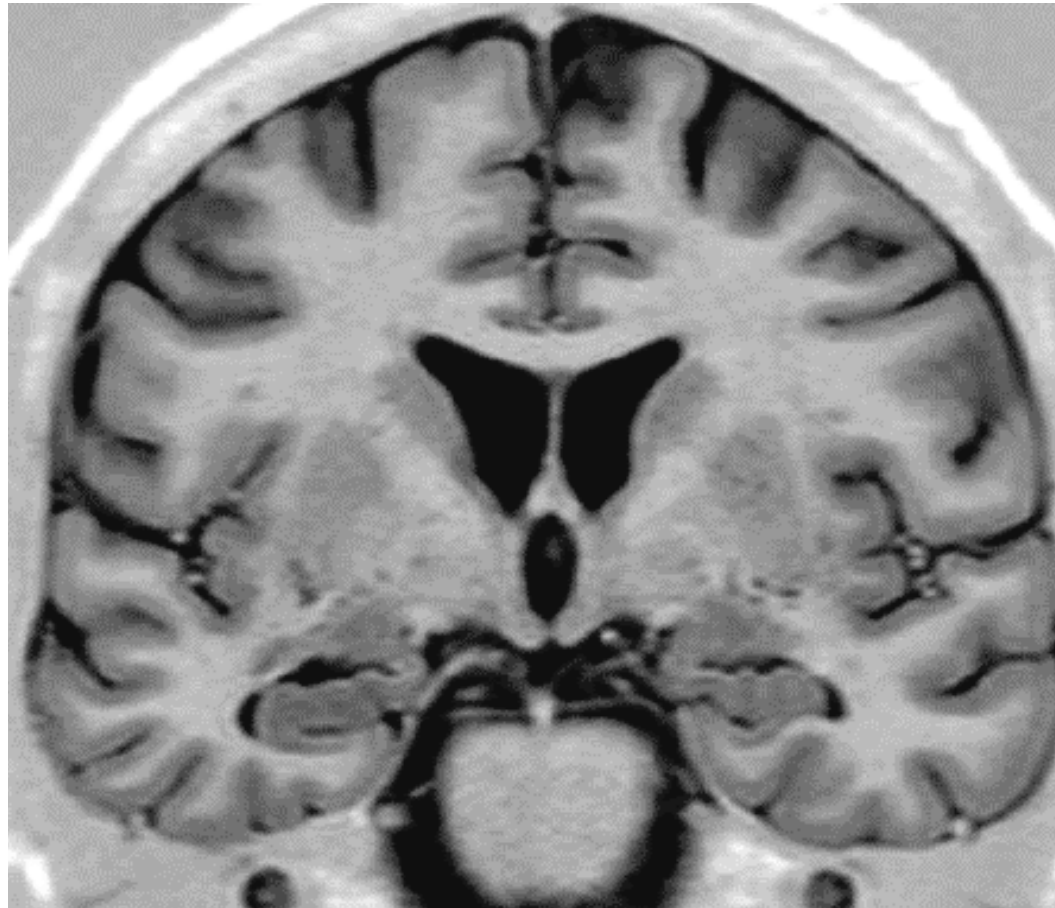
## D. Sémantique

---



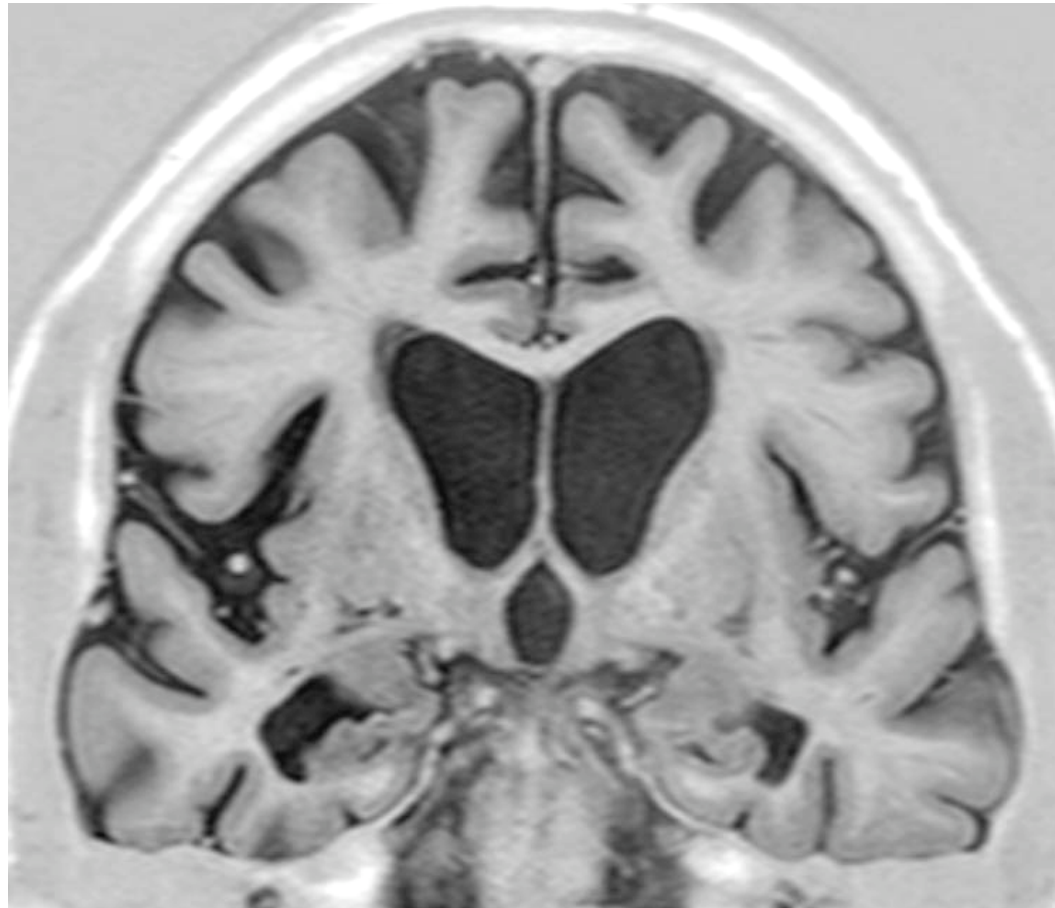
# MA

---



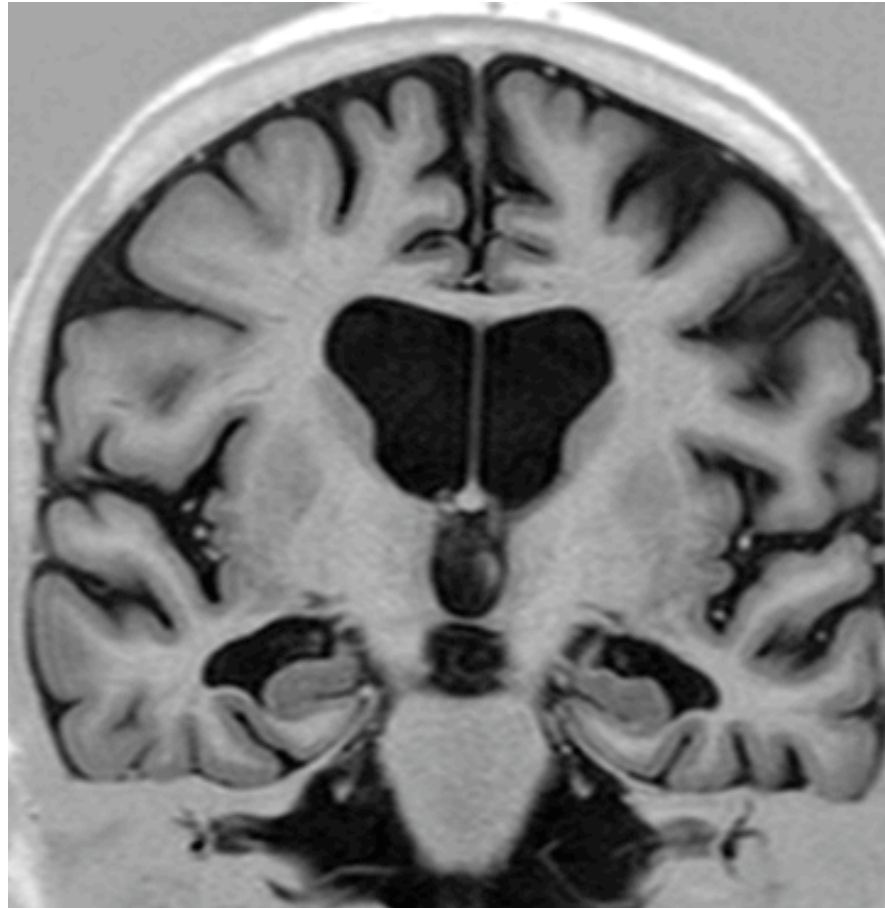
# DCL

---



# Alcool – Korsakoff

---

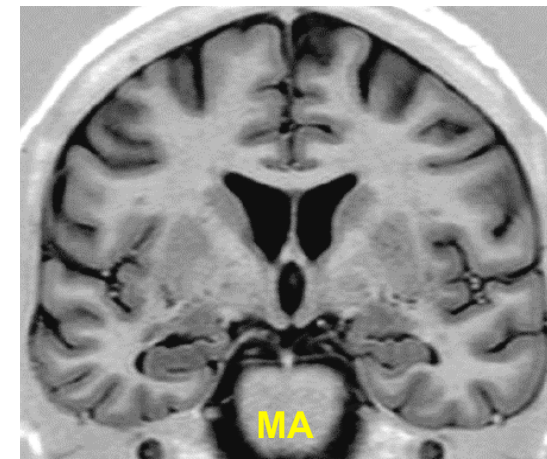
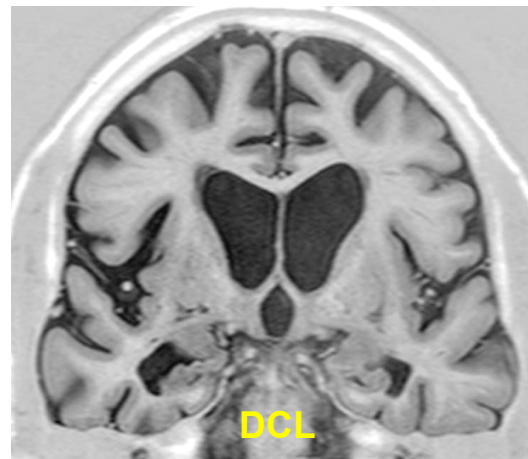
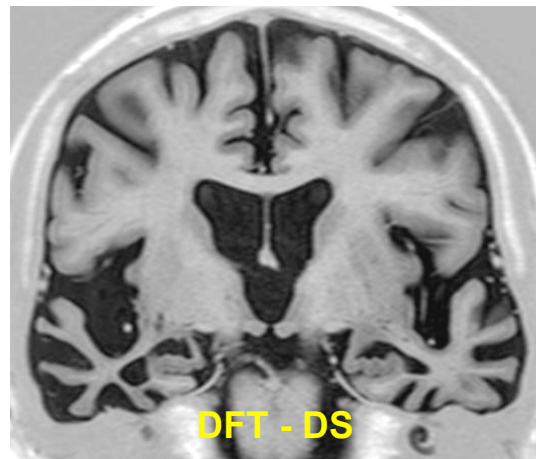
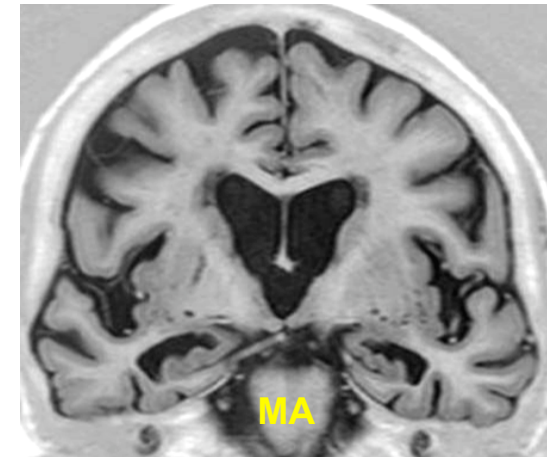
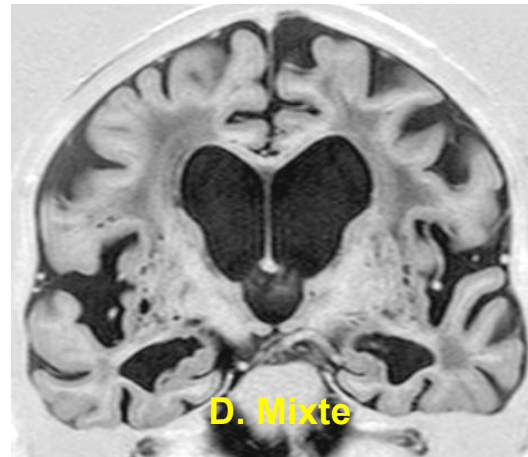
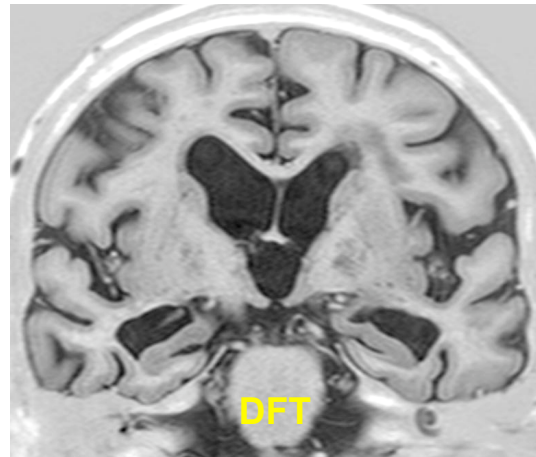


# Morphométrie cérébrale

---

L'atrophie de l'hippocampe n'est pas spécifique de la MA

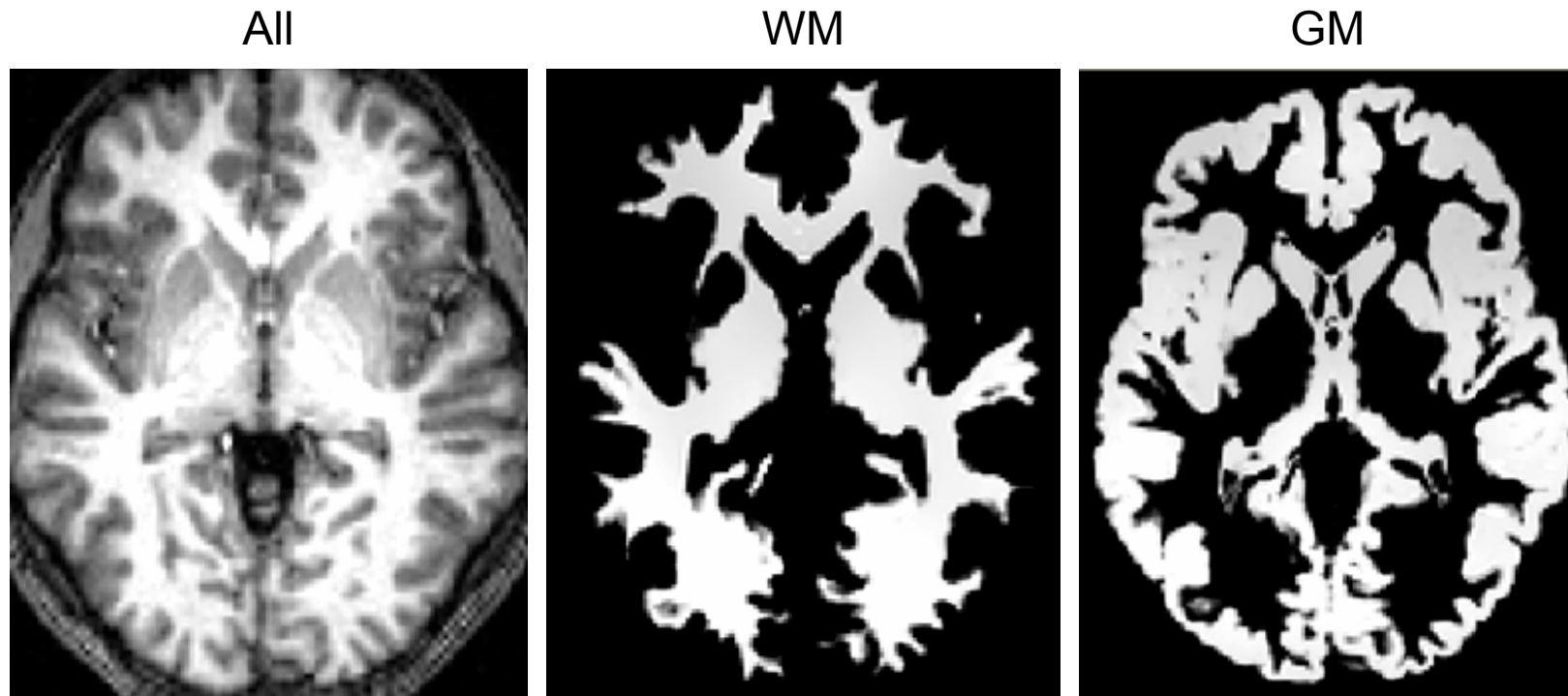
EC – IRM → valeurs prédictives ?



# Morphométrie cérébrale

---

- Subjective → ROI manuelles → Semi-automatique → Automatique (VBM)



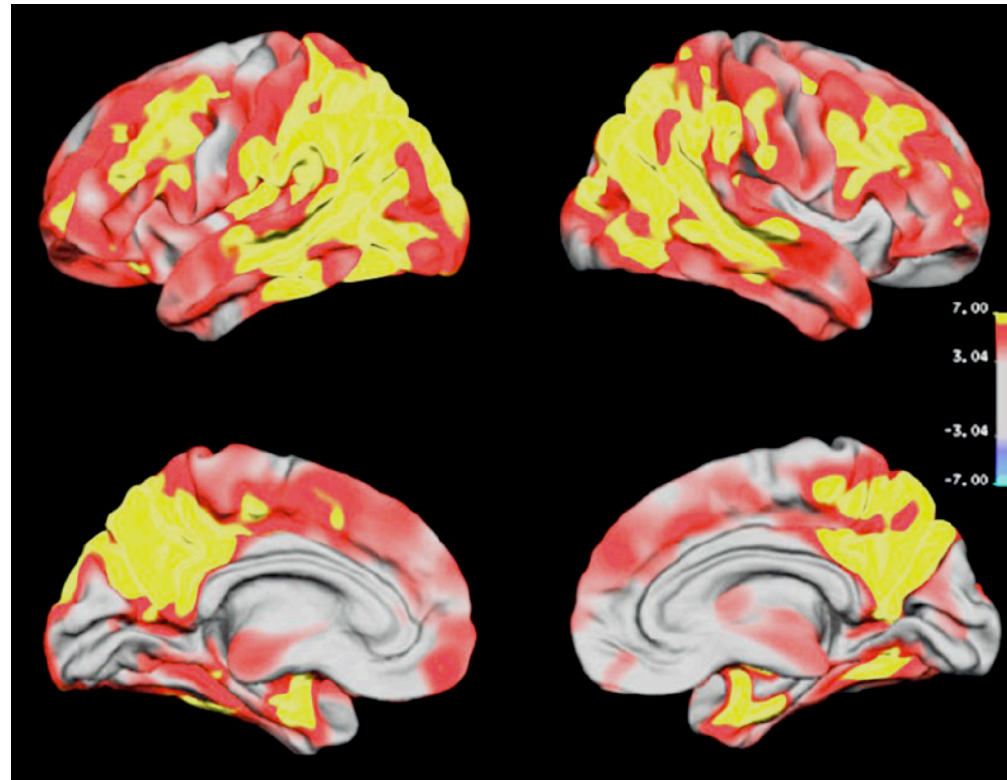


# Morphométrie cérébrale

---

- Subjective → ROI manuelles → Semi-automatique → Automatique (VBM)

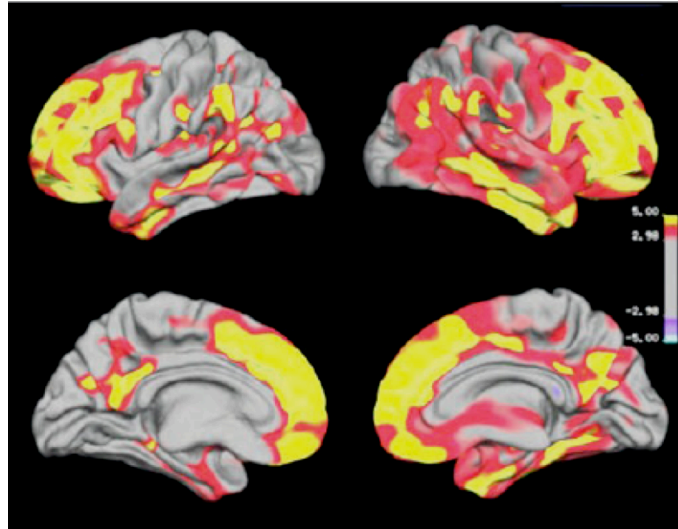
ALZ  
vs  
Sains



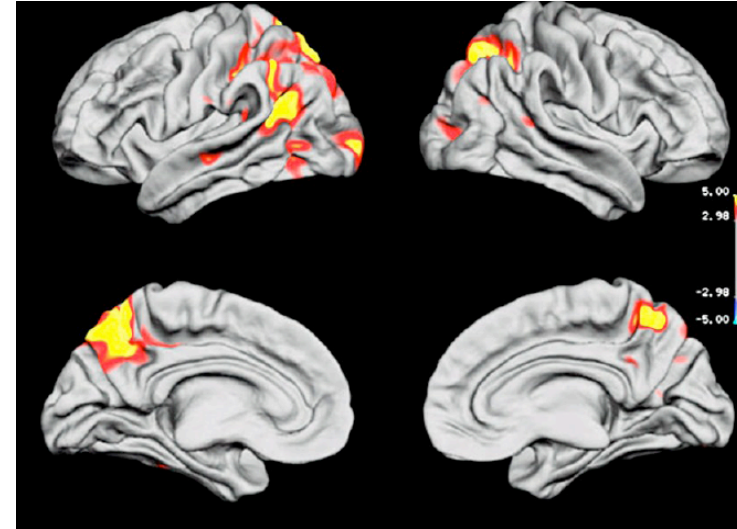
Du, *Brain* 2007

# Morphométrie cérébrale

DFT vs Normal

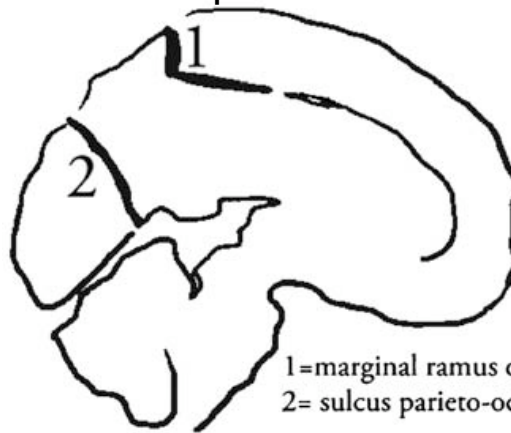
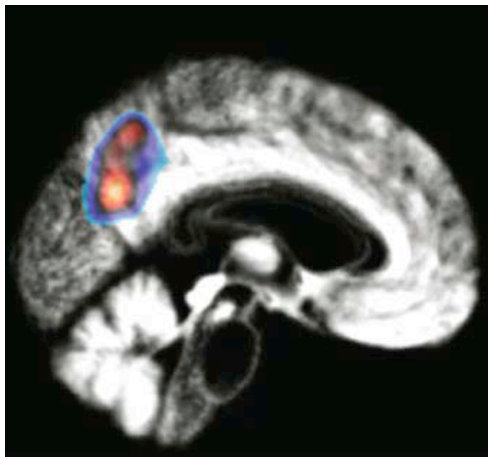


ALZ vs DFT

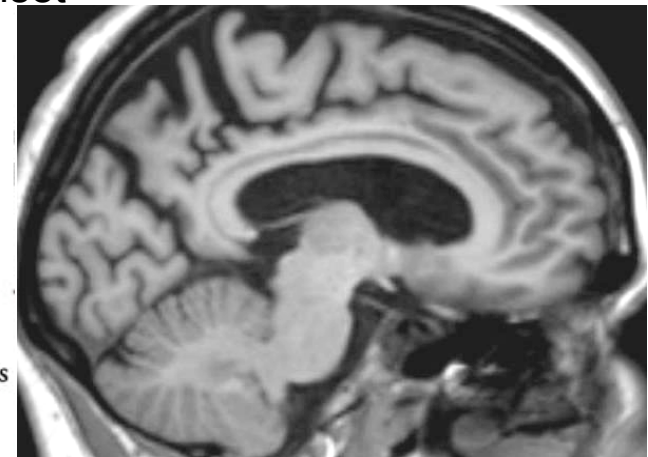


*Du Brain 2007*

ALZ : Atrophie inversement liée à l'onset



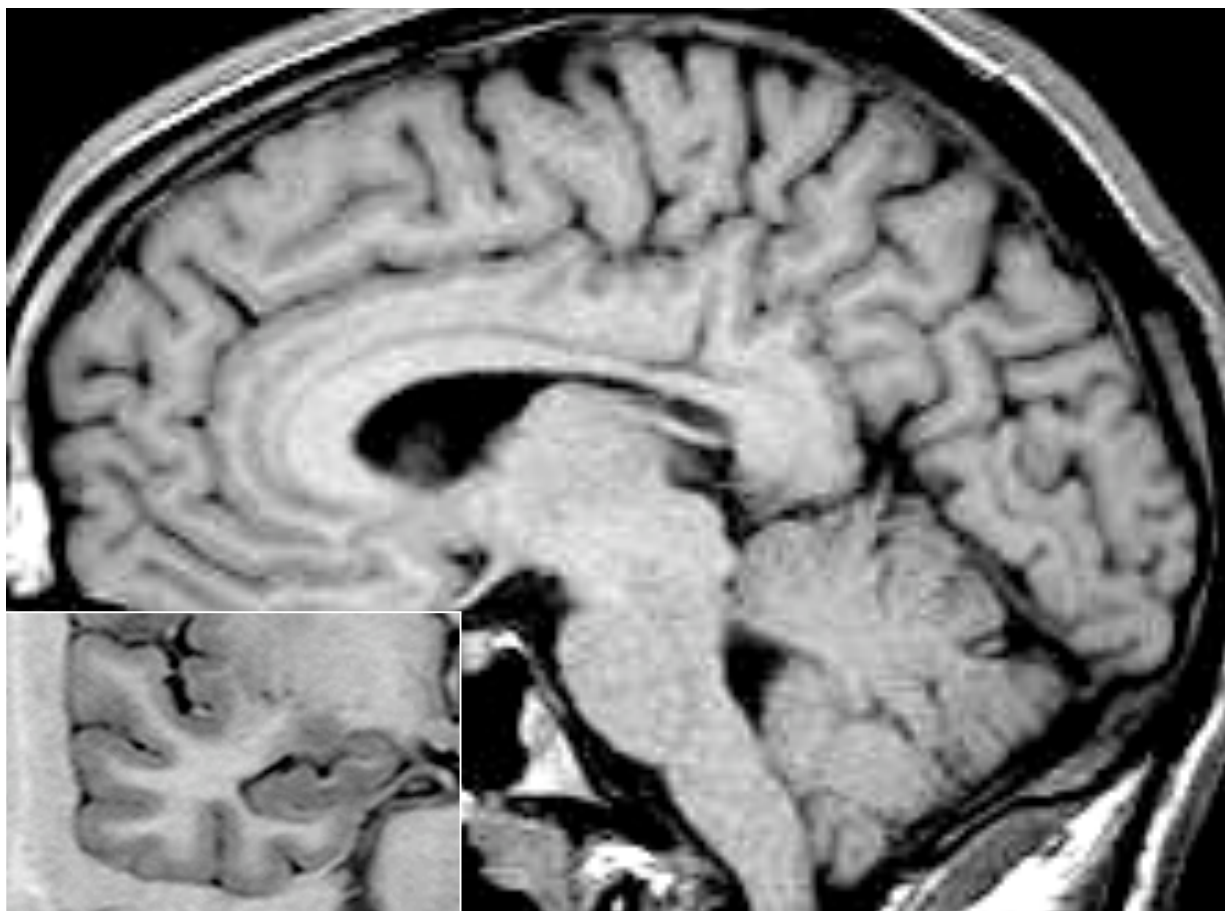
1=marginal ramus of sulcus cingularis  
2= sulcus parieto-occipitalis



*Kakas Neuroradiology 2007*

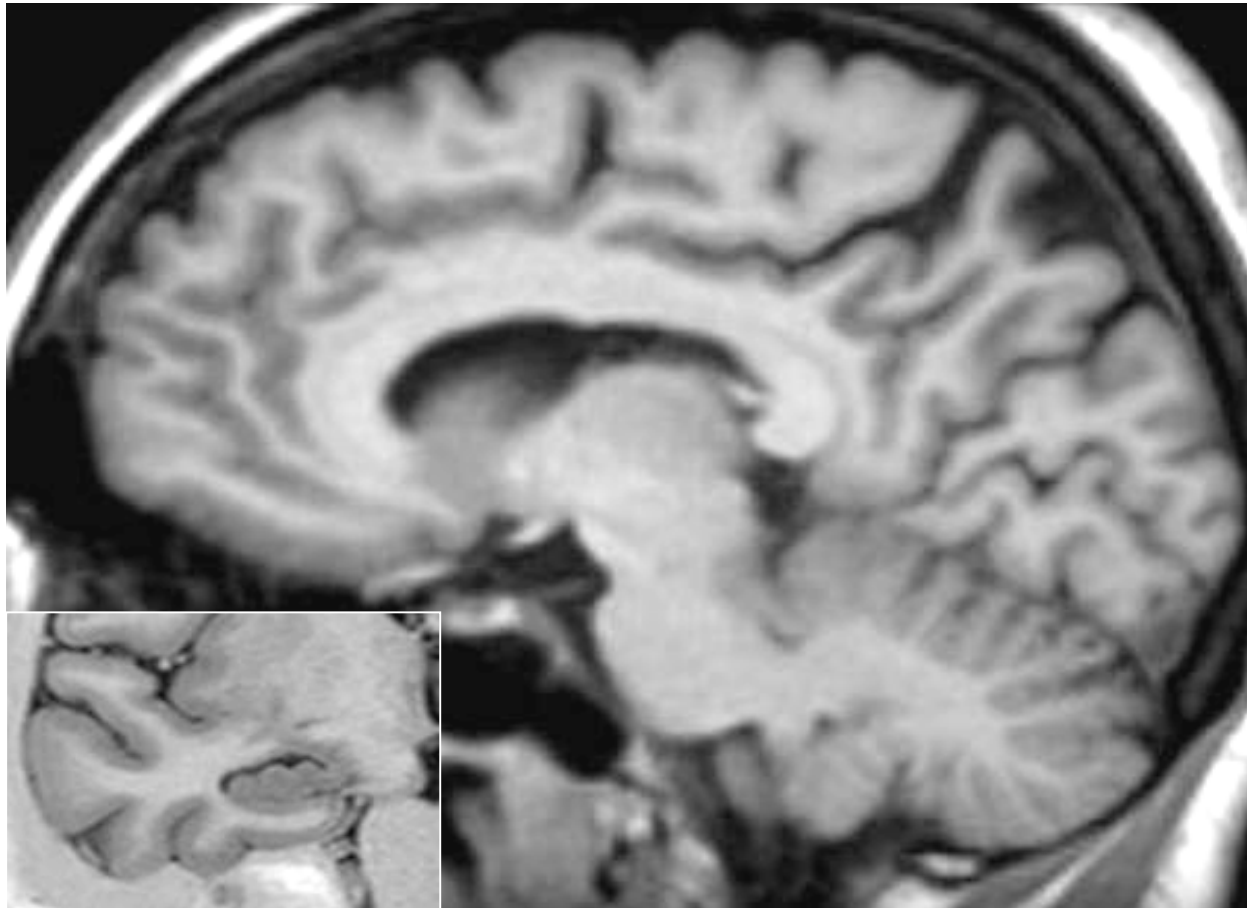
# Normal

---



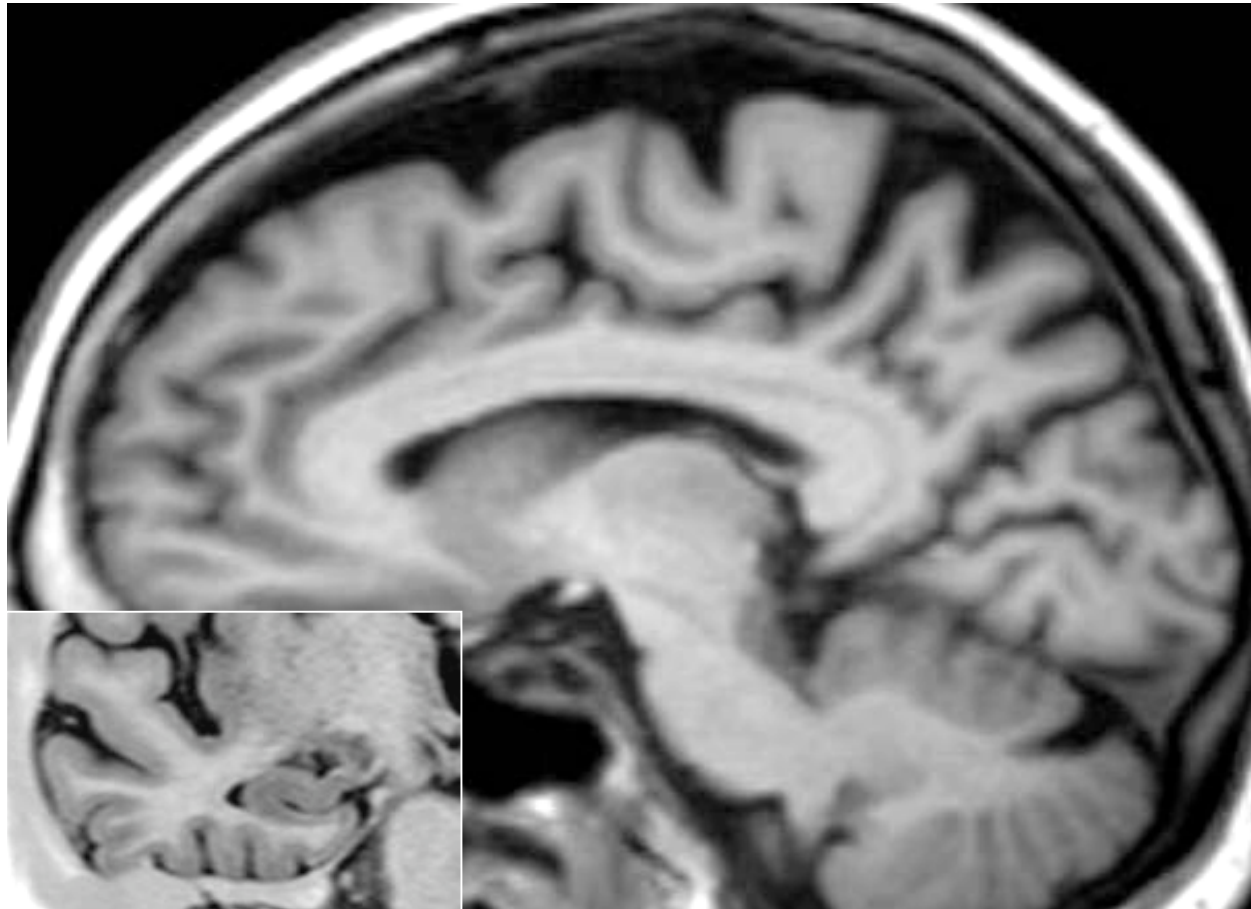
# TCL-a

---



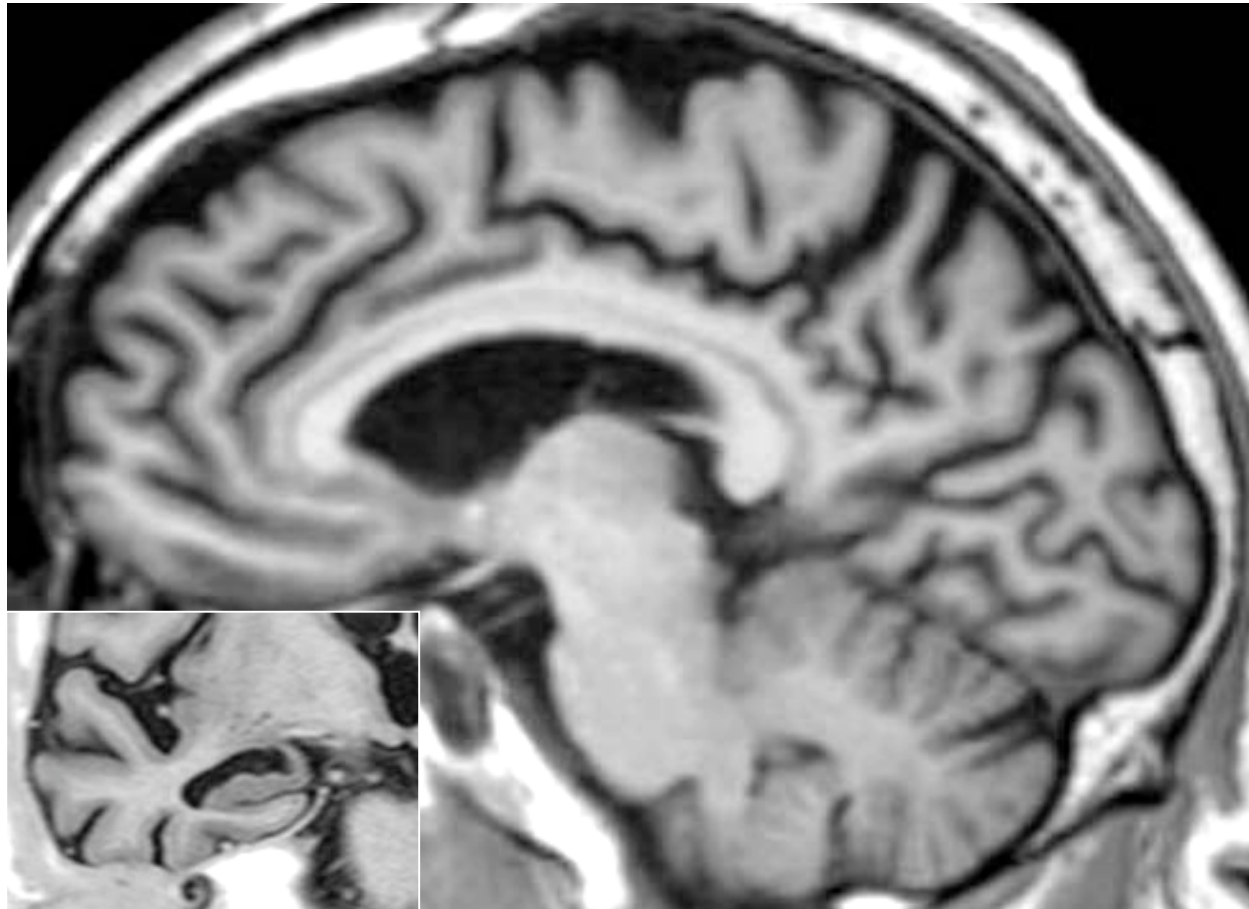
# MA

---



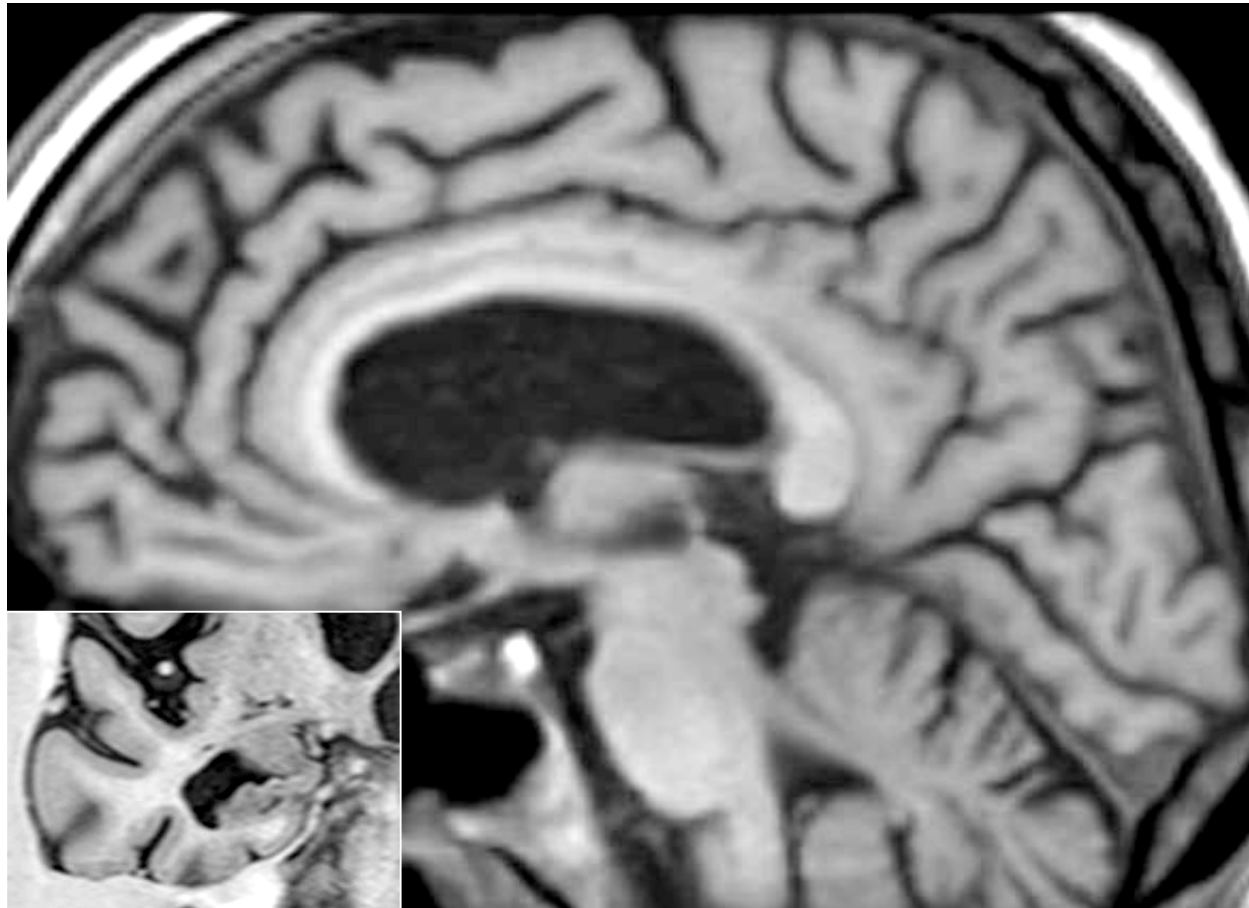
# MA

---



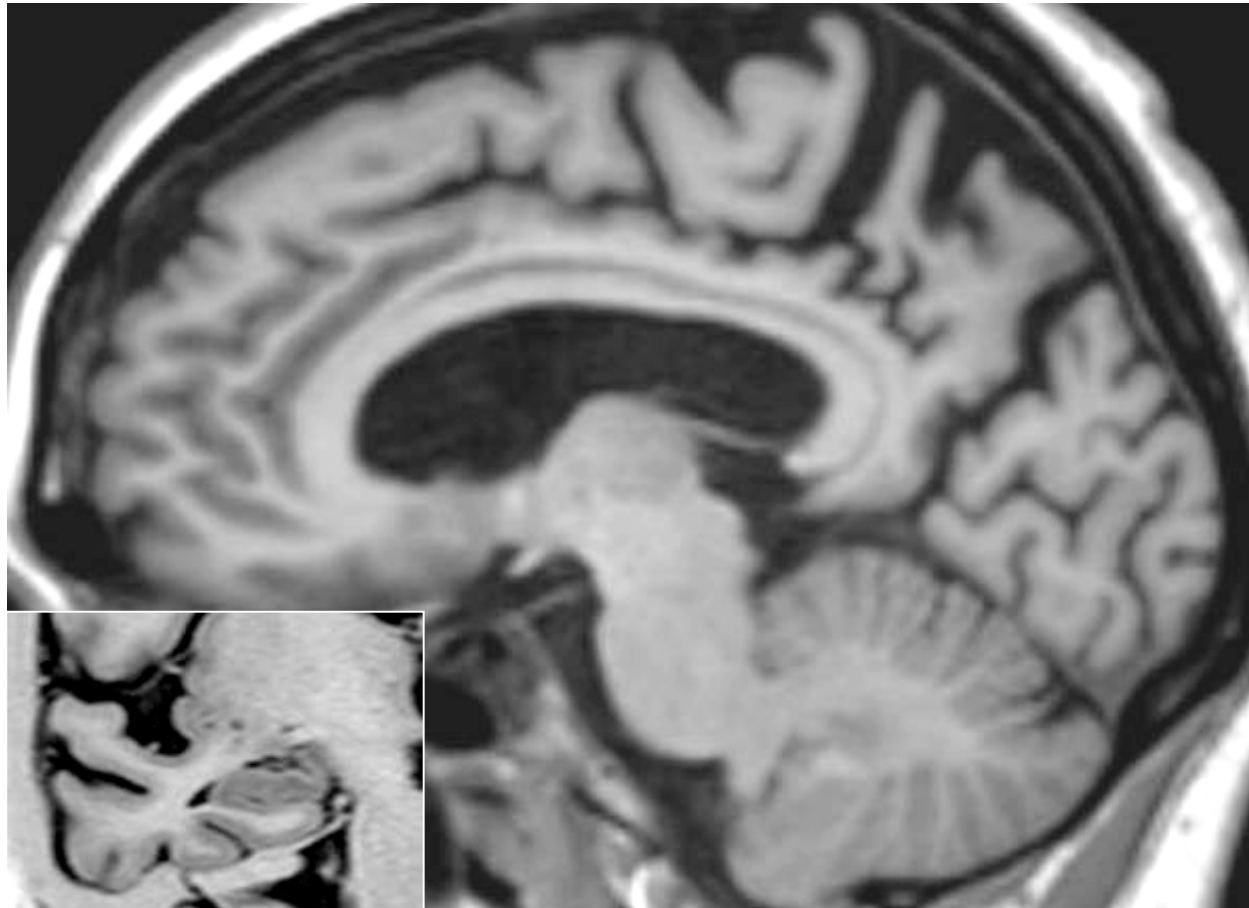
# DLFT

---



# MA

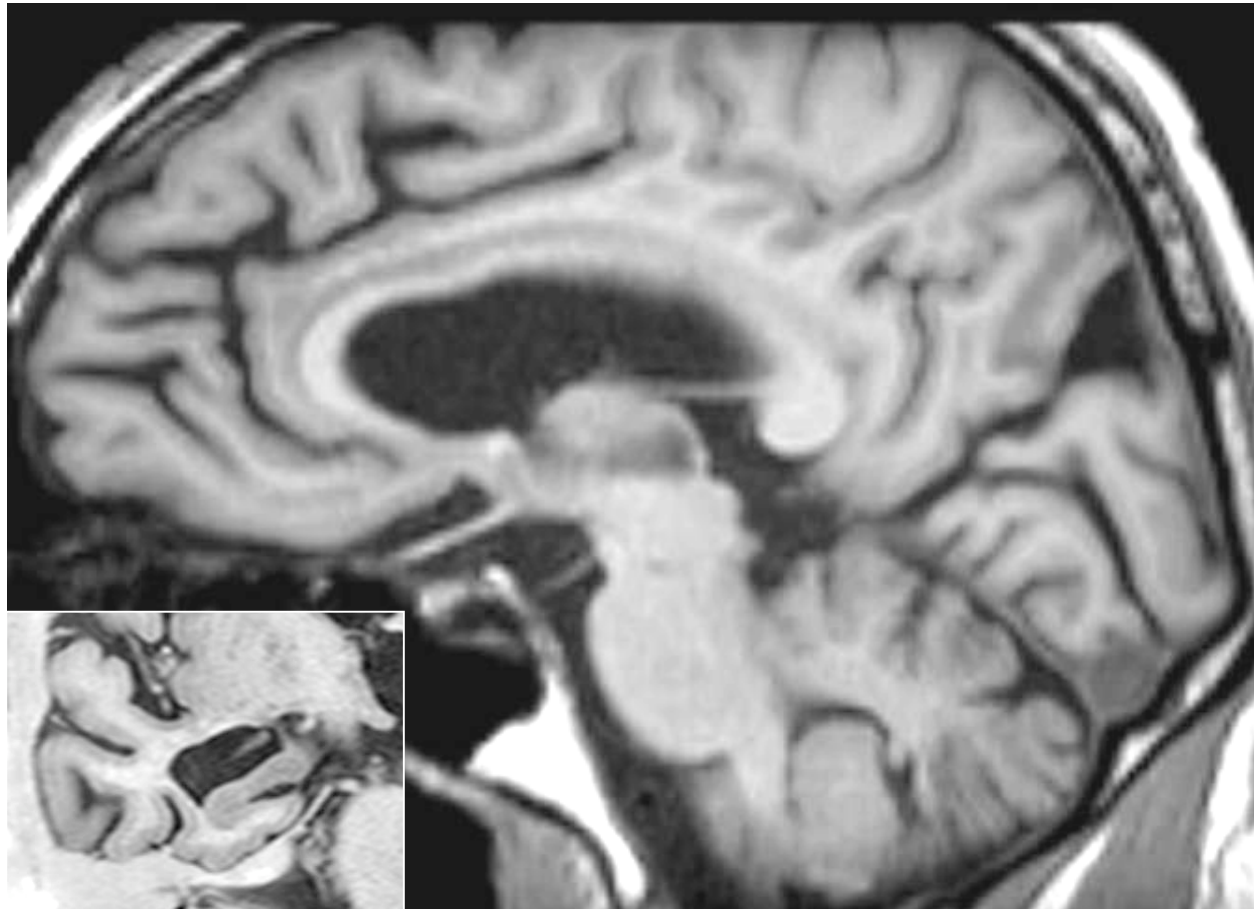
---





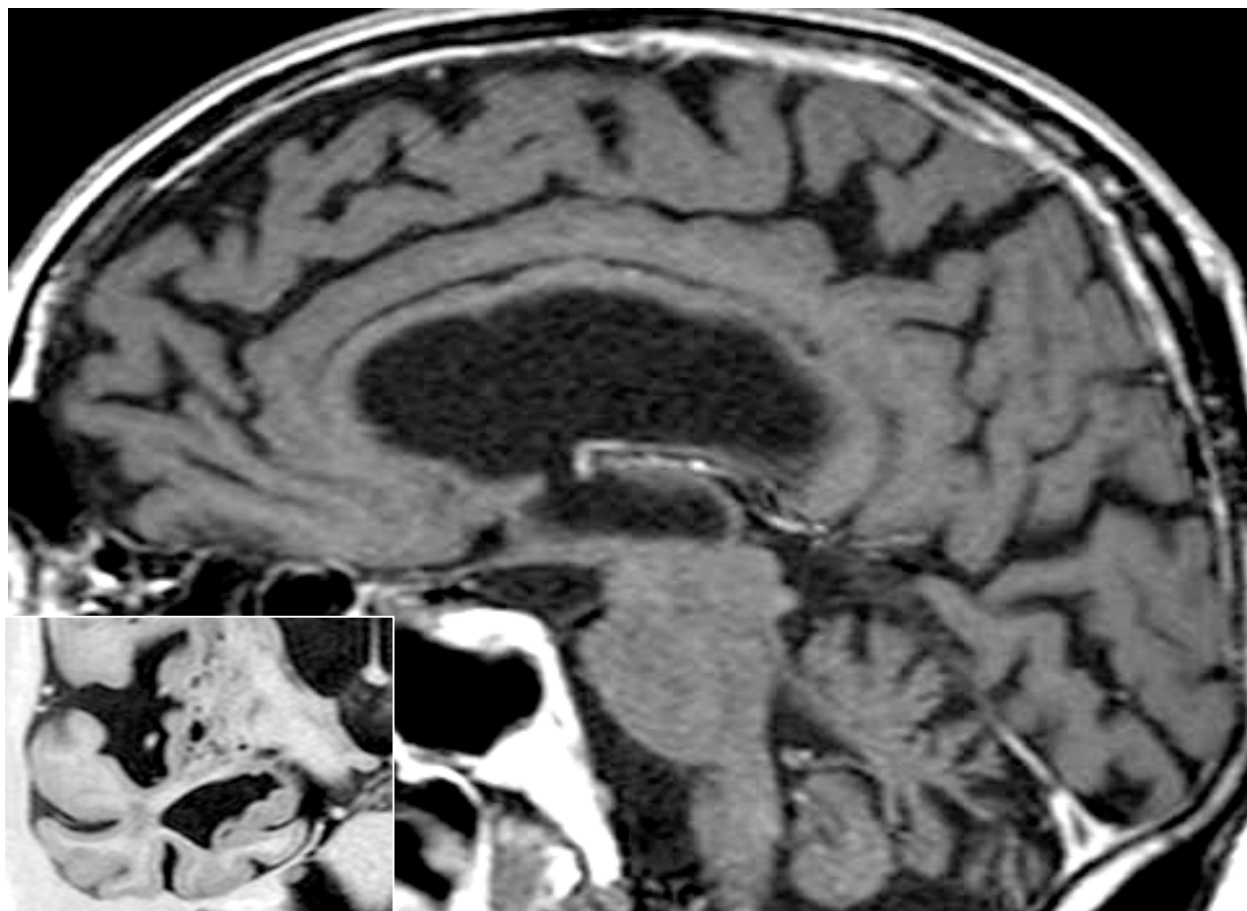
# DLFT

---



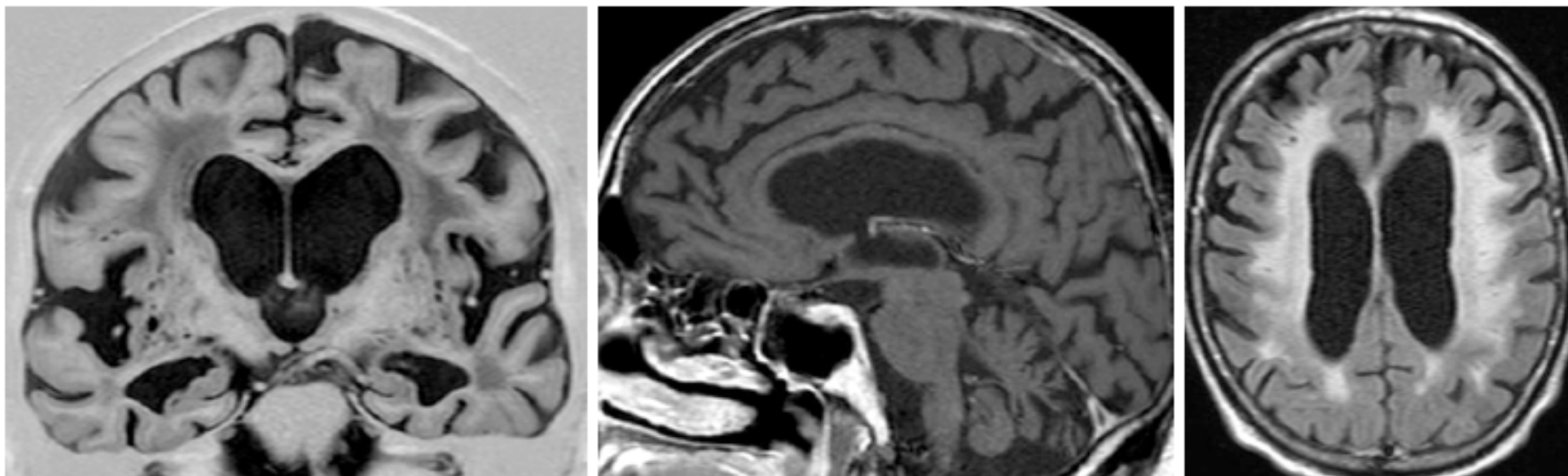
# D. mixte

---



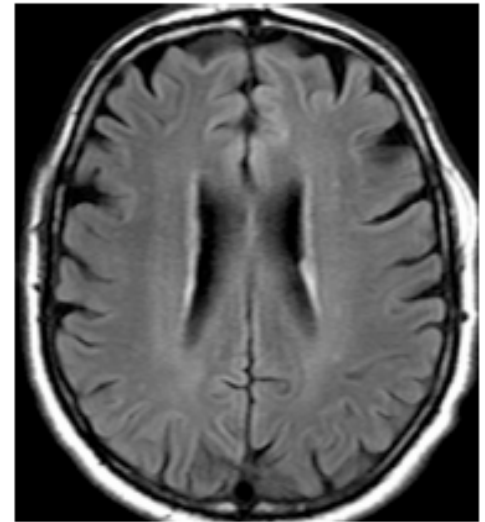
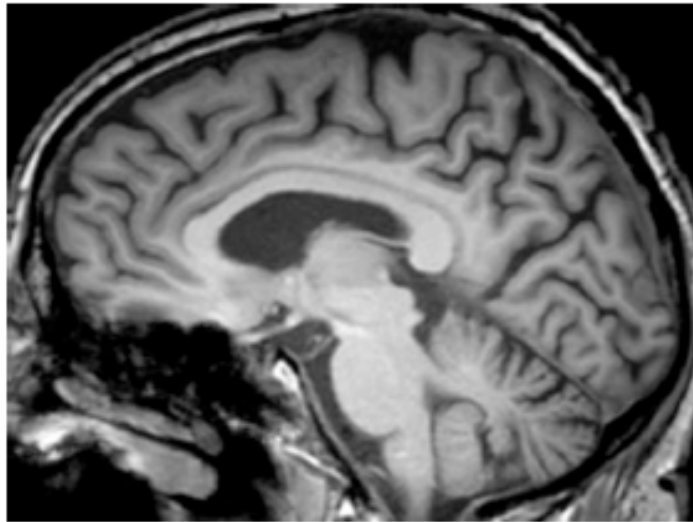
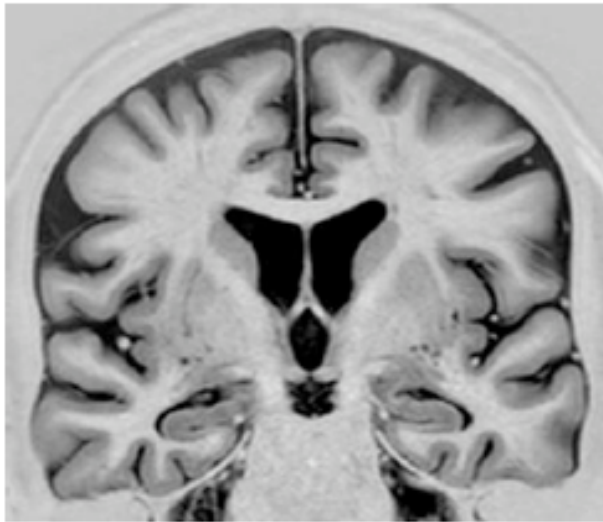
# D. mixte

---



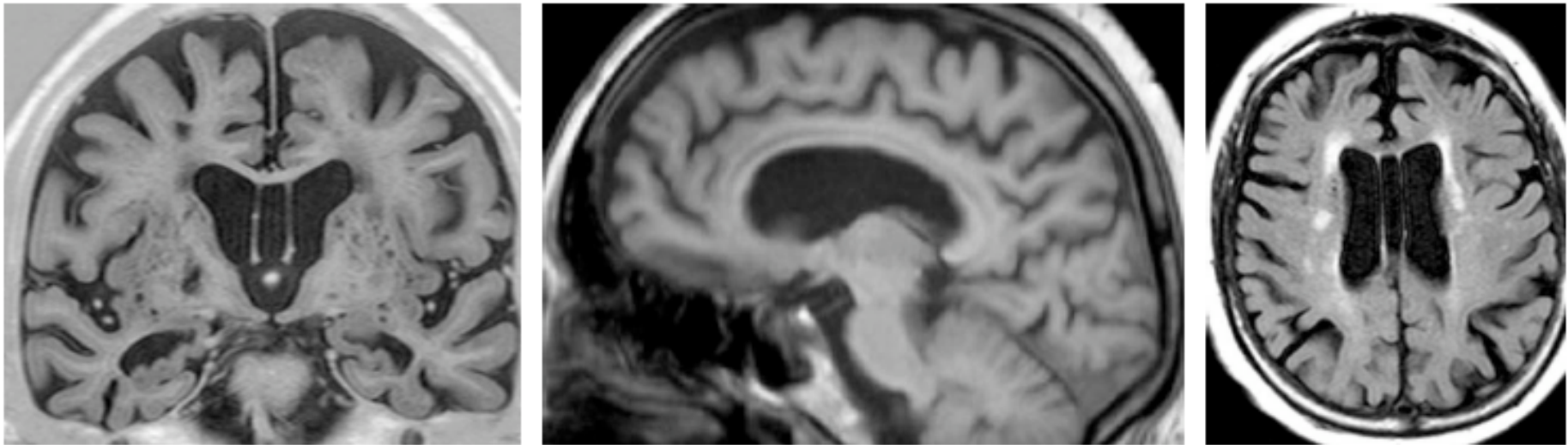
# MA

---



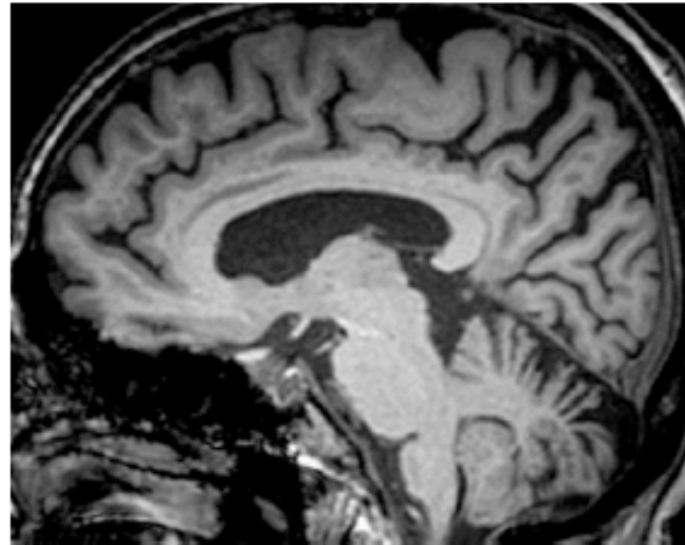
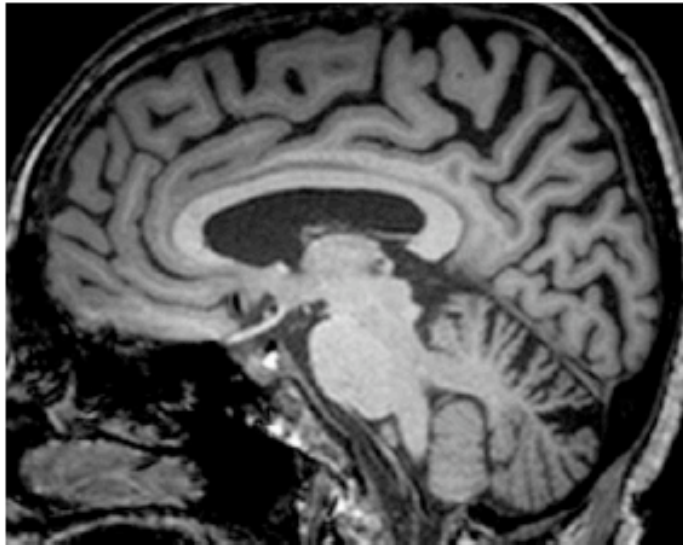
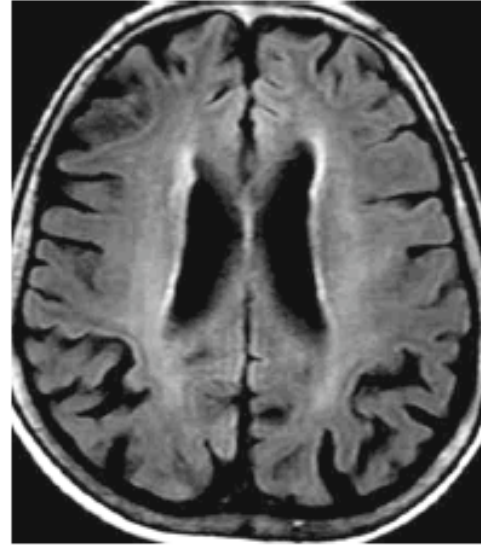
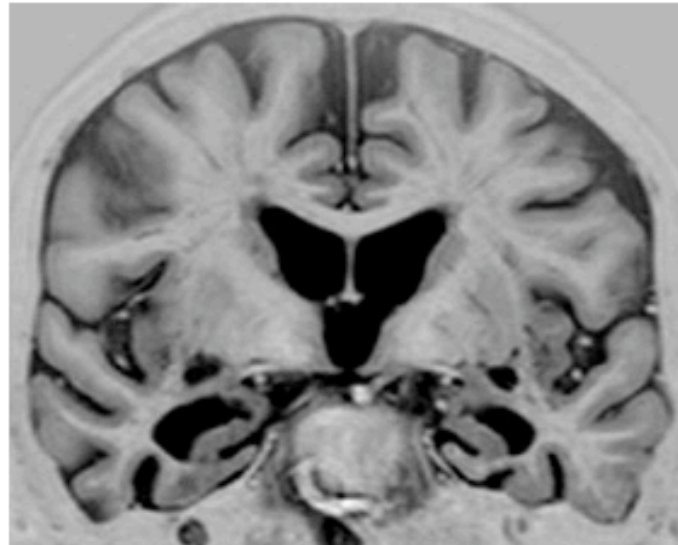
# D. mixte

---



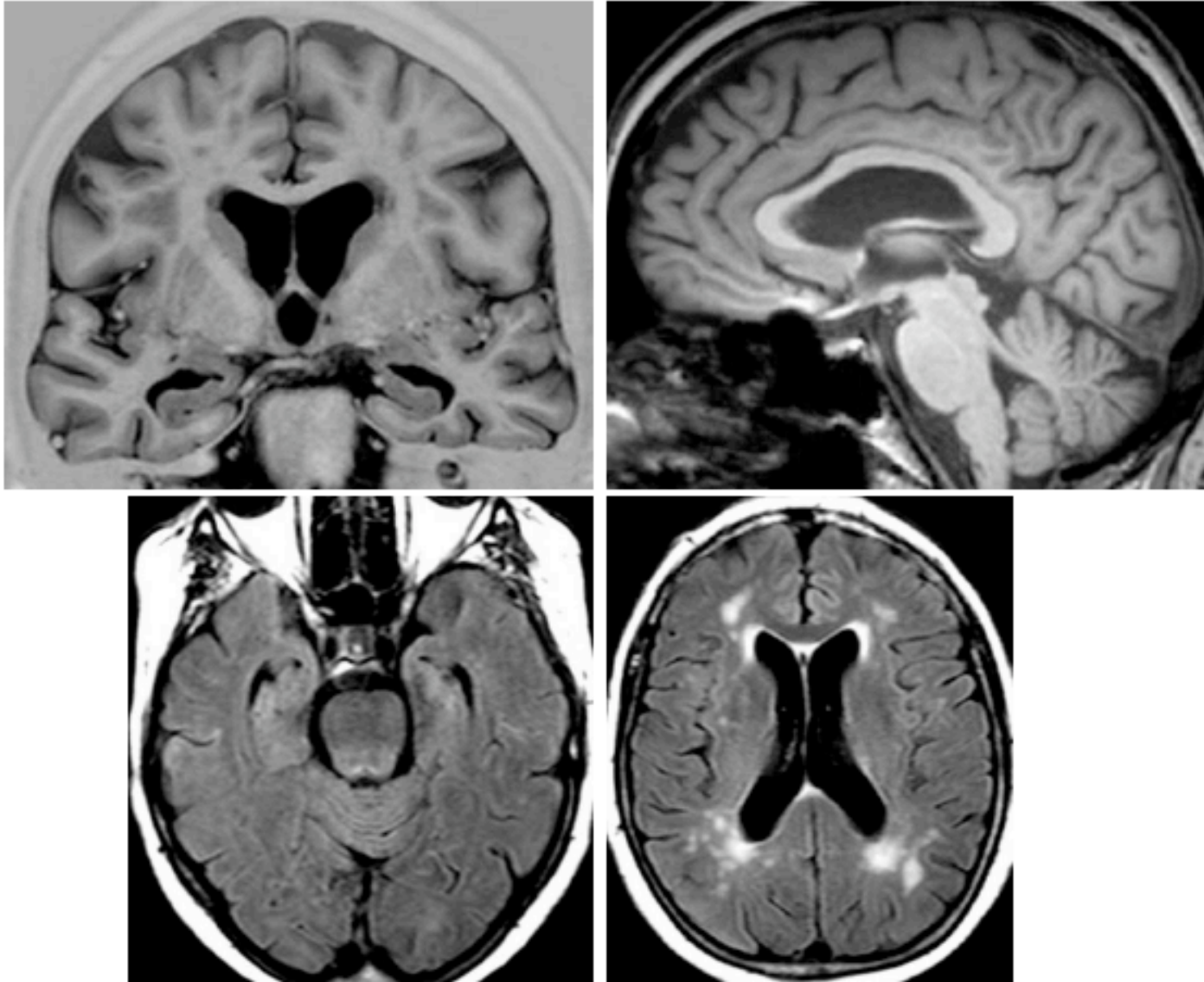
# MA

---



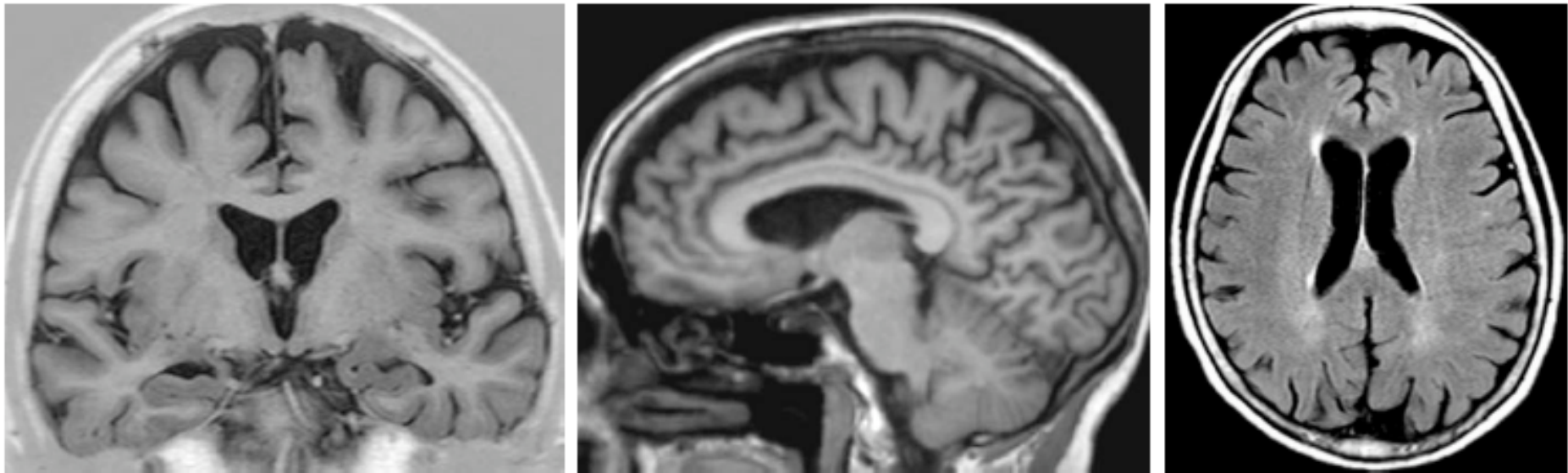
# D. mixte

---



# TCL-a

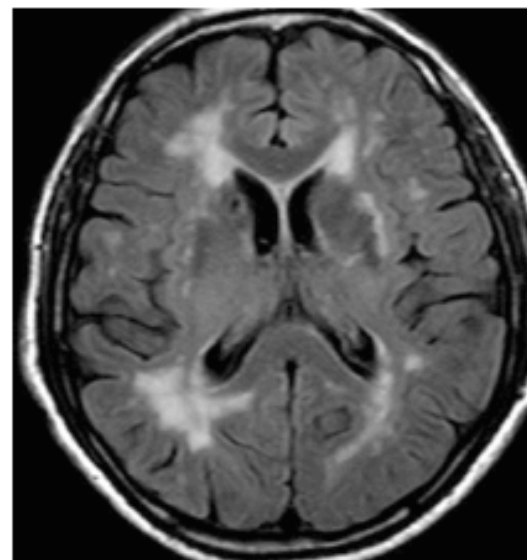
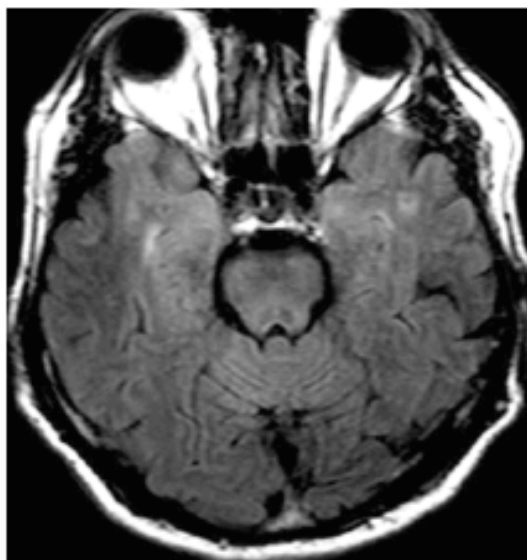
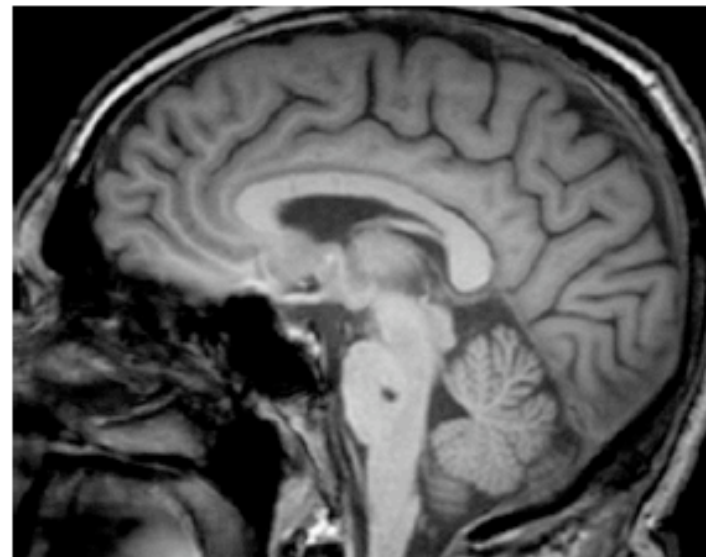
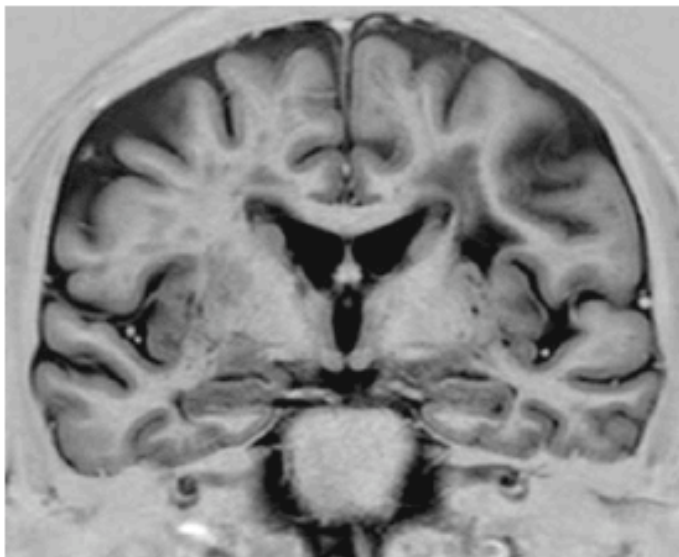
---





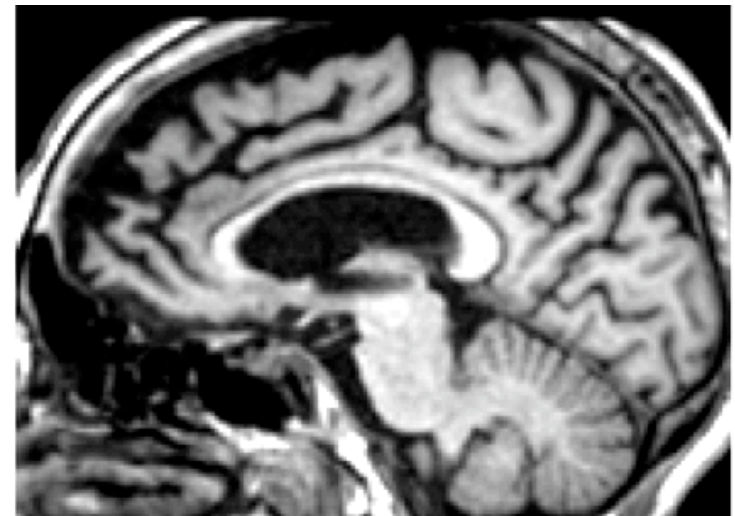
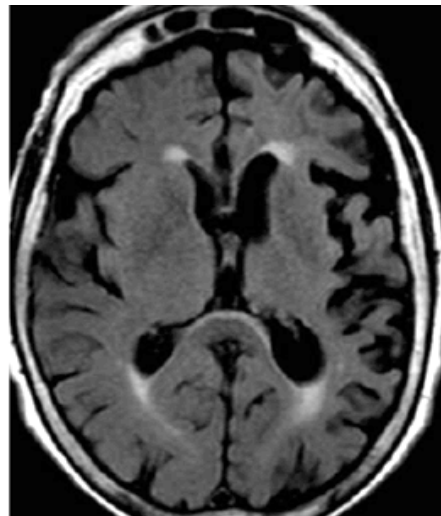
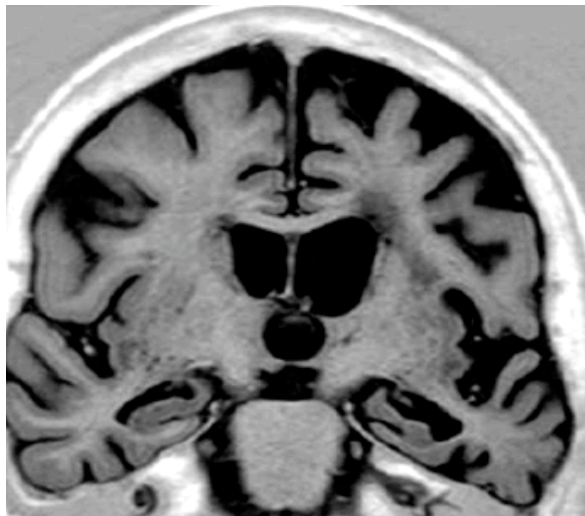
# CADASIL

---



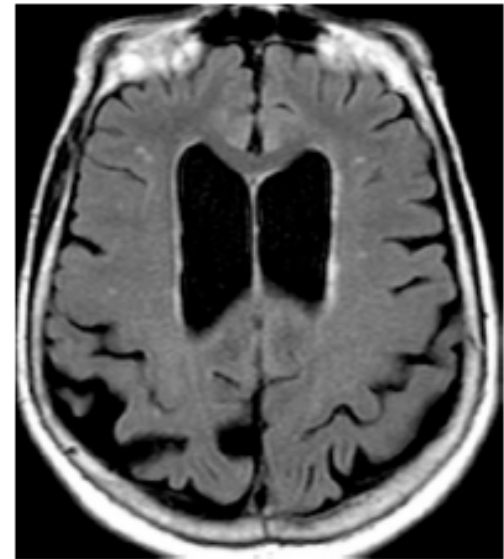
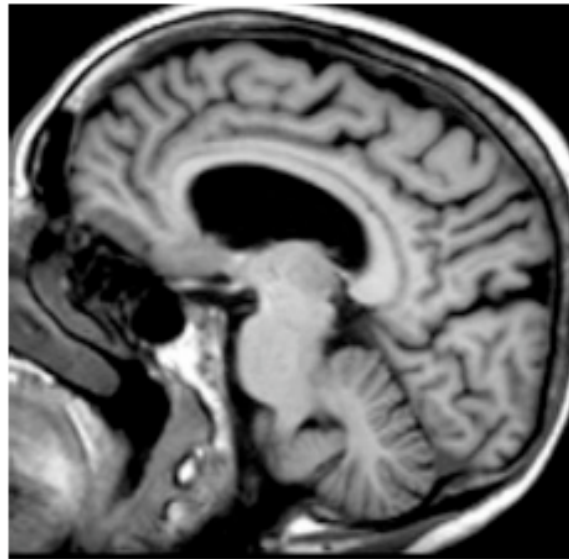
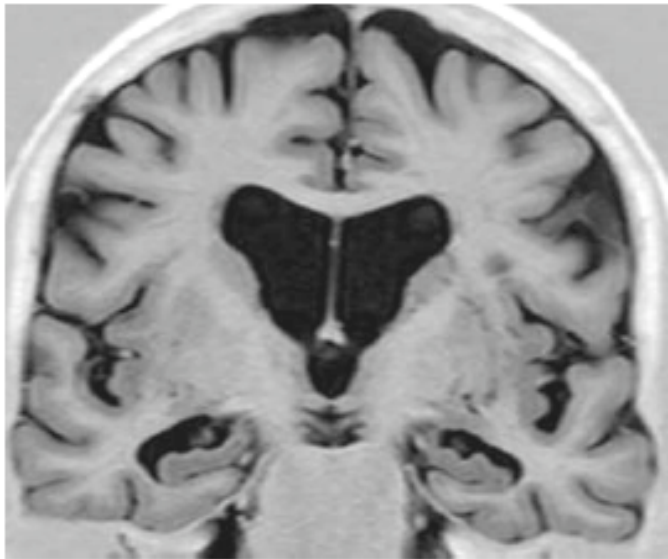
# DLFT – APP

---



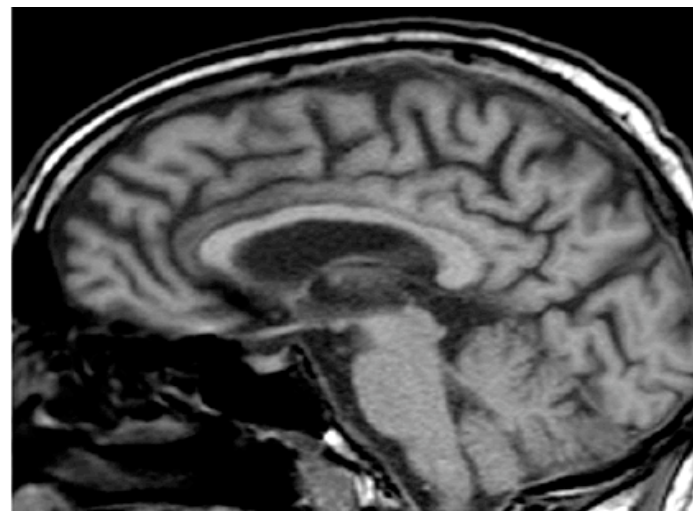
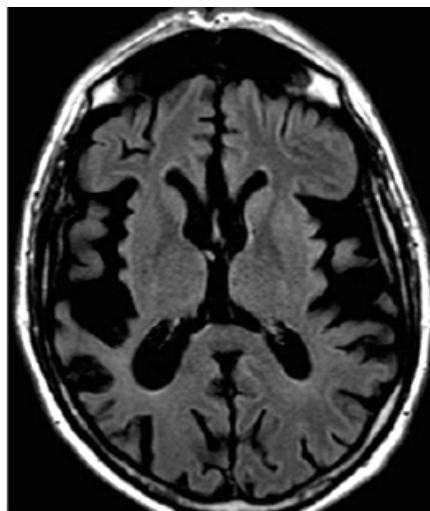
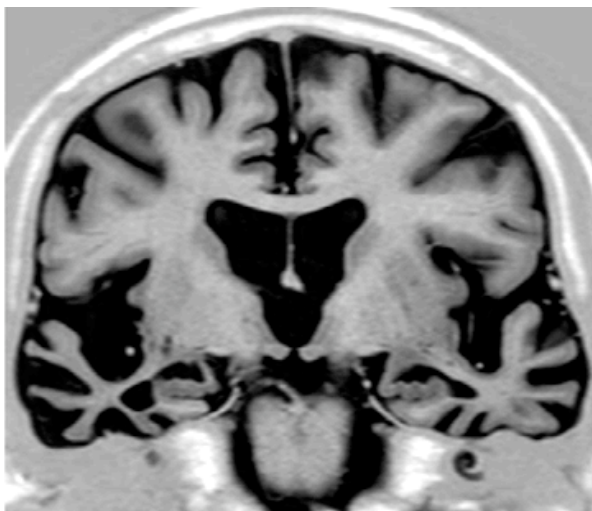
# MA

---



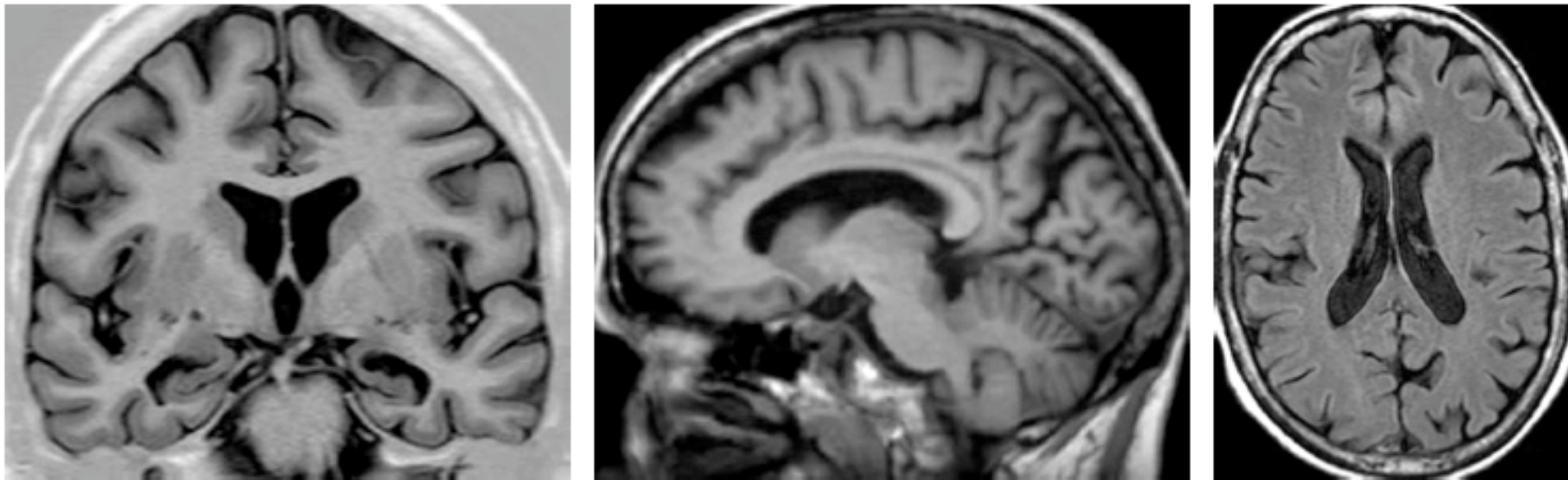
# DLFT – D. Sémantique

---



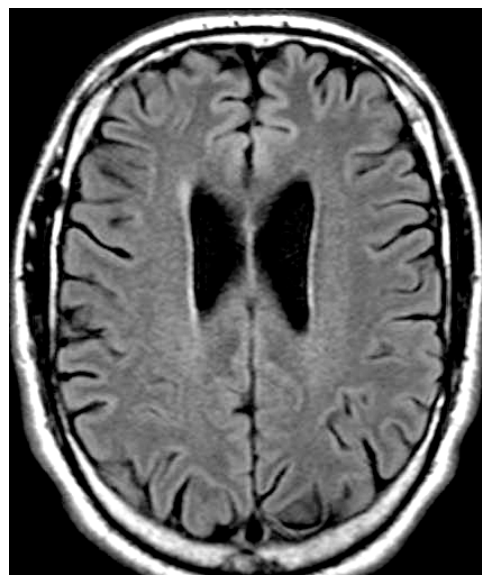
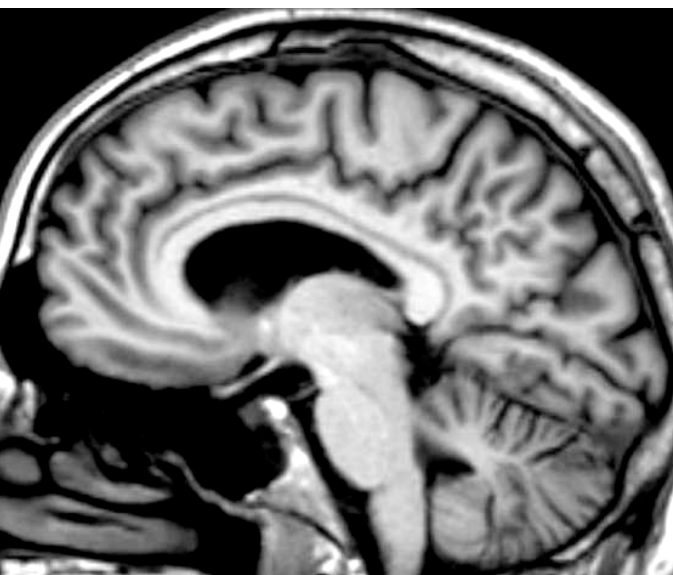
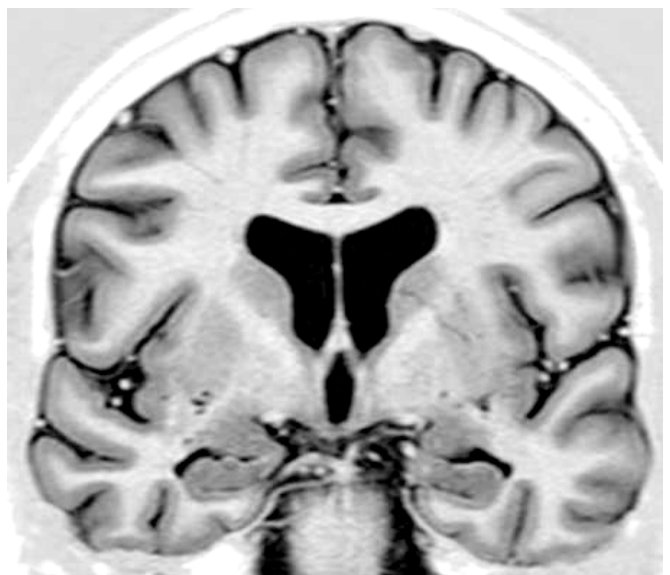
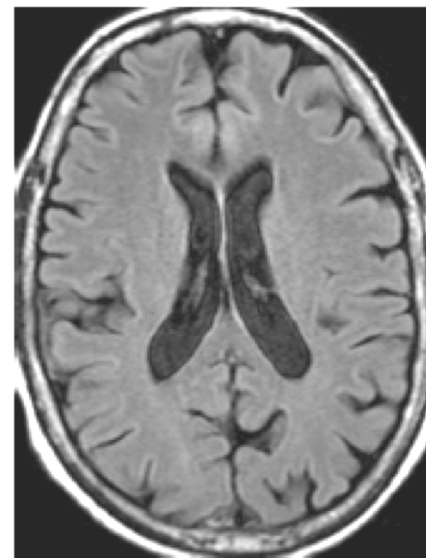
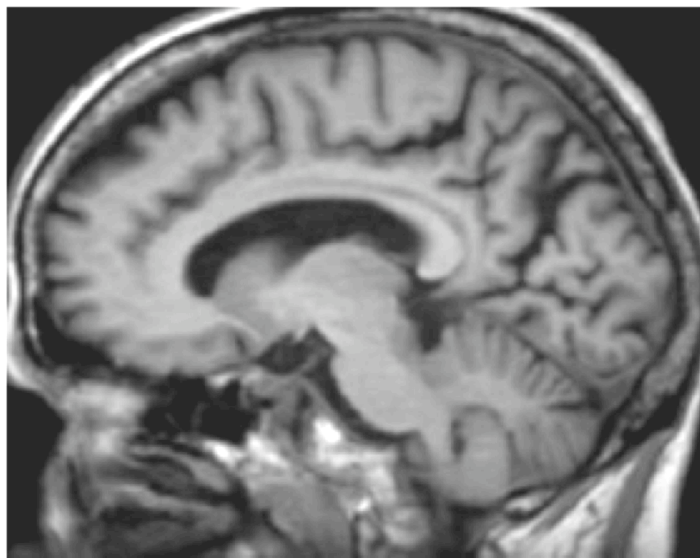
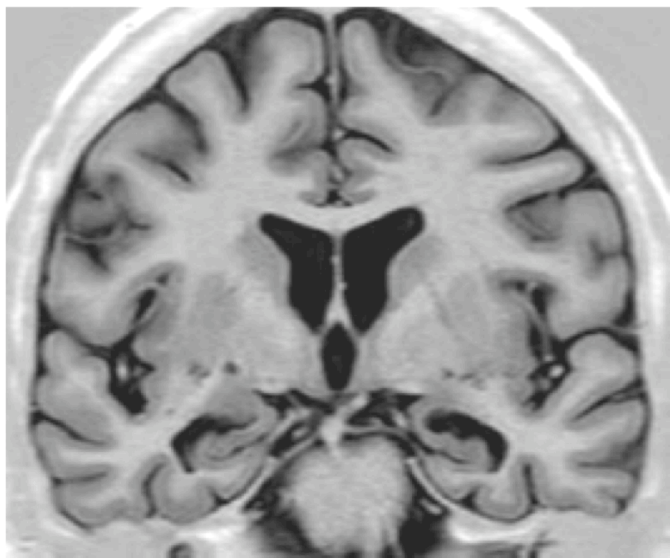
# MA

---



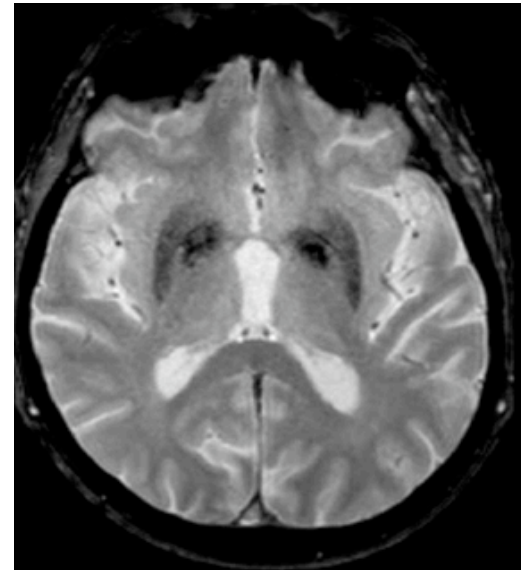
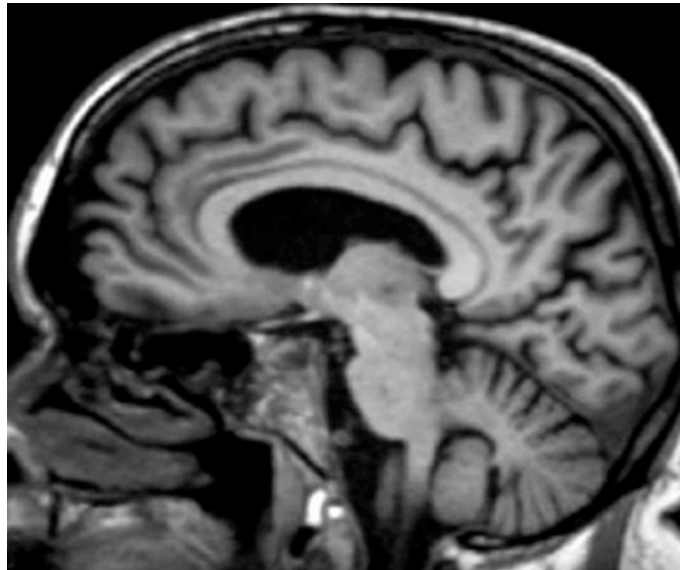
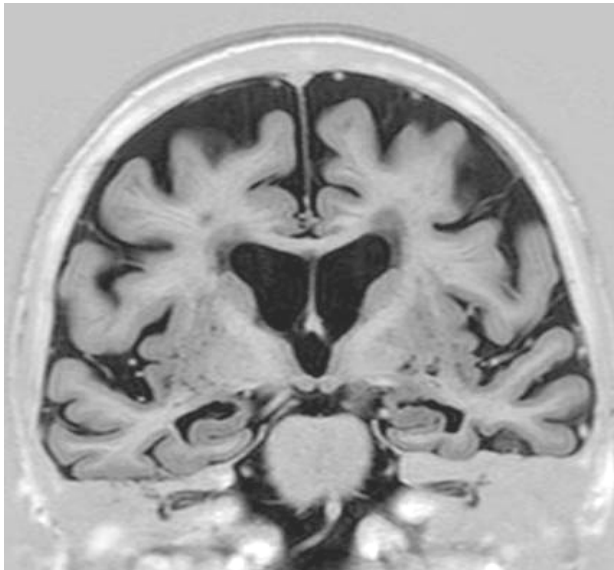
# MA ?

---



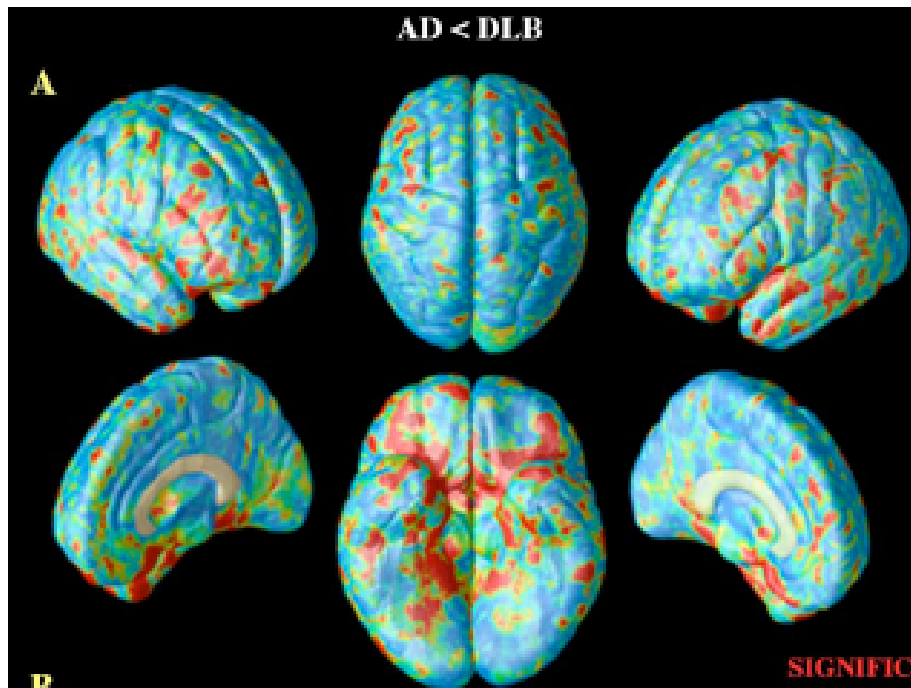
# DCL

---

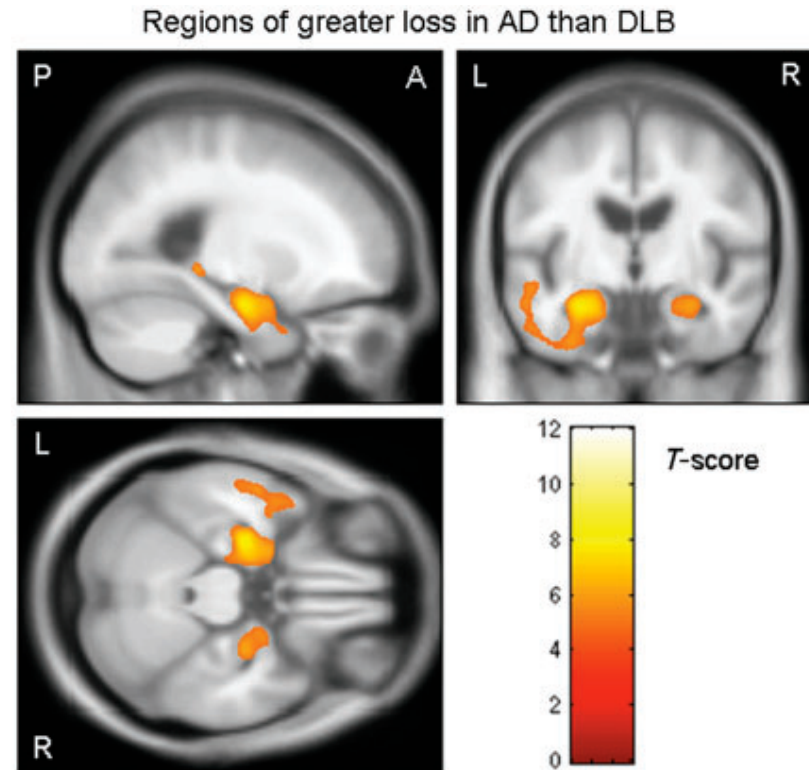


# DCL

---



Ballmaier, *Neuroimage* 2004

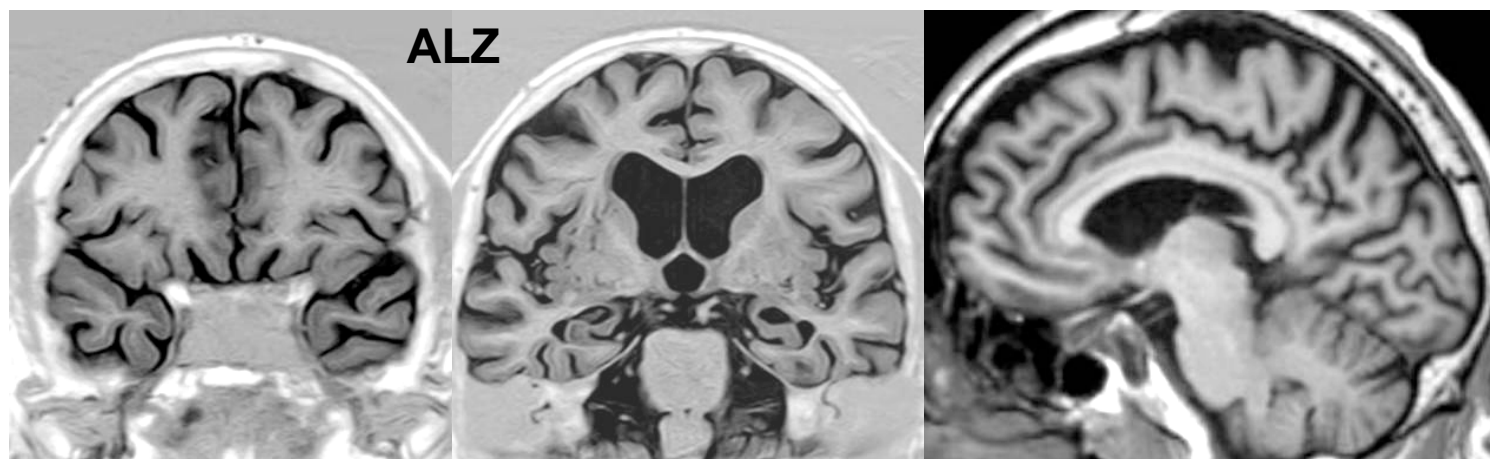
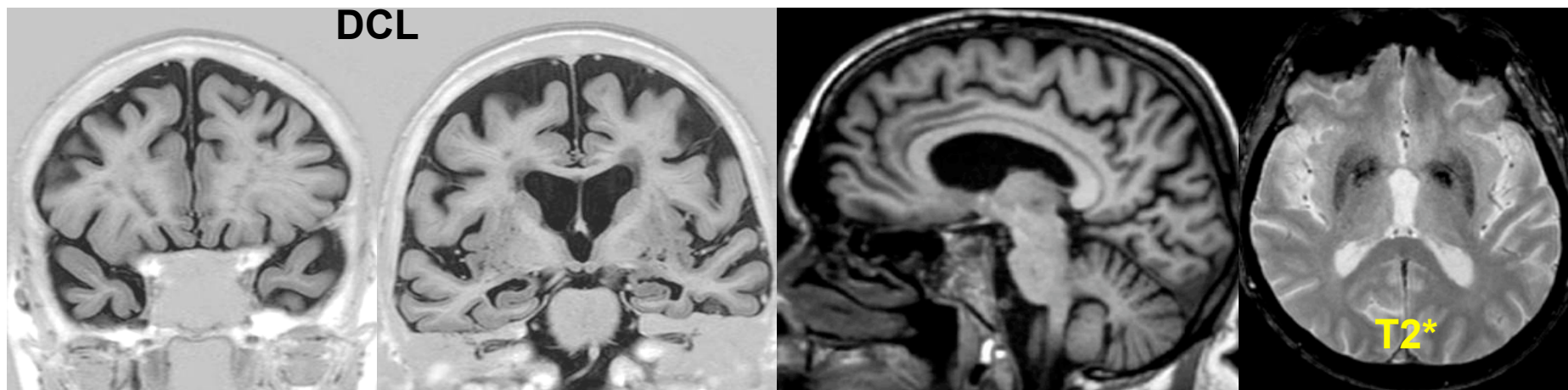


Whitwell, *Brain* 2007



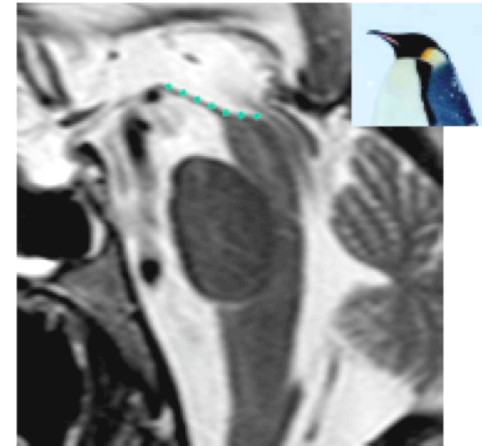
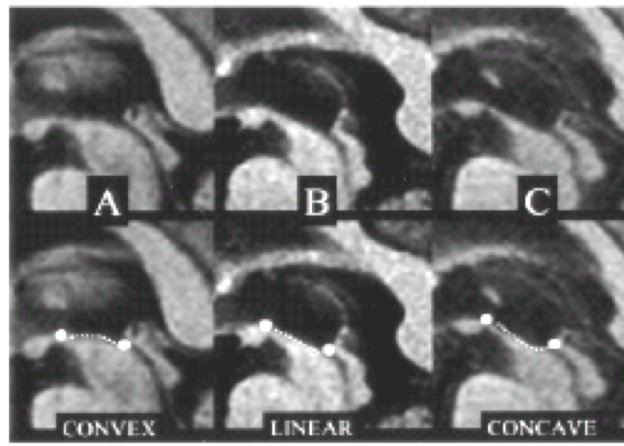
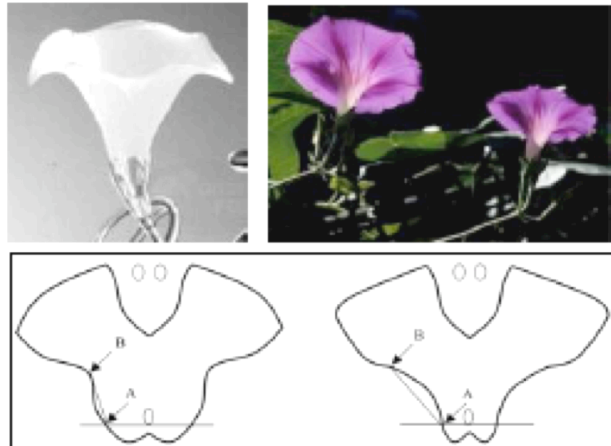
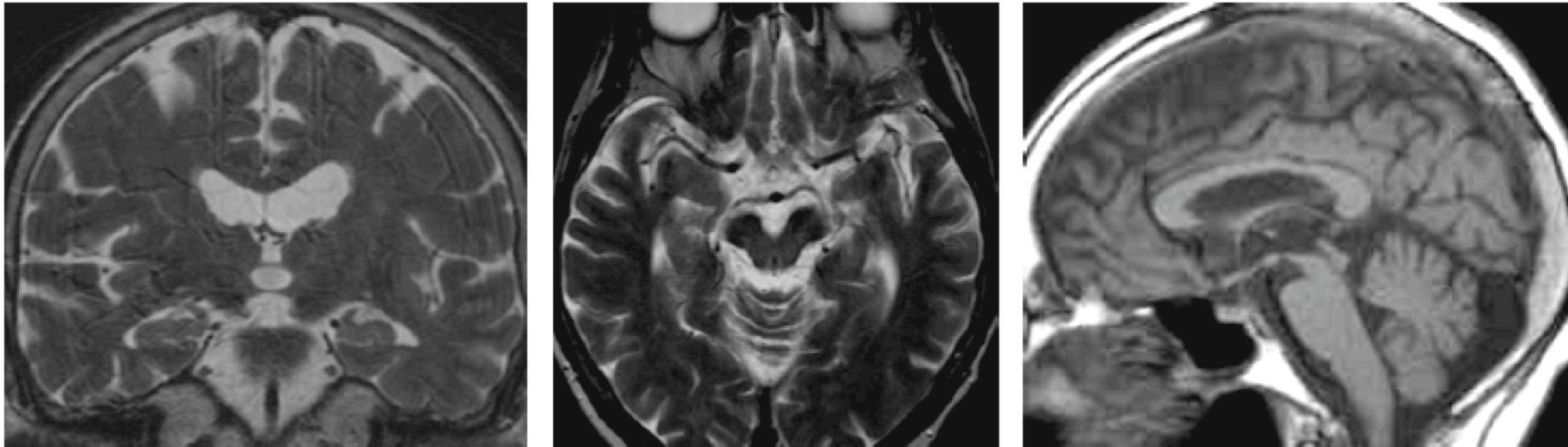
# DCL vs ALZ

---



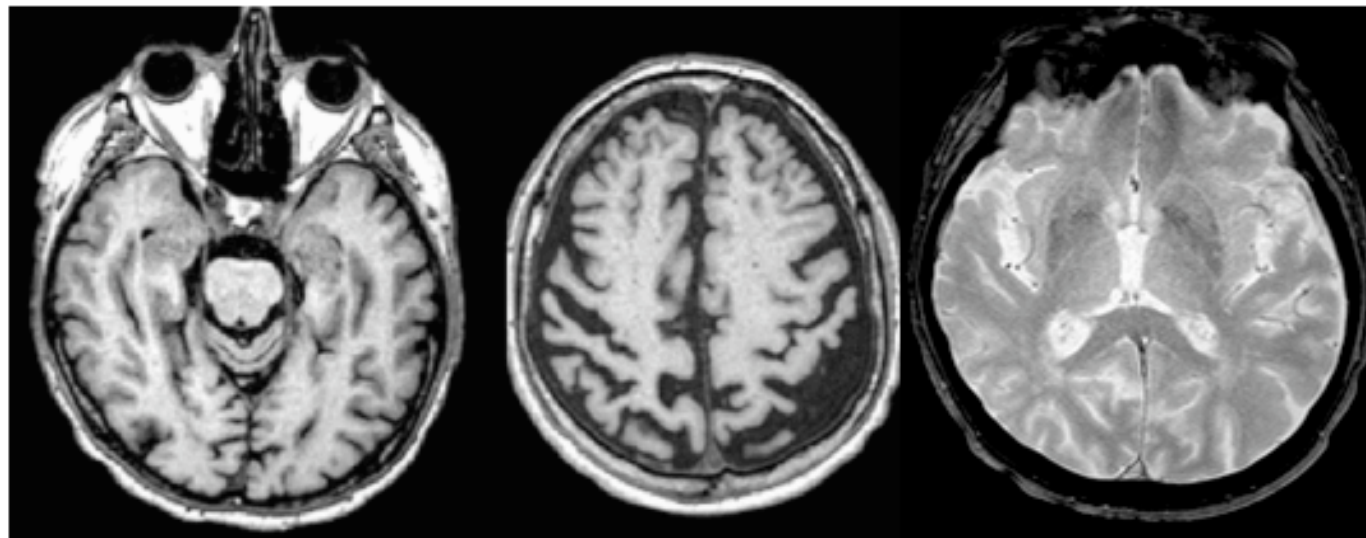
➔ DATscan®, PIB1,...?

# Paralyse supra-nucléaire progressive



# Dégénérescence cortico-basale

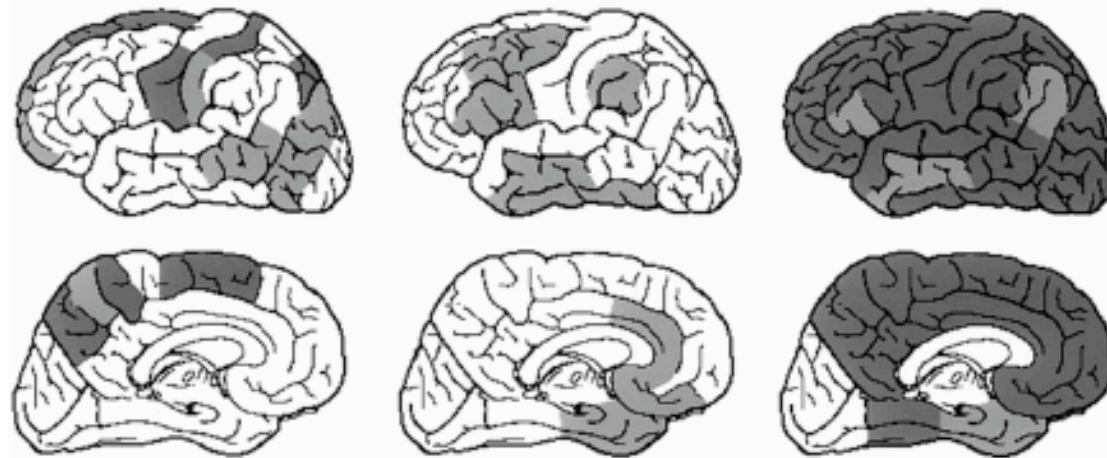
---



CBD vs AD

AD vs NC

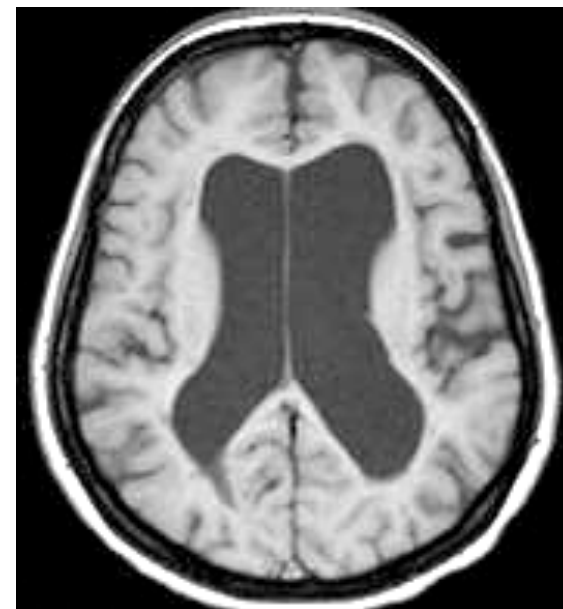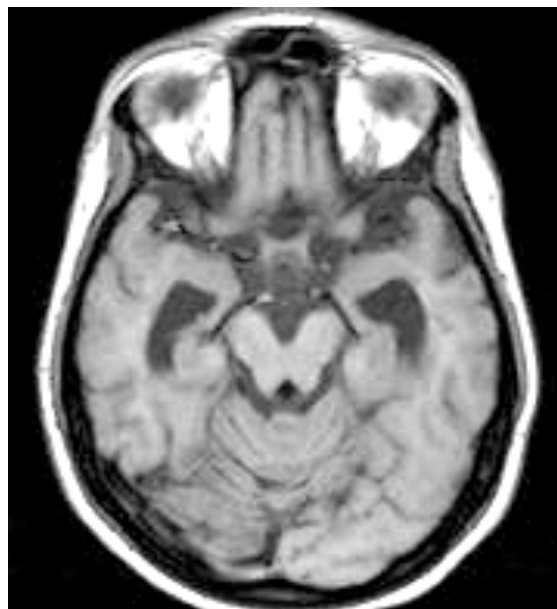
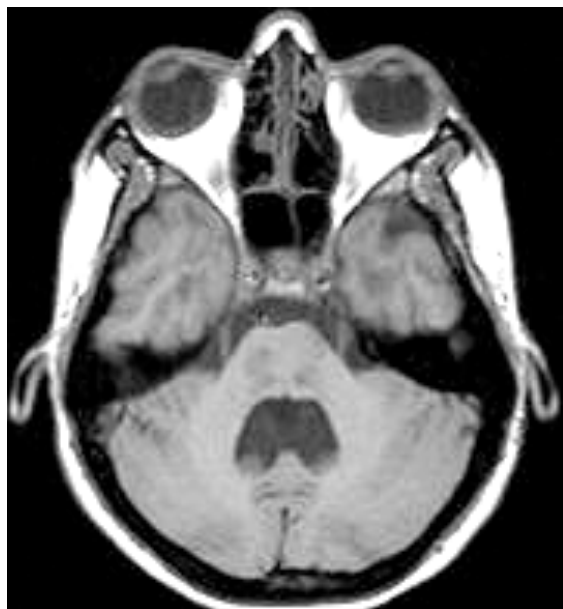
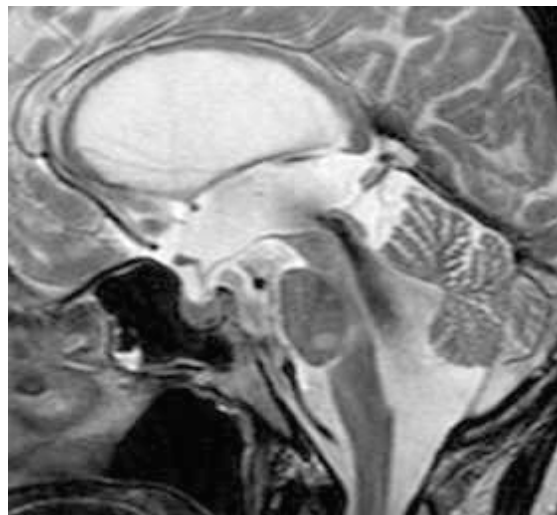
CBD vs NC



Kitagaki, *Radiology* 2000

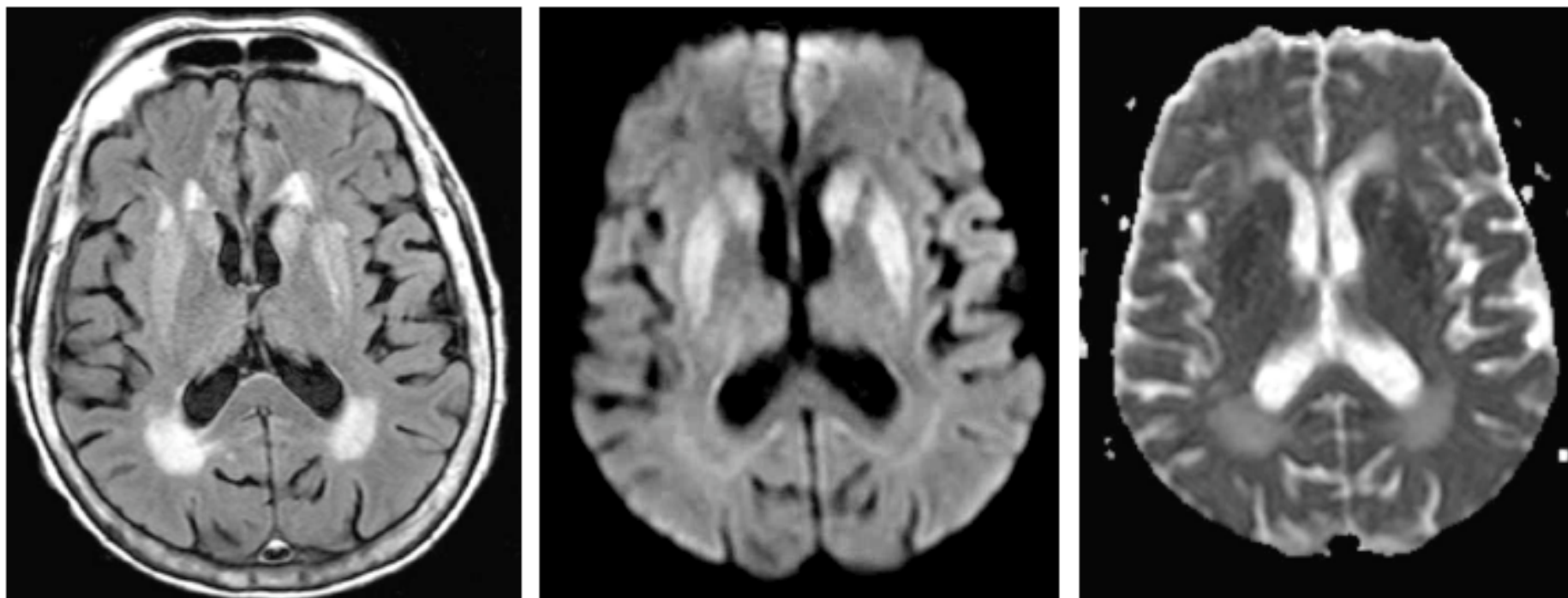
# Hydrocéphalie chronique de l'adulte

---



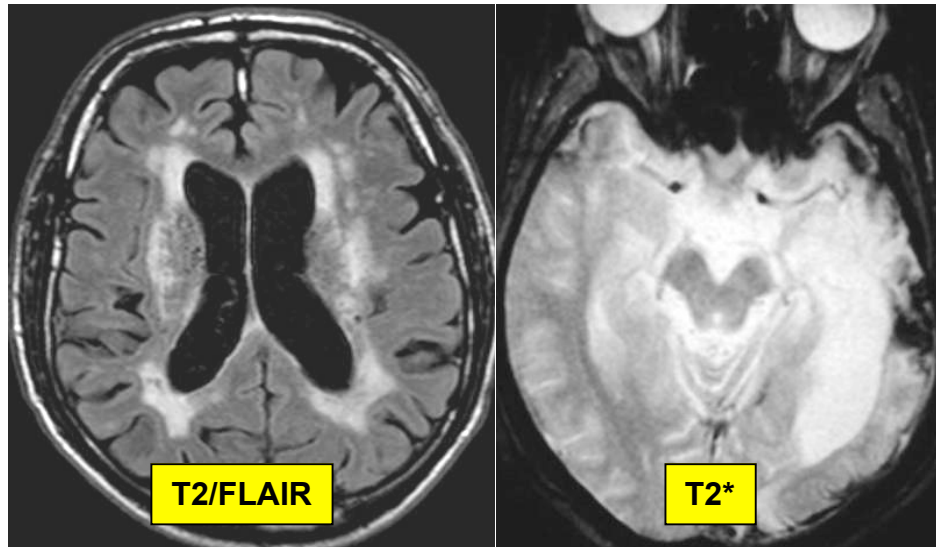
# M. Creutzfeldt-Jacob

---

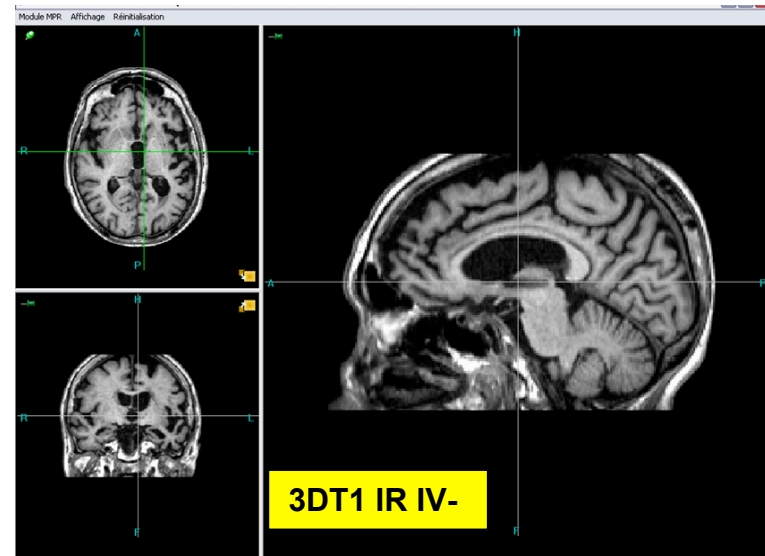


# Acquisition IRM : recommandations

Éliminer les autres causes de démences et voir les lésions vasculaires

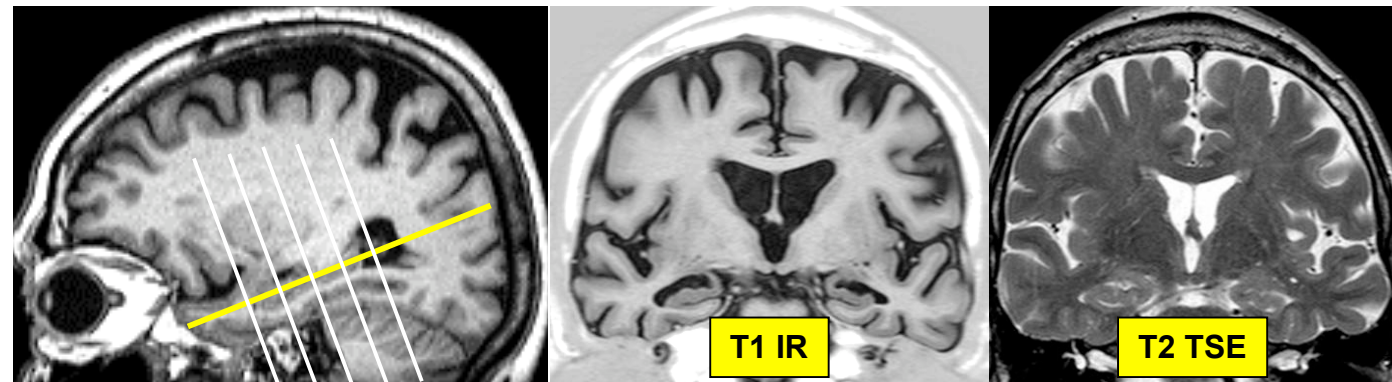


Volumétrie cérébrale



Voir les hippocampes

**± DWI**



# Neuro-imagerie et MAMA

---

- Démarche diagnostique
  - Cause « chirurgicale » (TDM)
  - Cause « médicale » (IRM)
  - Cause « neurodégénérative » (IRM)
- Recommandations IRM
  - T2 (TSE / FLAIR), T2\* (EG)
  - Frontal hippocampe, 3D (T1 ou T2)
  - DWI...
- Avantages
  - Morphométrie reproductible
    - Atrophie de l'hippocampe
    - Gradient d'atrophie fronto-pariétale...
  - Accessibilité, non-invasivité, coût
- Inconvénients
  - « Polymorphisme »
  - Interprétation des données

## Perspectives

- → Imagerie multi-modale (techniques avancées et Médecine Nucléaire...)
  - → Analyse multi-paramétrique
- → Nosologie clinique X Nosologie imagerie X Nosologie biologique X Nosologie anatomo-pathologique

# Neuro-imagerie et MAMA

---

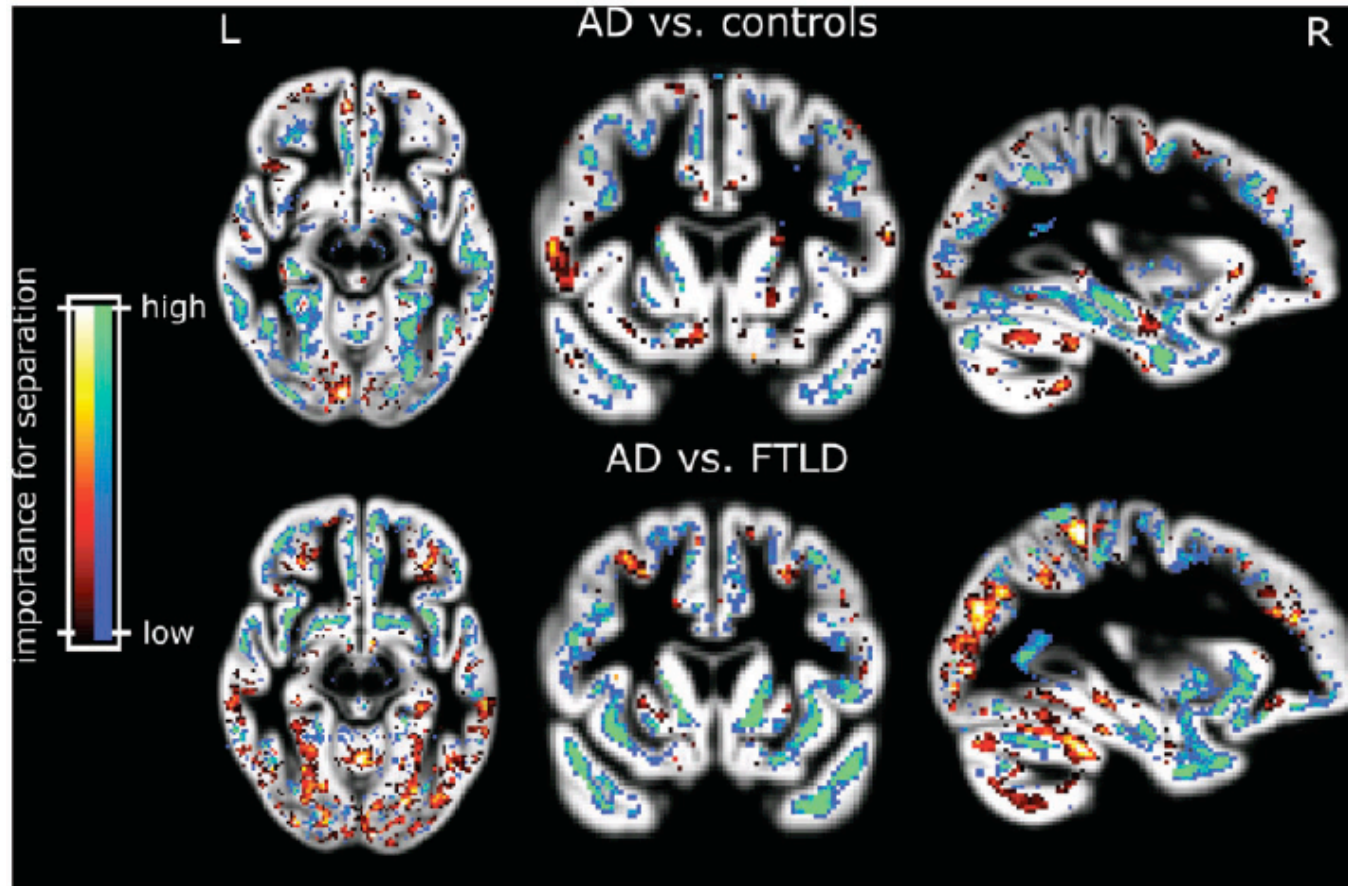
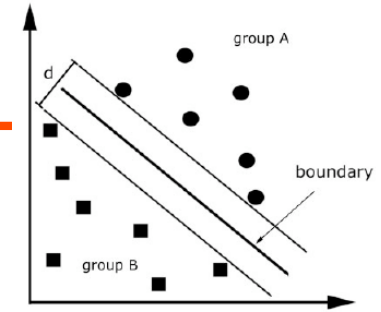
## Perspectives

- Morphométrie
- IRM du tenseur de diffusion
- Spectroscopie
- IRM fonctionnelle



# Morphométrie : Classificateurs SVM

- Catégorisation multi-paramétrique : exactitude >90%

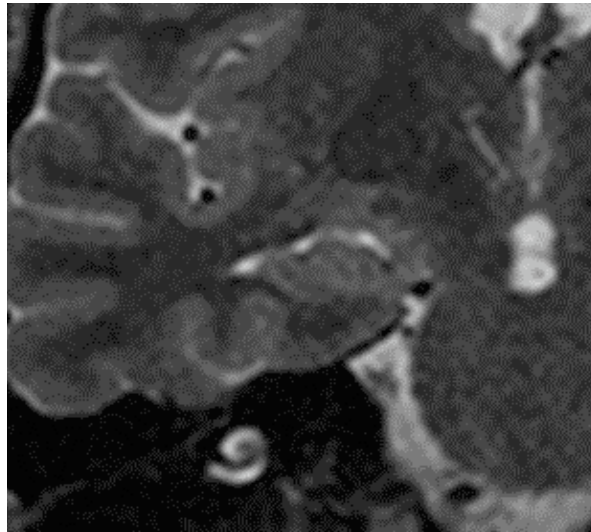


Klöppel, *Brain* 2008

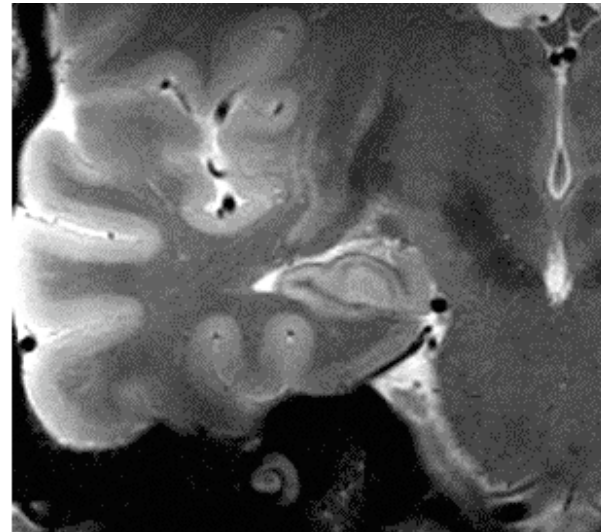
# IRM à très haut champ : $\geq 7T$ ...

---

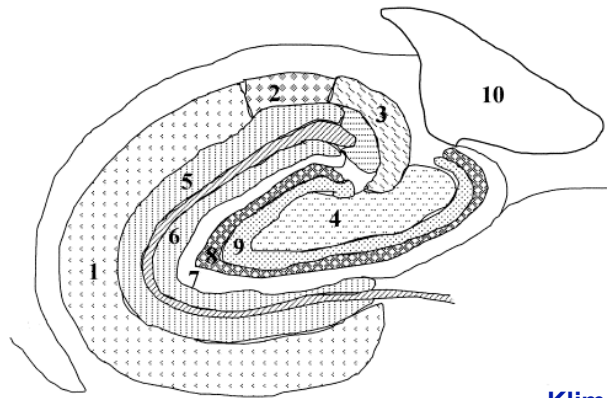
1,5T



7T



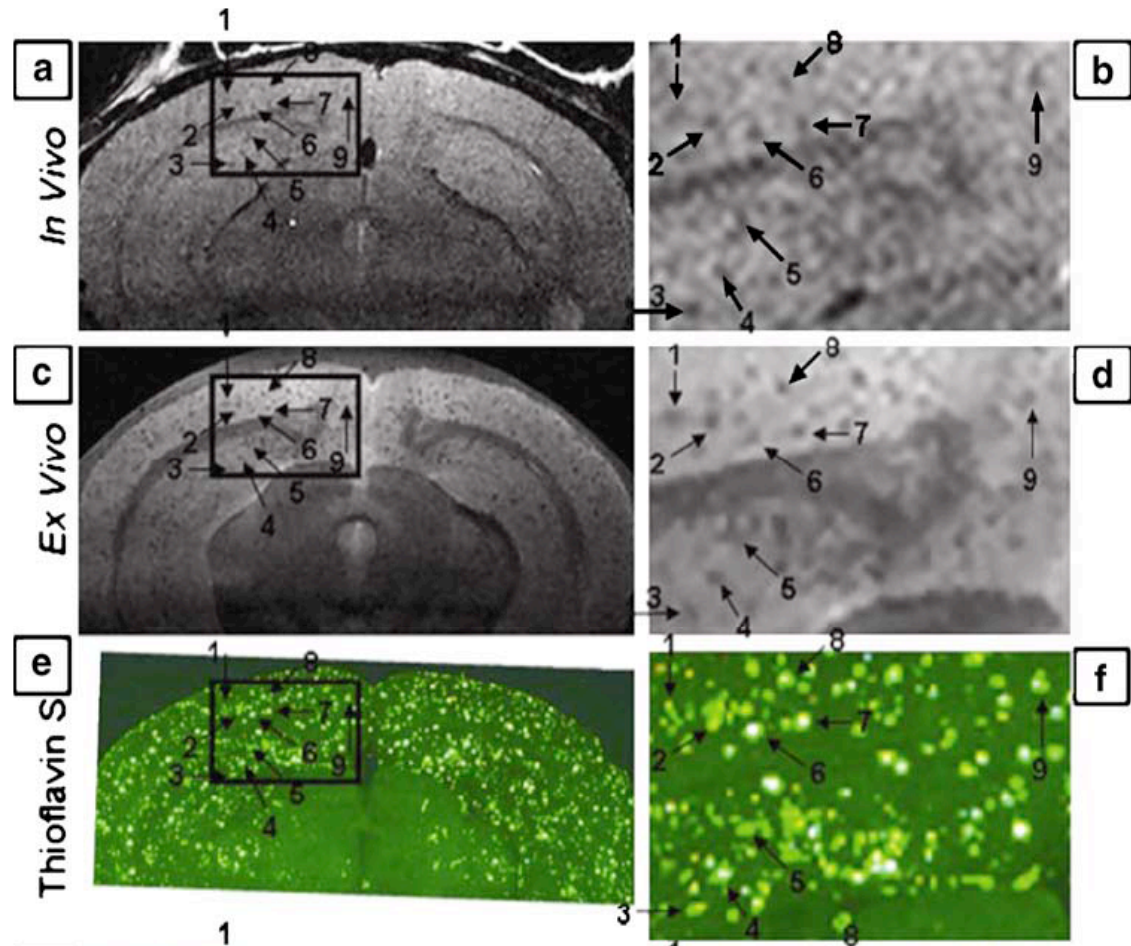
Norris, Radboud Univ. Nijmegen



Klimek Neuropsychopharmacology 1999

# Microscopie IRM

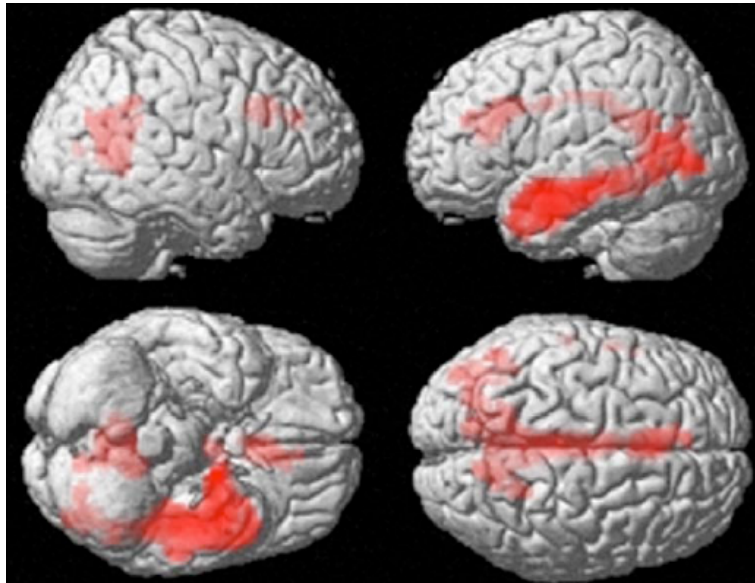
- Plaques A $\beta$ 
  - 2 - 200  $\mu$
- IRM >7T
  - T2\* EG
  - Vox=40 $\mu$
  - > 1 heure
- TEP
  - PIB



Jack, *J Neurosci* 2005

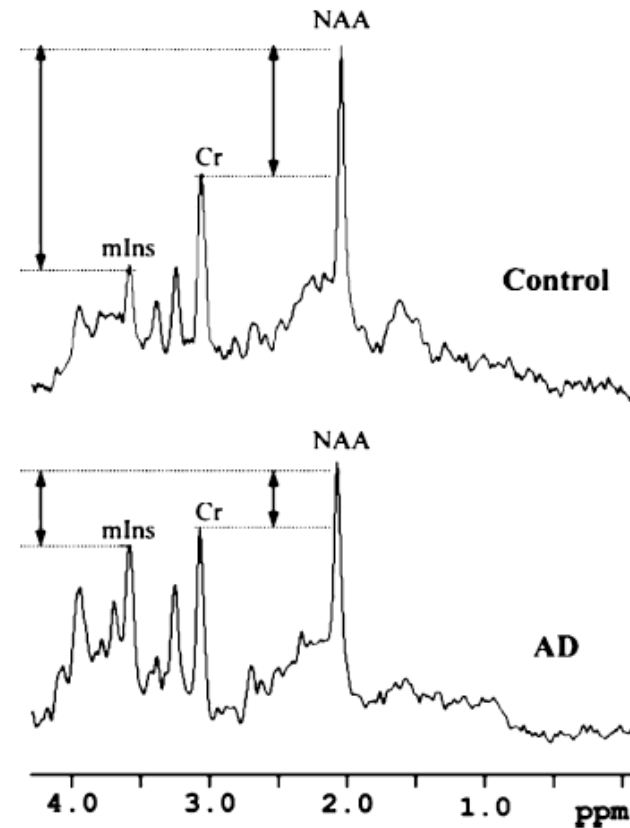
# IRM du tenseur de diffusion - Spectroscopie

VB-DTI (AF) : Alz vs Sain



- Validité sur groupe
- Pas de validité individuelle
- Distinction MA - Sain
- Pas de distinction entre MAMA

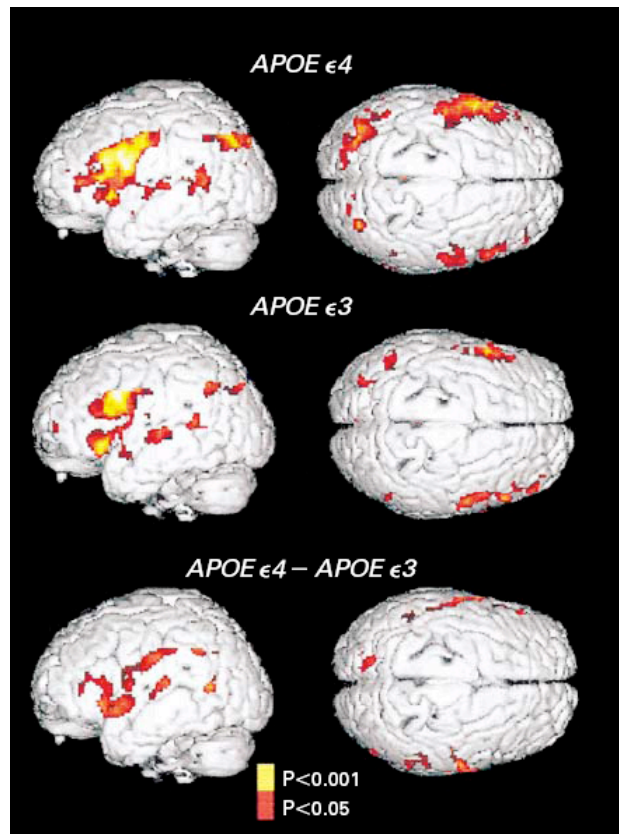
Posterior cingulum SVI – TE=30ms



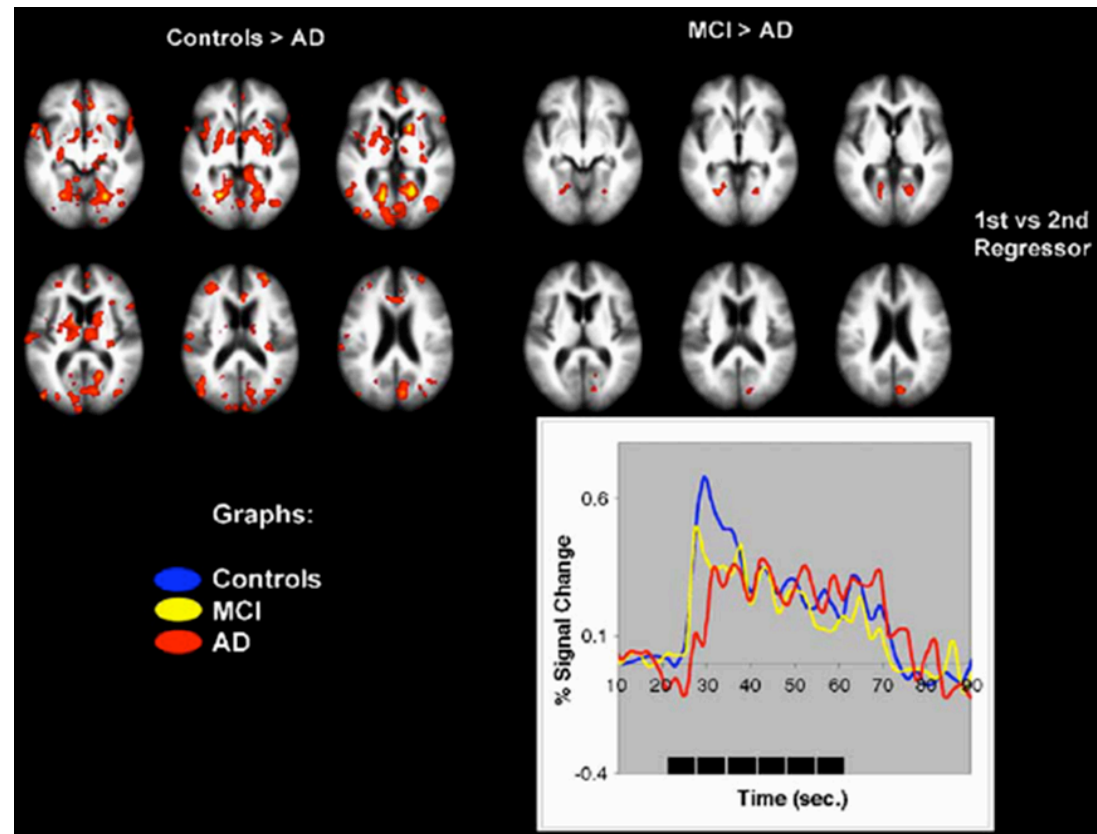
Lehéricy, *Eur Radiol* 2007

# IRM fonctionnelle cognitive

- Encodage mnésique visuel



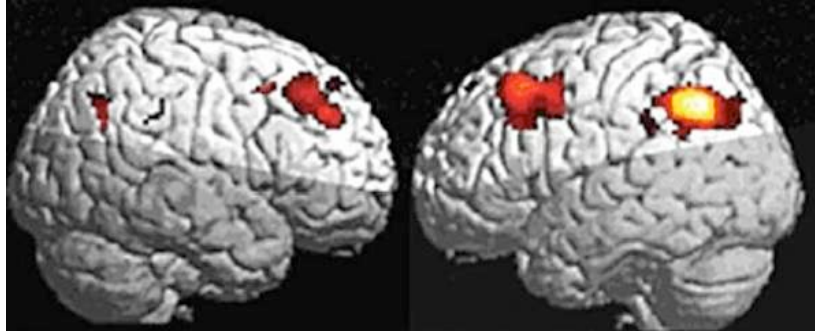
Bookheimer, *NEJM* 2000



Rombouts, *Neuroimage* 2005

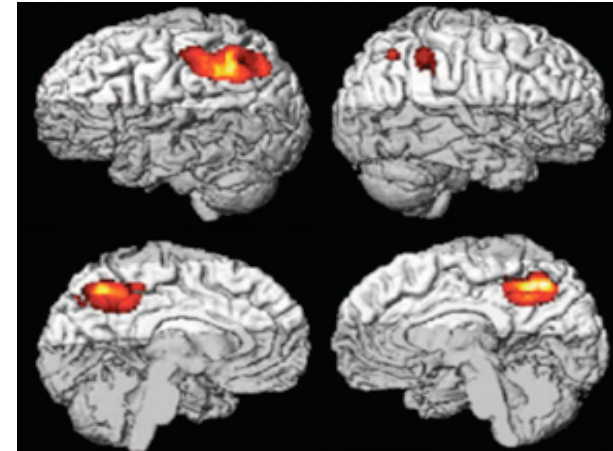
# IRM fonctionnelle perfusion

Perfusion basale ASL  
Sain vs ALZ



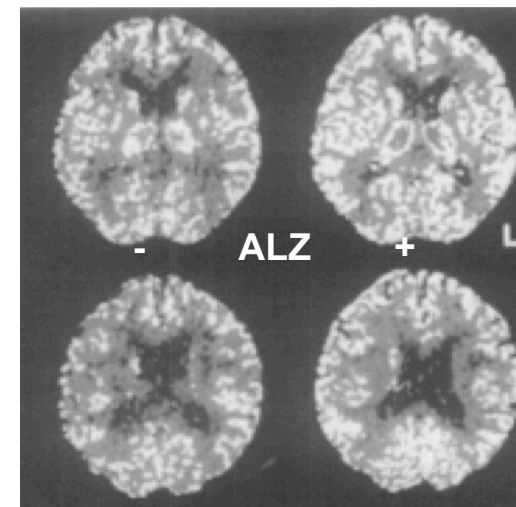
Johnson, *Radiology* 2005

Perfusion basale ASL  
DFT vs ALZ



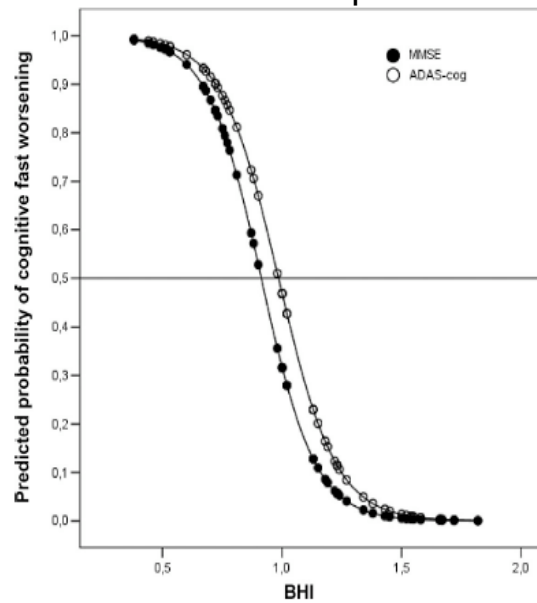
Du, *Neurology* 2006

CT Xenon – ACZ



Oishi, *J Clin Neurosci* 1999

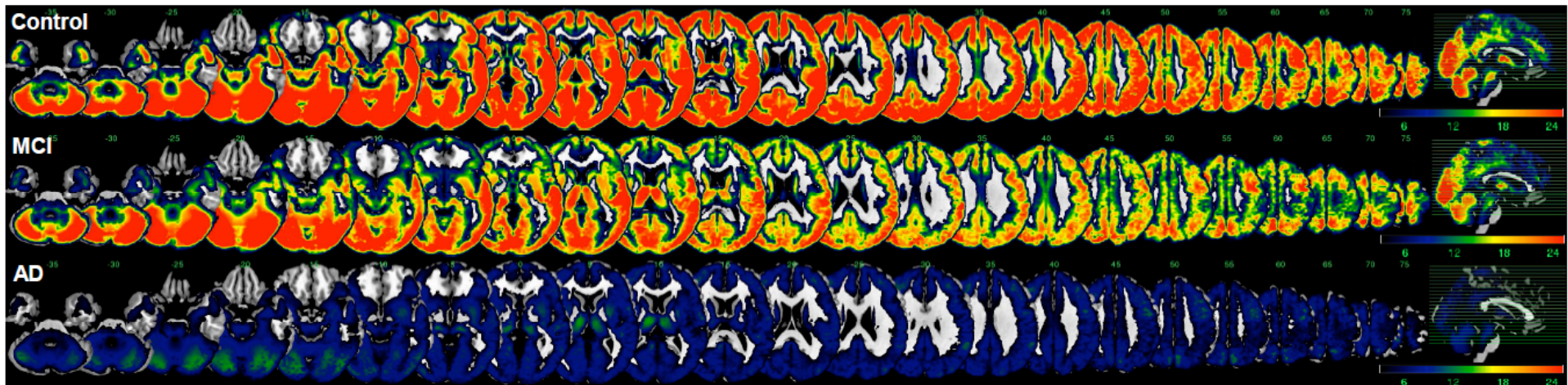
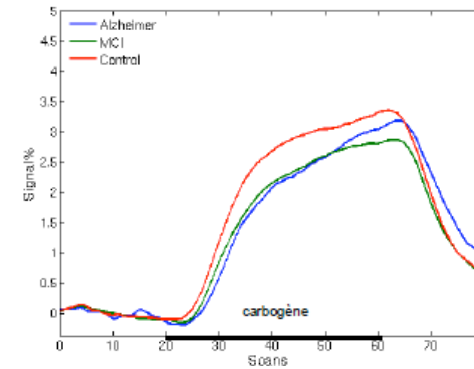
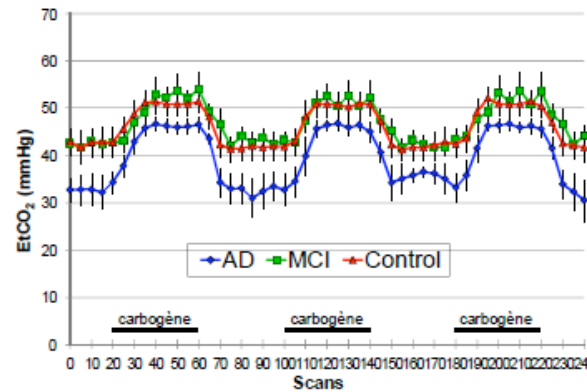
TCD - Apnea



Silvestrini, *Stroke* 2006

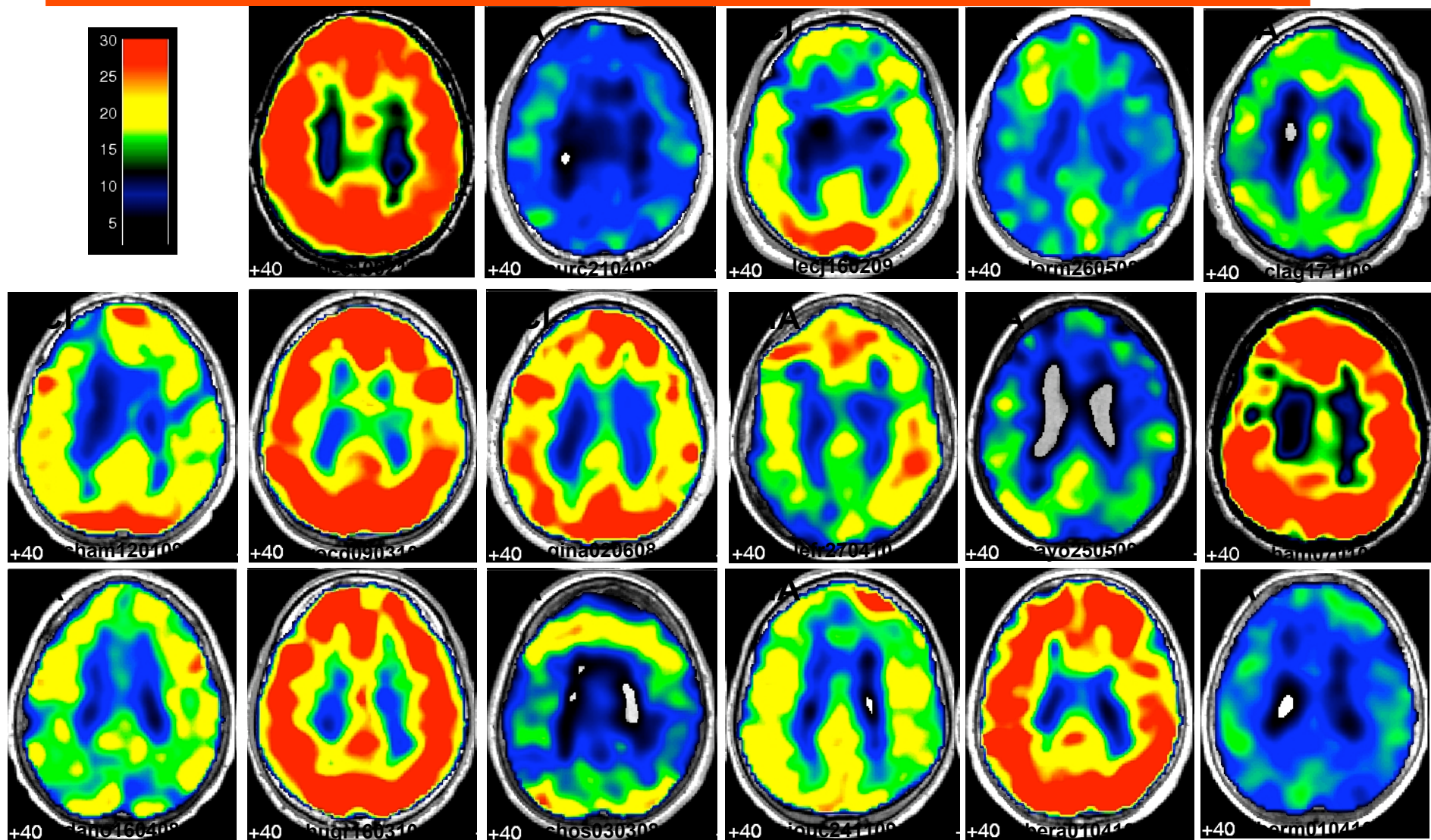
# CEVASAL – Preliminary results PHRC 2007

- BOLD fMRI – Carbogen inhalation (CO<sub>2</sub> 7% - O<sub>2</sub> 93%)
- Control (n=10): 64yo; MMSE=29
- MCI (n=8): 67yo; MMSE=26
- ALZ (n=8): 72yo; MMSE=22



Krainik et al. *ICVD Barcelona 2009*

# Vasoréactivité Alzheimer FAZEKAS $\leq 1$ BOLD $CO_2$ 7% / $O_2$ 93%



317=129 140 163



# Remerciements

---



- Pr Jean-François Le Bas, Dr Irène Troprès et toute l'équipe de l'IRM
- Dr Olivier Moreaud, Dr Armelle Memin et toute l'équipe du CMRR
- Pr Pascal Couturier, Pr Alain Franco et toute l'équipe de Gériatrie
- Dr Jan Warnking et toute l'équipe 5 du GIN

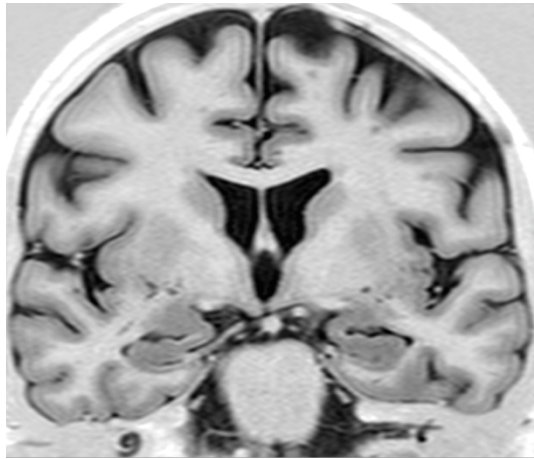




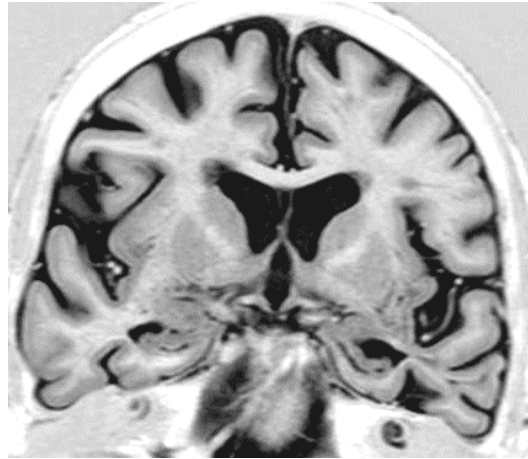
# Quelques exemples

---

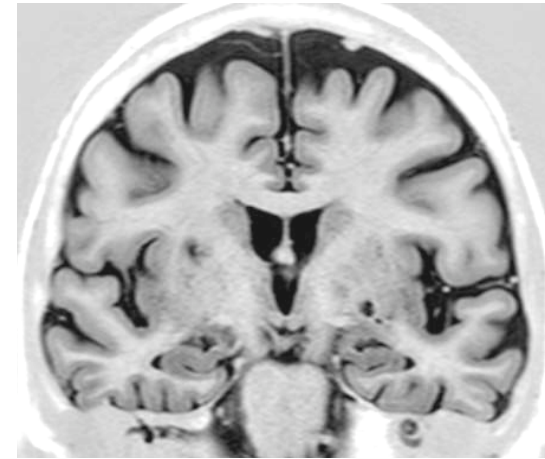
Normal



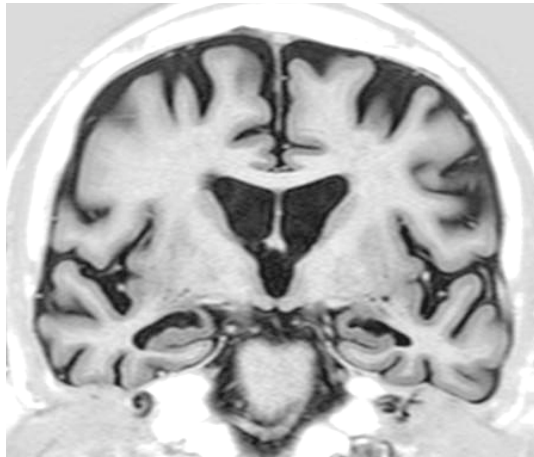
MA



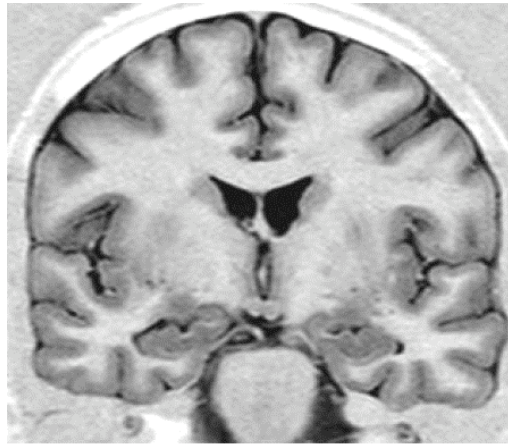
TCL-a



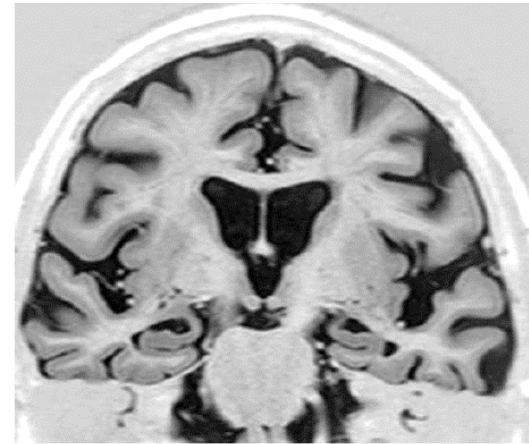
MA



Normal



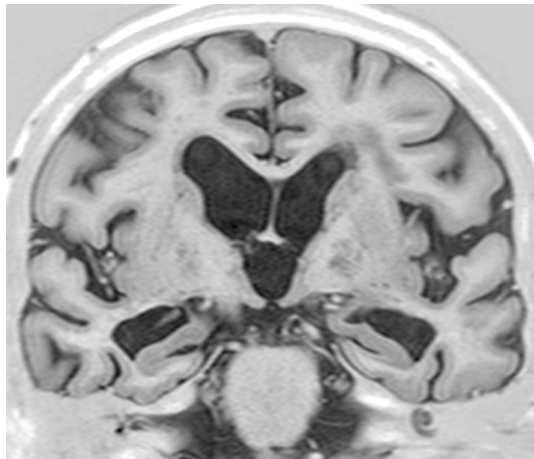
MA



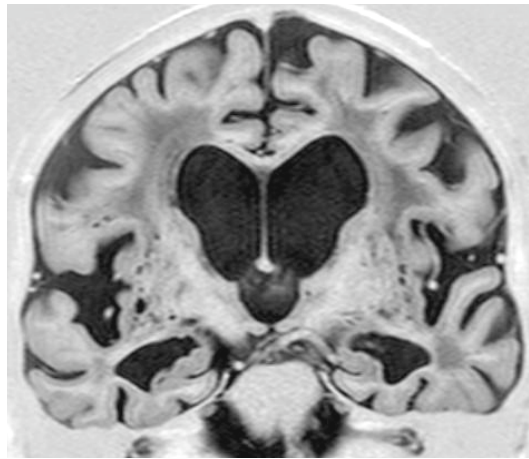
# Quelques exemples

---

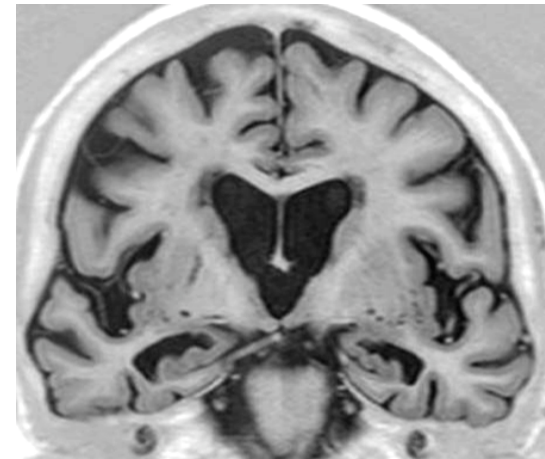
DFT



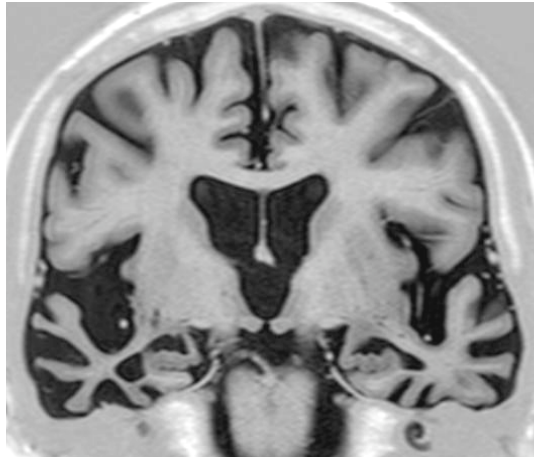
D. Mixte



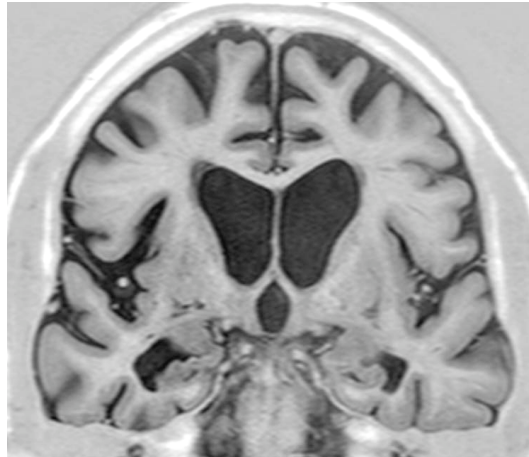
MA



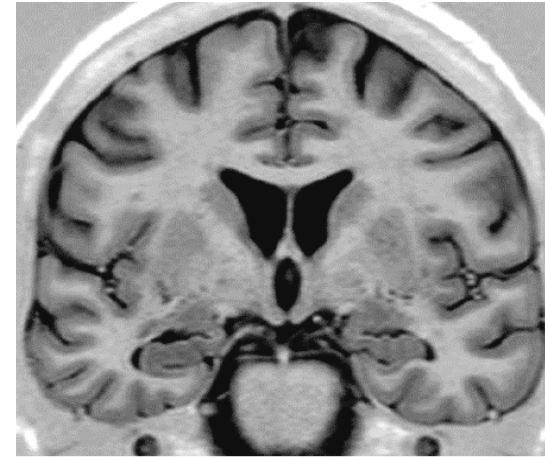
DFT - DS



DCL

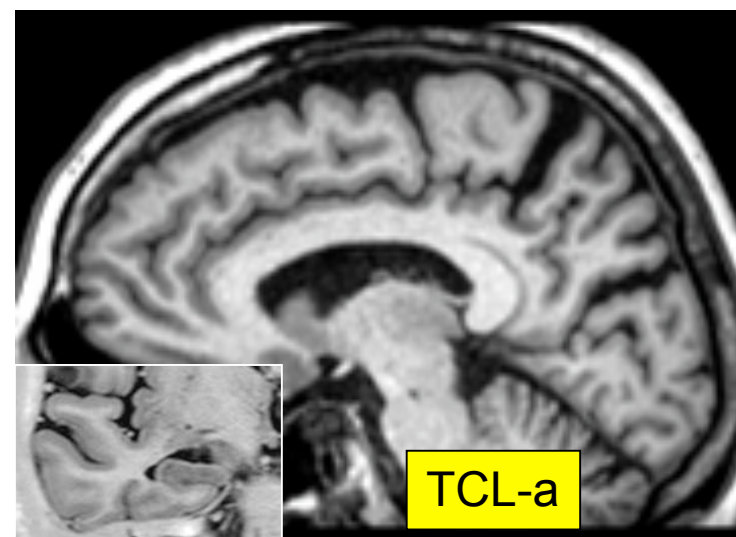
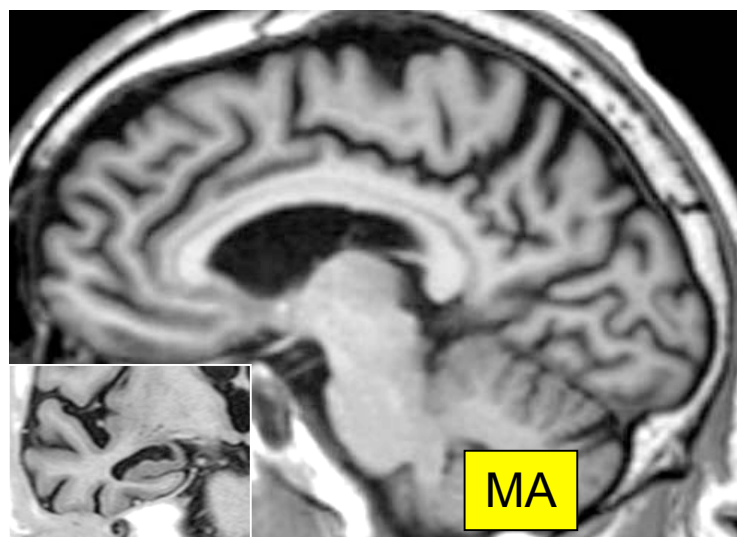
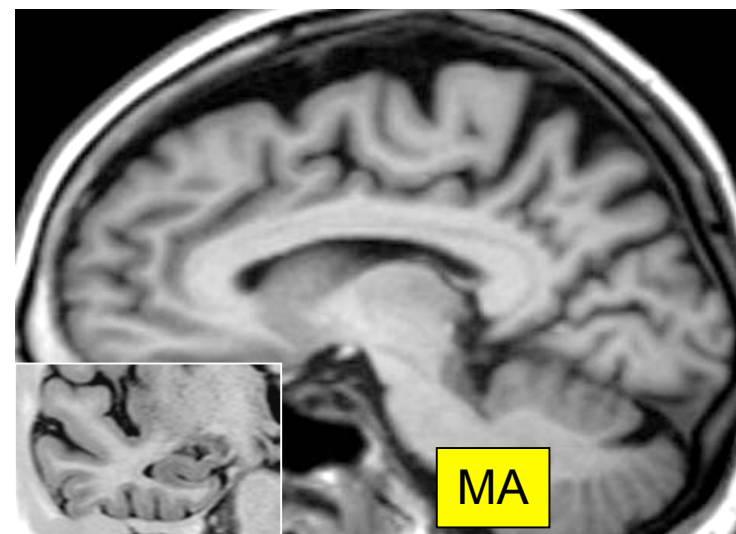
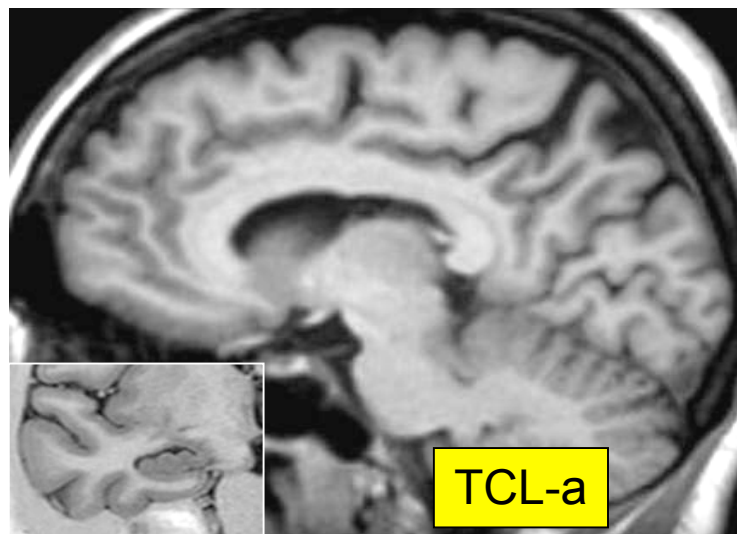


MA



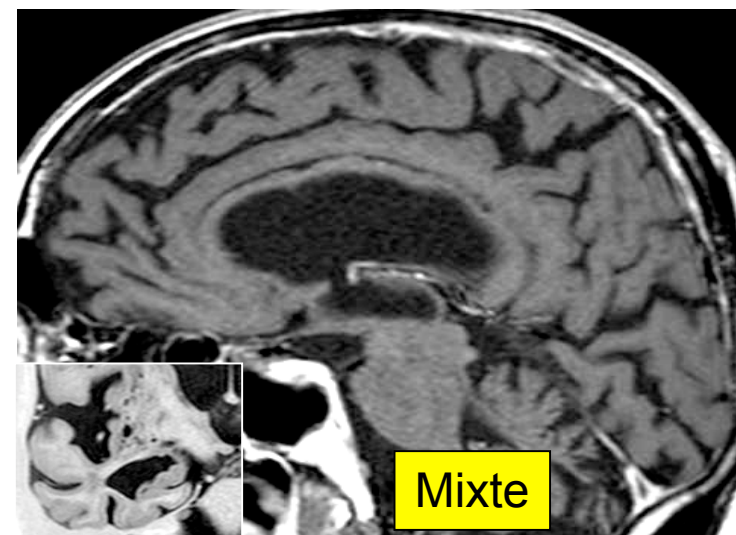
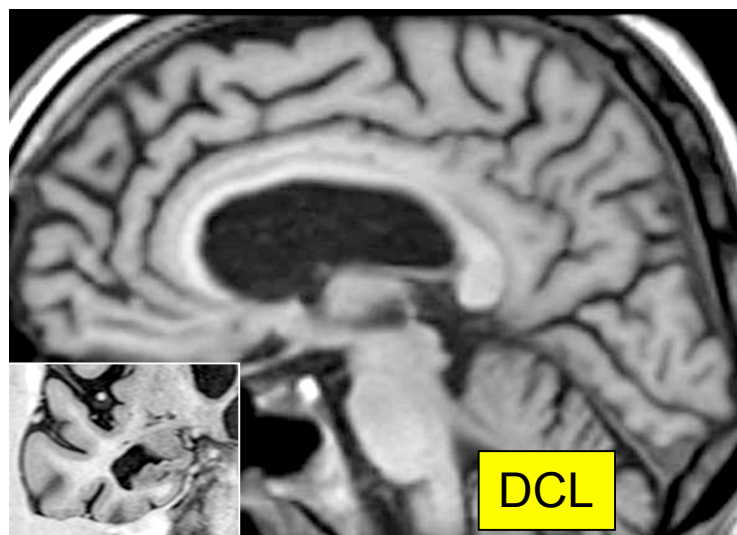
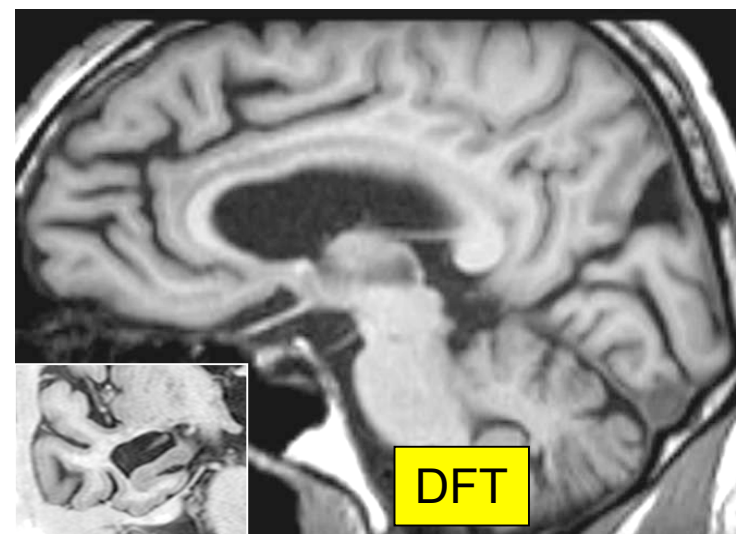
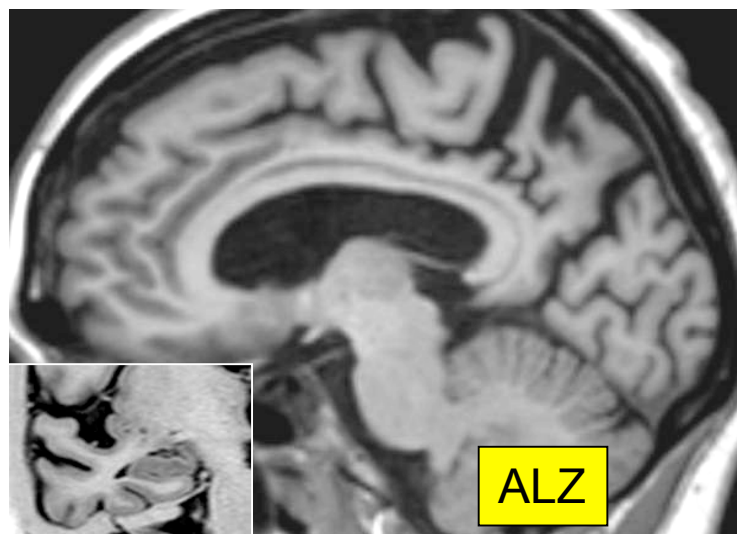
# Morphométrie cérébrale

---



# Morphométrie cérébrale

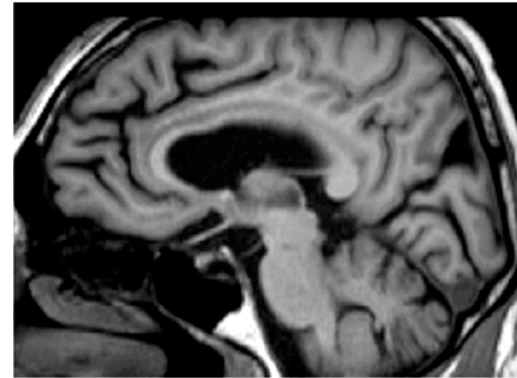
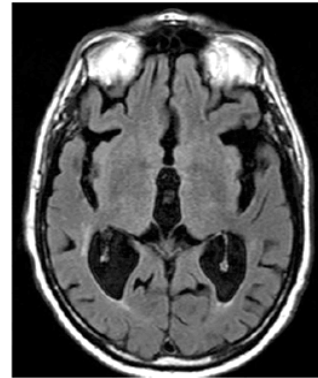
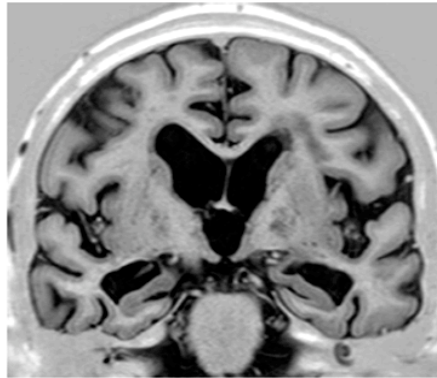
---



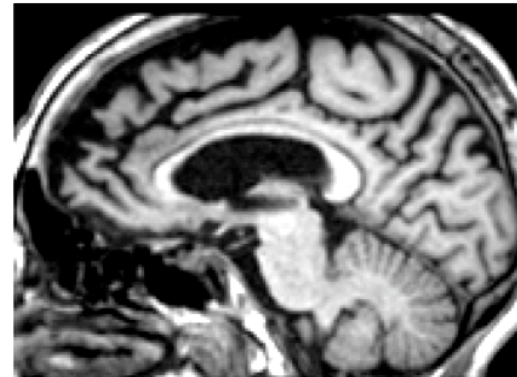
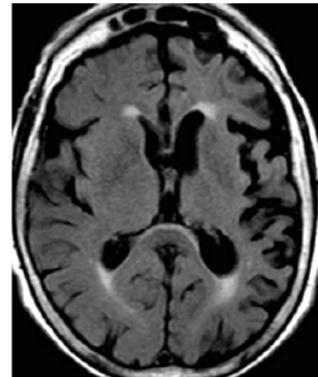
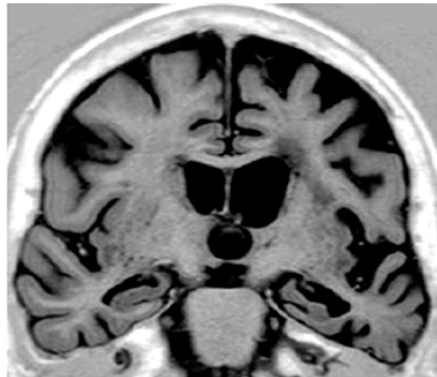
# Morphométrie cérébrale

---

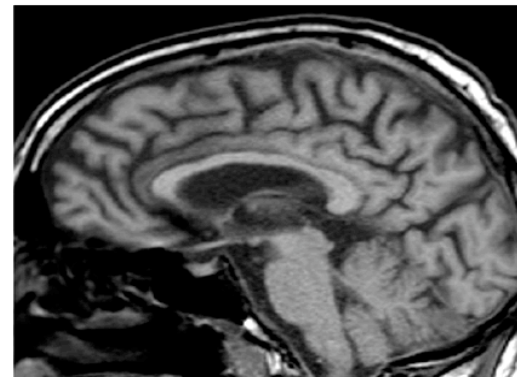
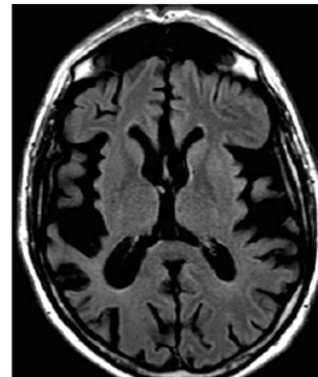
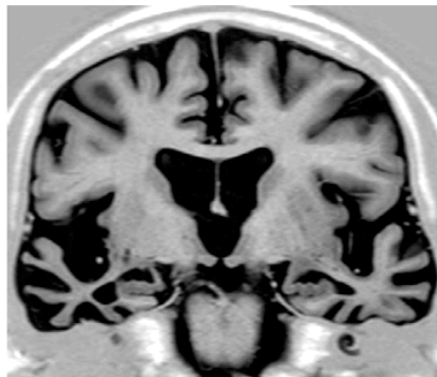
DFT



APP



Démence  
Sémantique

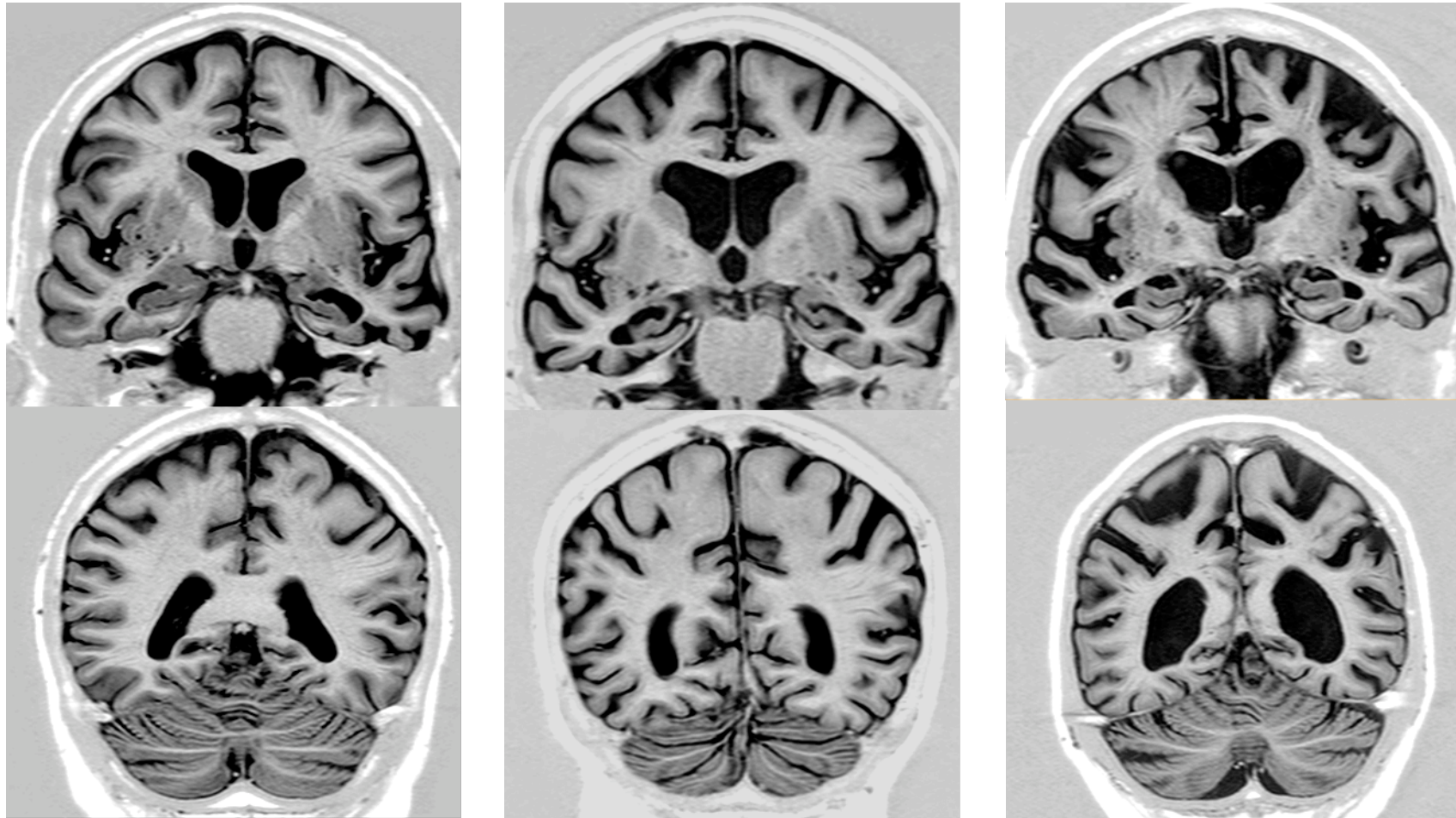




# Morphométrie cérébrale

---

- La pratique montre le « polymorphisme morphométrique de la MA »



# Glioblastome

---

