Radiologie de l'otospongiose
Société de Radiologie
Rhône Alpes Auvergne
Saint-Etienne
Décembre 2009

Christian Martin & Bernard Fraysse
Charles Veyret & Bernard Escudé
& Jean François Pouget

LOCALISATION DES LESIONS

- Fenêtre ovale 96 %
- Autres localisations 49 %
  - Péri-cochléaire
  - Fenêtre ronde
  - Conduit auditif interne
  - Foramen cochléaire

+ Concept : Otospongiose cochléaire pure

RAPPEL HISTOLOGIQUE

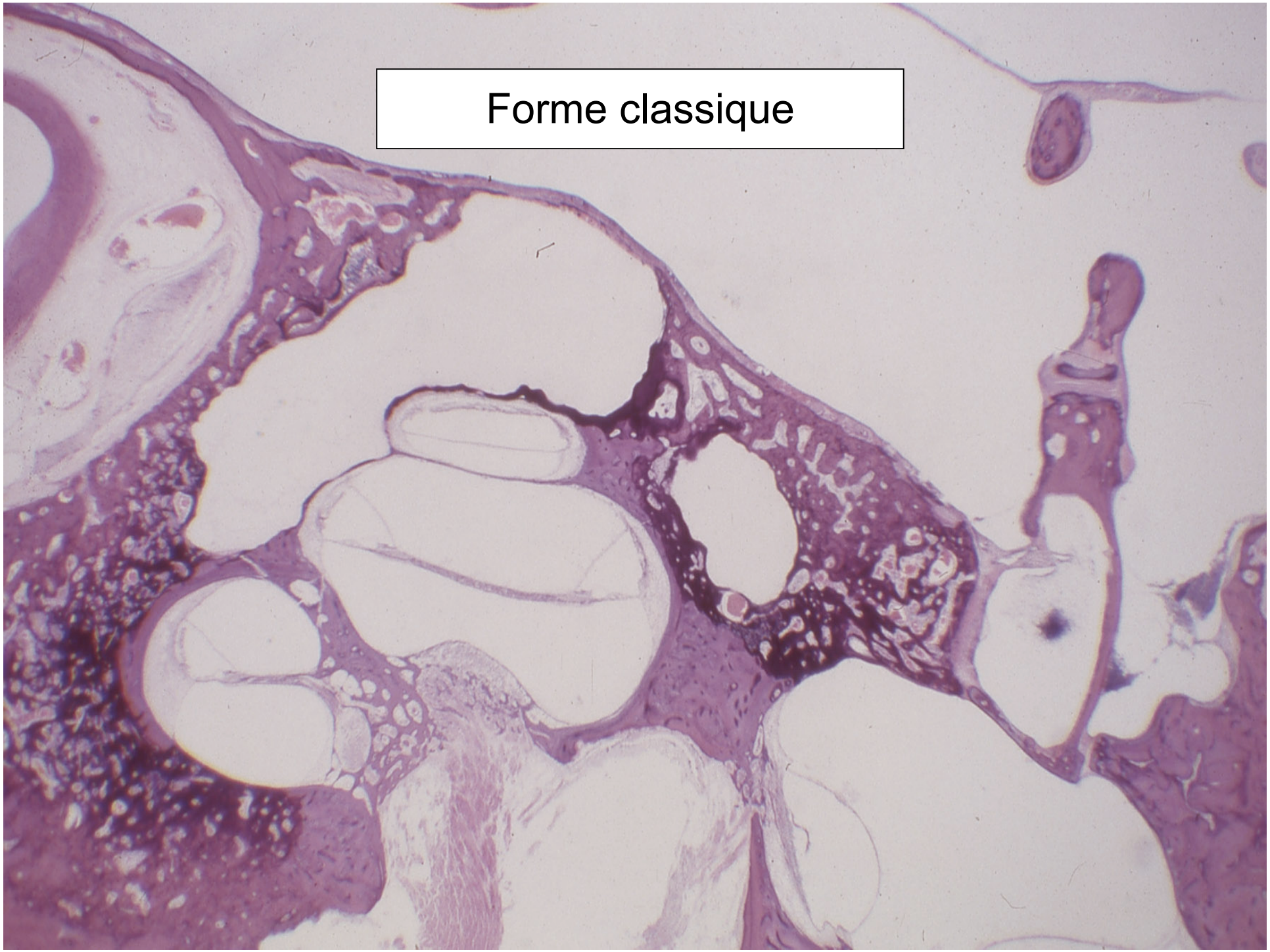
Forme classique

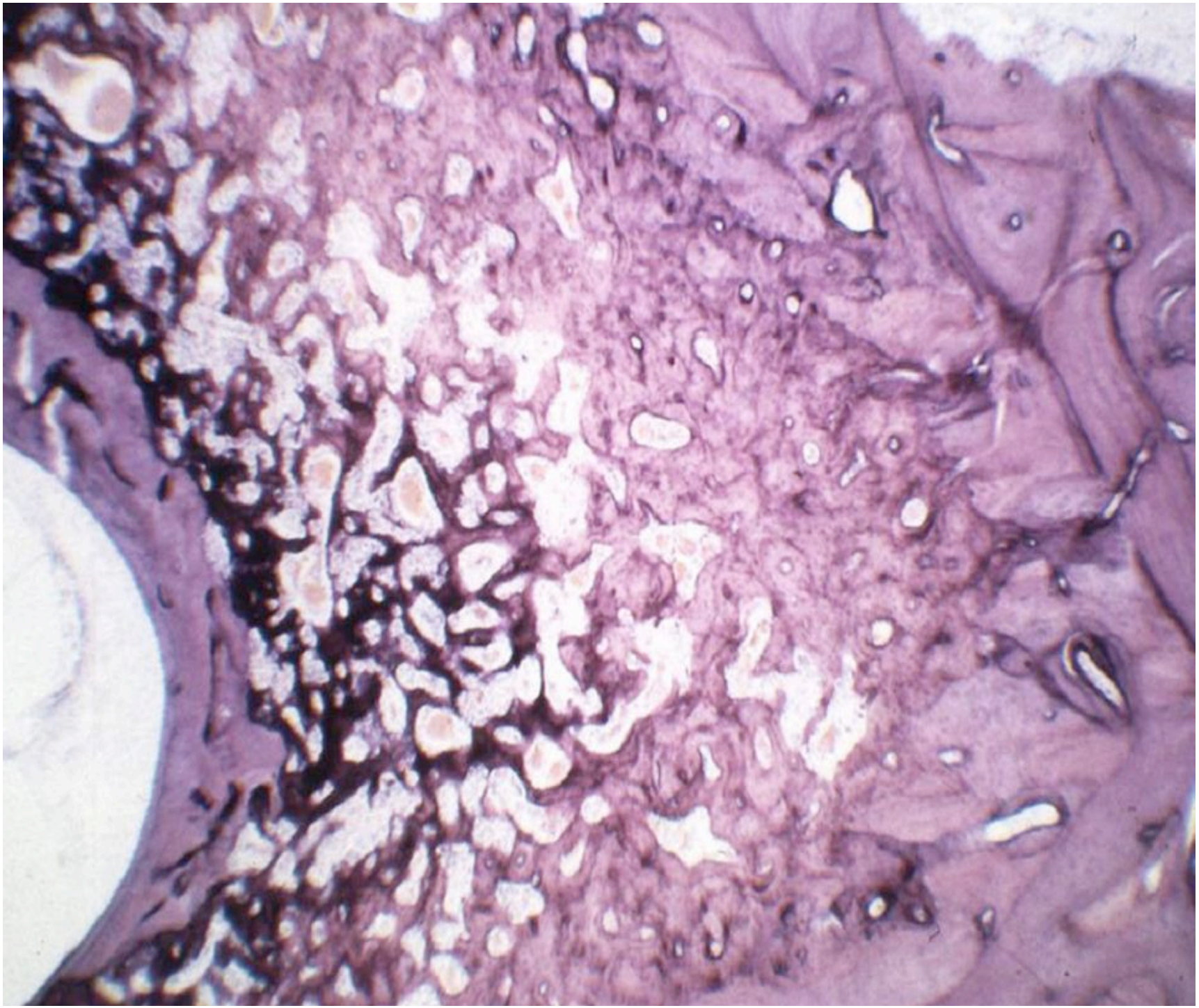

Forme extensive

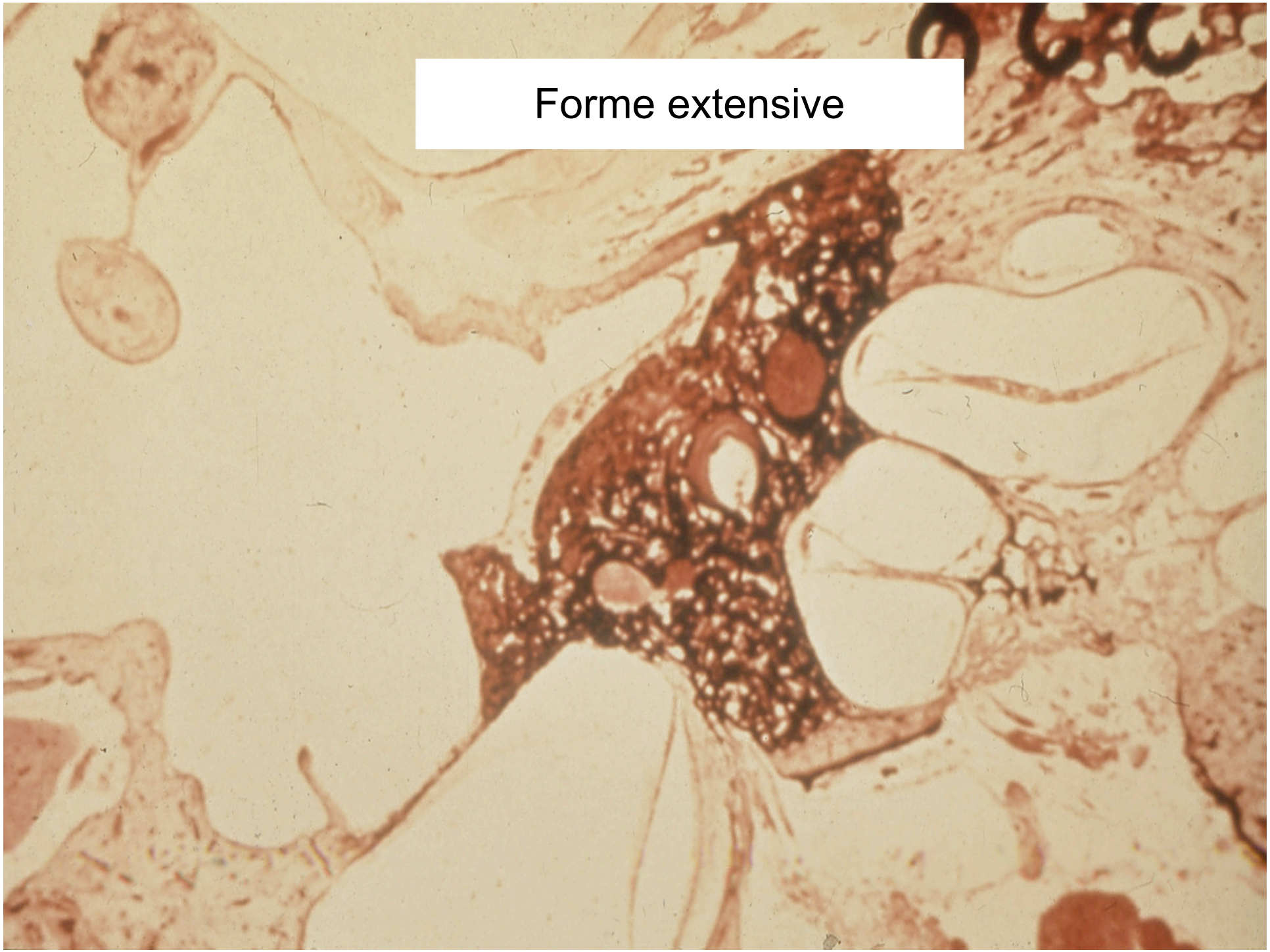

Forme péri-cochléaire

OTOSPONGIOSE
ET SURDITE NEUROSENSORIELLE

- Quelles lésions peuvent-elles expliquer la surdité neurosensorielle ?

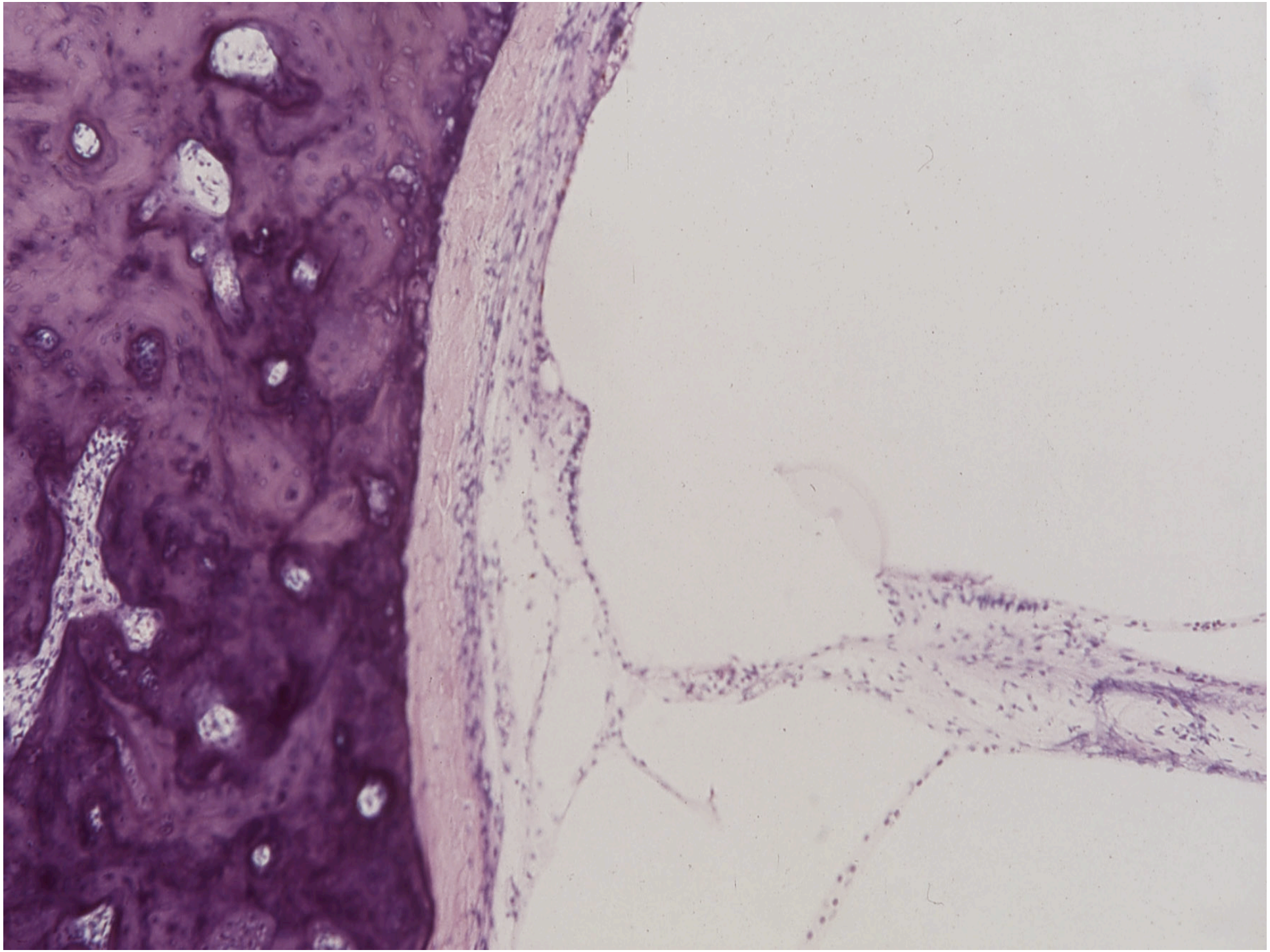

OTOSPONGIOSE MALIGNE

SCHUKNECHT

Définition

Envahissement des deux fenêtres avec oblitération de la *scala tympani* par de nouvelles formations osseuses

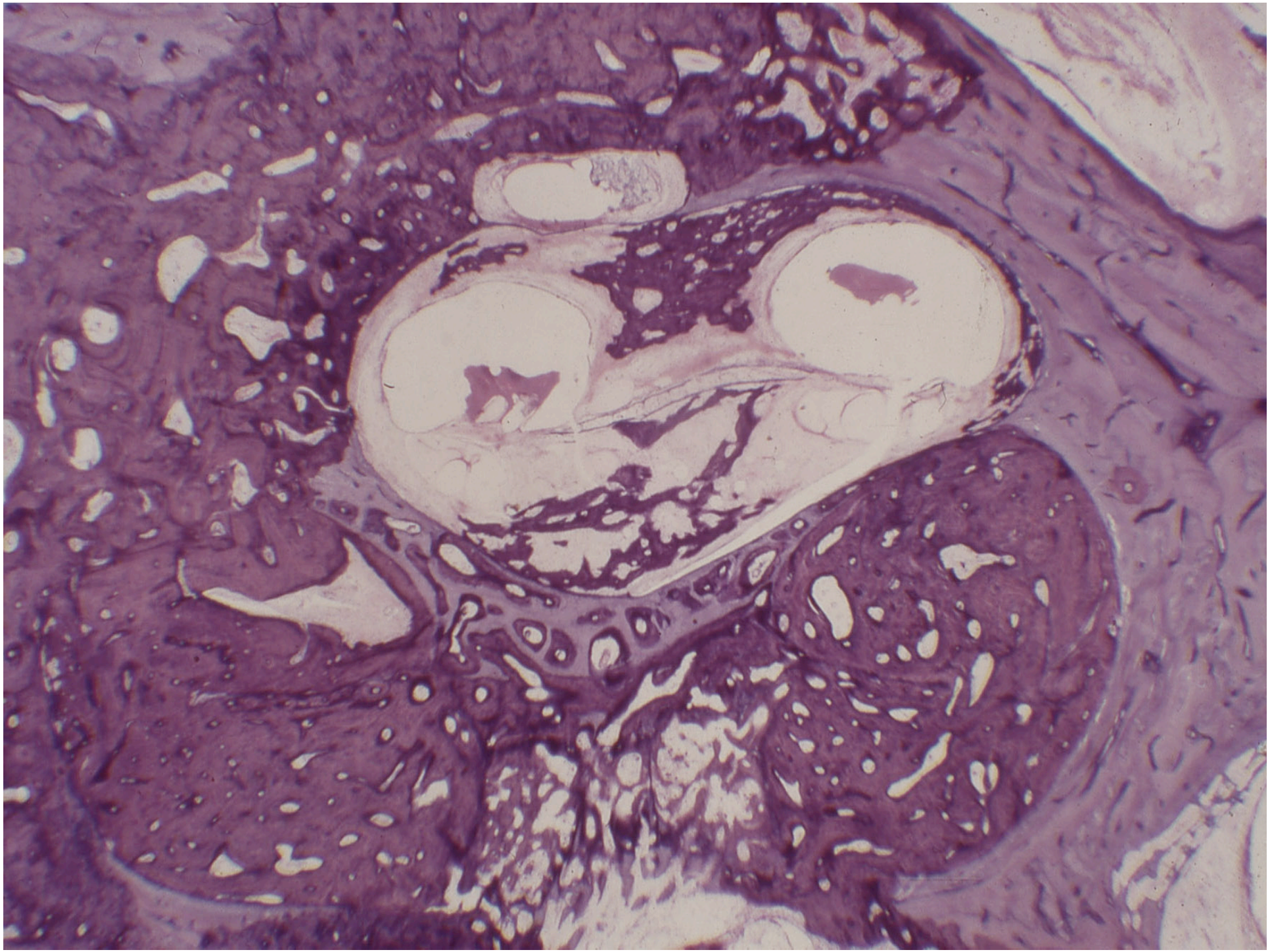

OTOSPONGIOSE COCHLEAIRE PURE

- Surdité neurosensorielle sans fixation stapédienne très rare

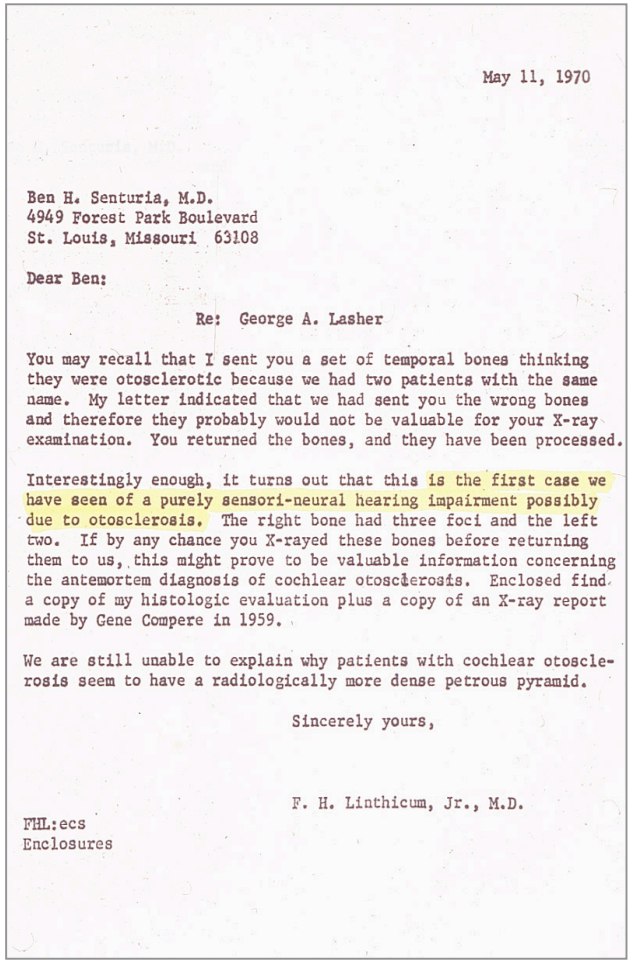

May 11, 1970

Ben H. Senturia, M.D.
4949 Forest Park Boulevard
St. Louis, Missouri 63108

Dear Ben:

Re: George A. Lasher

You may recall that I sent you a set of temporal bones thinking they were otosclerotic because we had two patients with the same name. My letter indicated that we had sent you the wrong bones and therefore they probably would not be valuable for your X-ray examination. You returned the bones, and they have been processed.

Interestingly enough, it turns out that this is the first case we have seen of a purely sensori-neural hearing impairment possibly due to otosclerosis. The right bone had three foci and the left two. If by any chance you X-rayed these bones before returning them to us, this might prove to be valuable information concerning the antemortem diagnosis of cochlear otosclerosis. Enclosed find a copy of my histologic evaluation plus a copy of an X-ray report made by Gene Compere in 1959.

We are still unable to explain why patients with cochlear otosclerosis seem to have a radiologically more dense petrous pyramid.

Sincerely yours,

F. H. Linthicum, Jr., M.D.

FHL:ecs
Enclosures

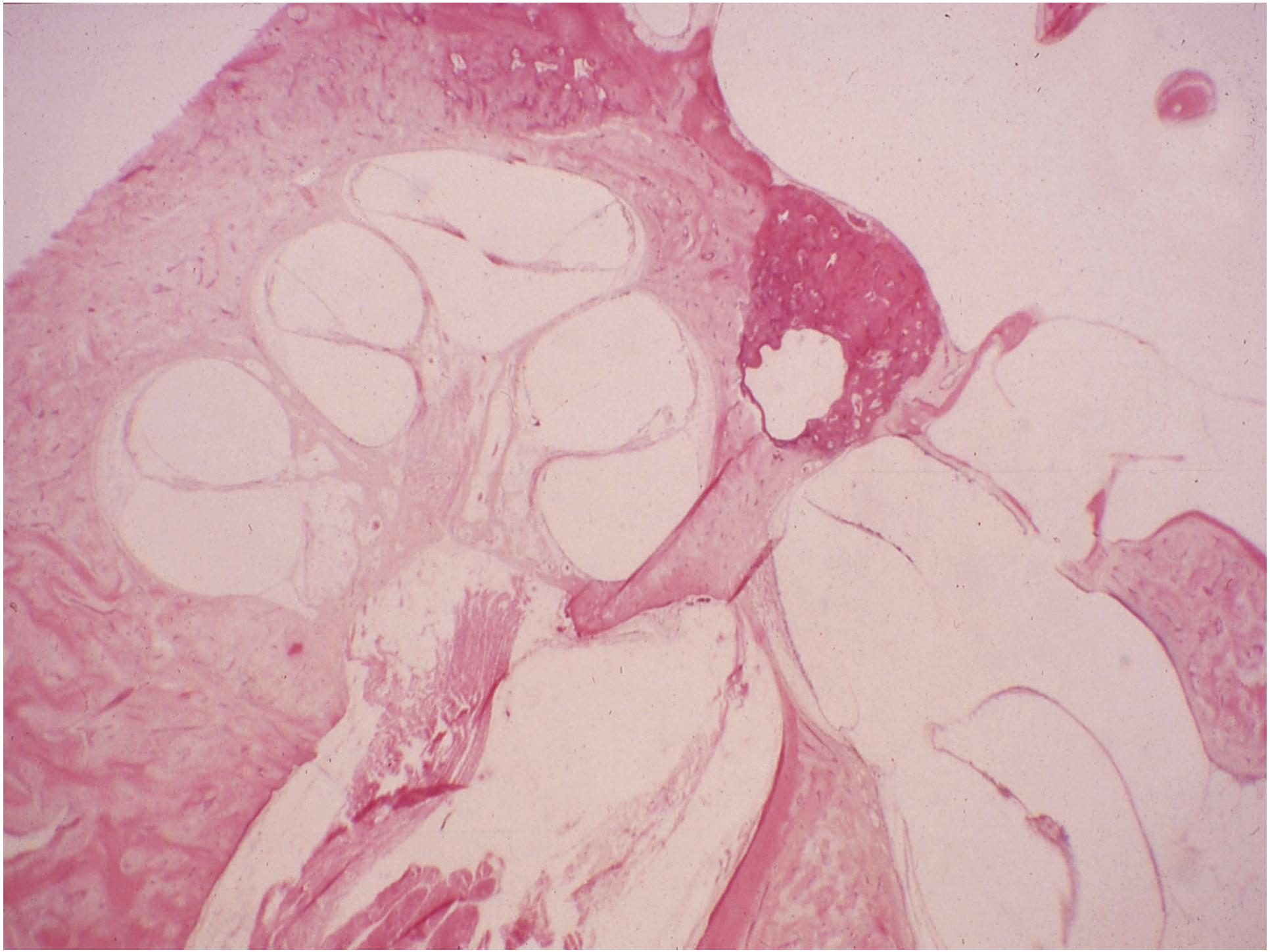

QUAND ET POURQUOI DEMANDER UN SCANNER

- Confirmer le diagnostic notamment dans les cas douteux
- Préciser la localisation et l'extension des lésions
- Évaluer les conditions anatomiques de la chirurgie
- Évaluer l'oreille controlatérale
- Confirmer la cause d'un échec chirurgical

INTÊRET DU SCANNER

- **Confirmer le diagnostic**
- Préciser la localisation des lésions
- Evaluer les conditions anatomiques
- Evaluer l’état de l’oreille controlatérale
- Confirmer la cause d’un échec chirurgical

SCANNER POSITIF

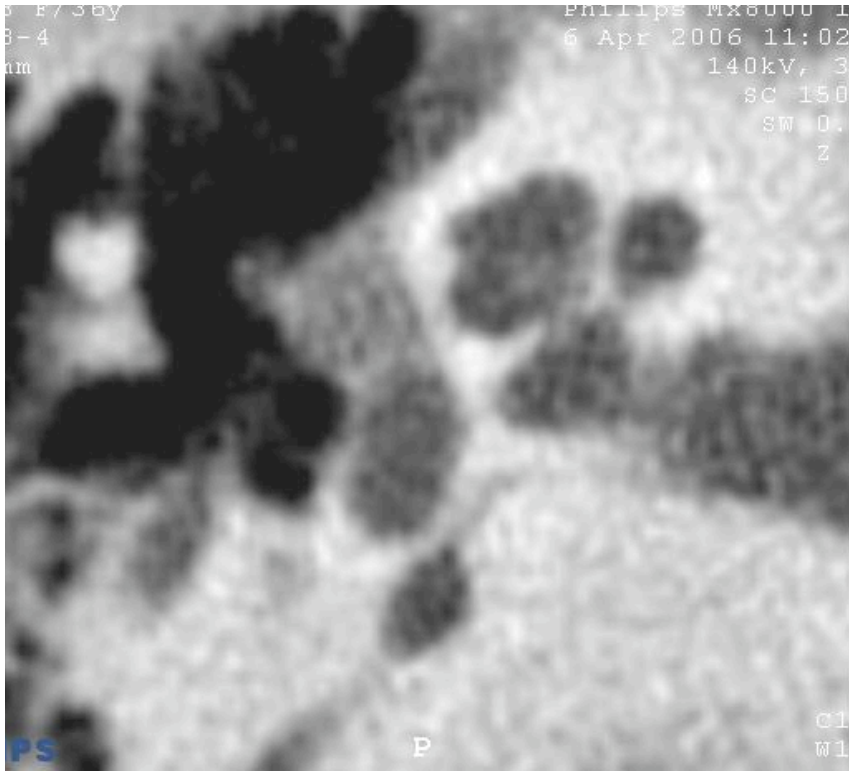

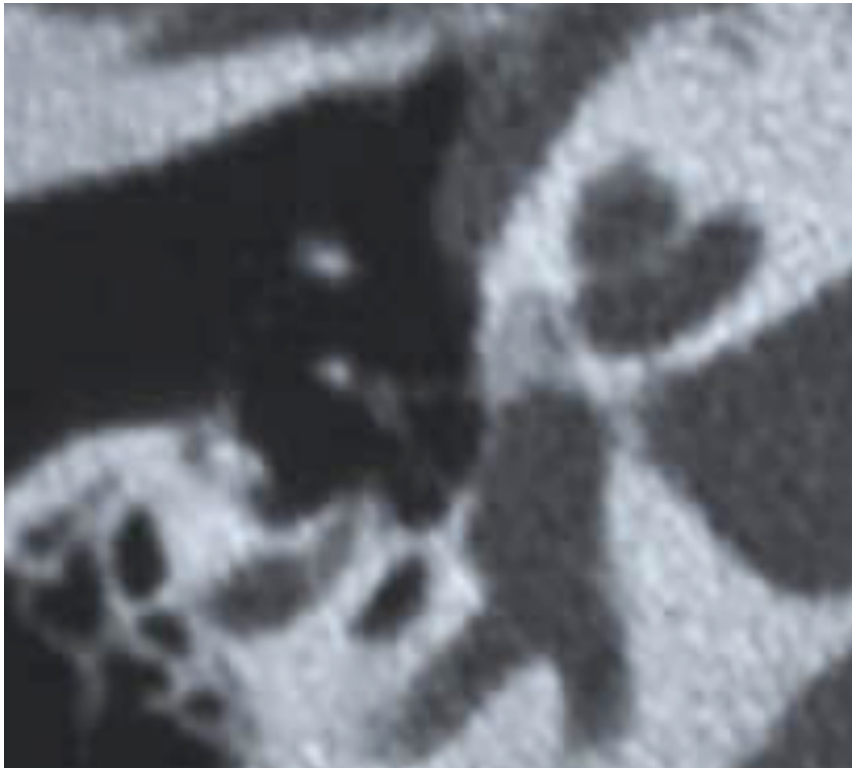

- Hypodensité
- Otospongiose - otosclérose

SCANNER DOUTEUX

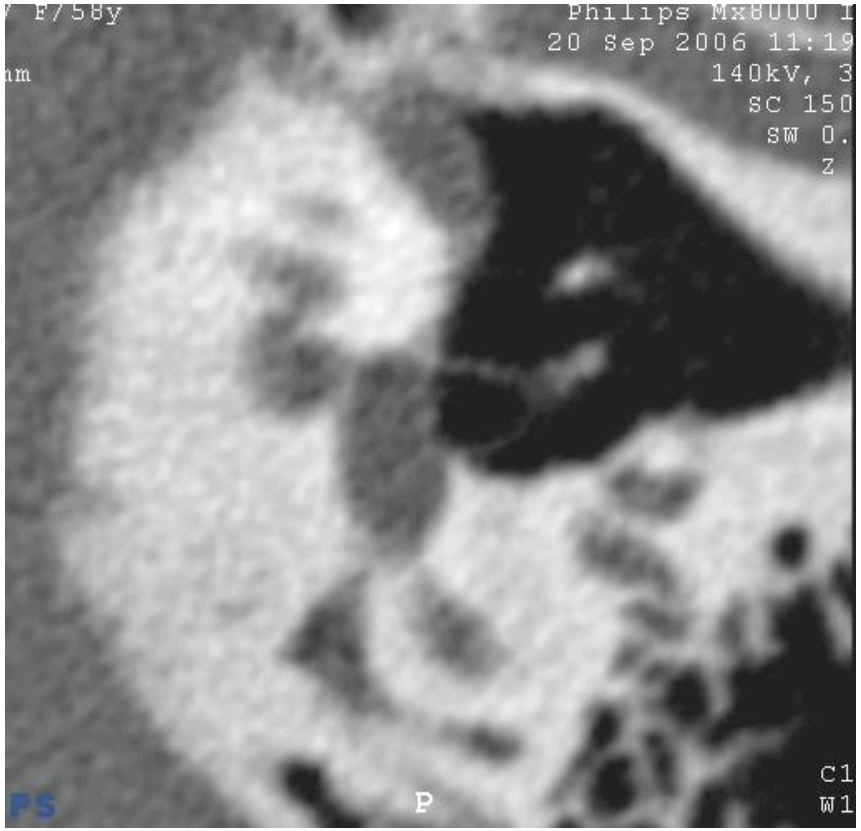

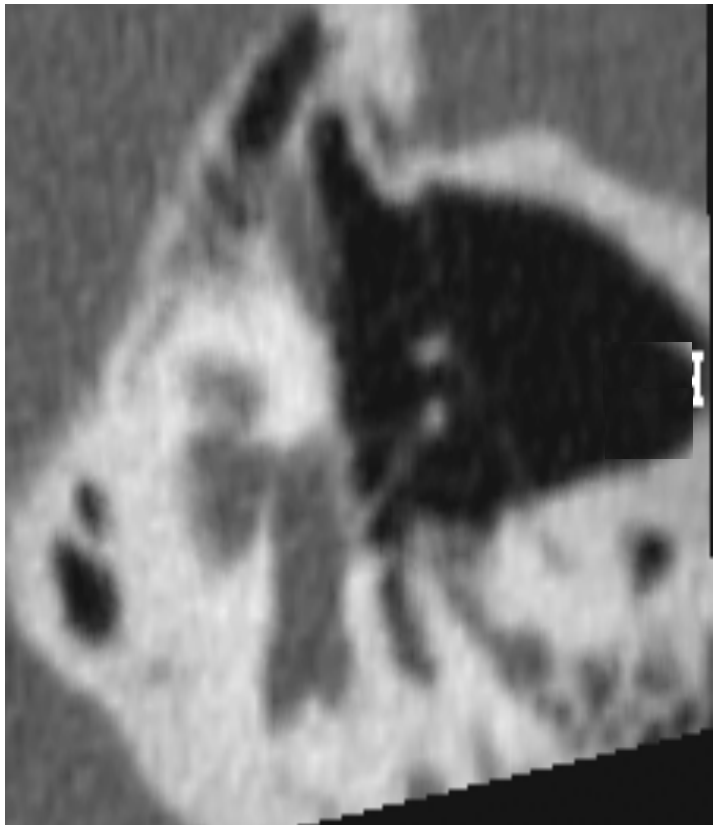

- Epaississement de la branche antérieure
- Epaississement de la platine

POPULATION

663 cas

❶ 1989-1999
Etude rétrospective

Acta Oto-Laryngol, 2001;121(2):200-204

❷ 2004-2006
Etude prospective

Otol Neurotol 2009

➔ **Fiabilité**

455 patients
69%

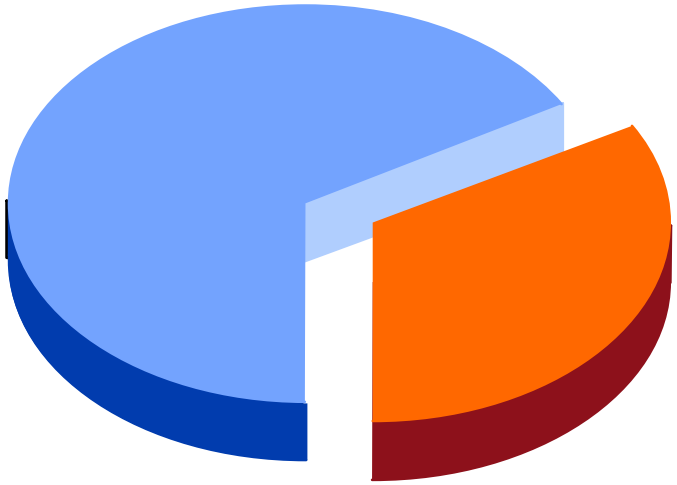

208 patients
31%

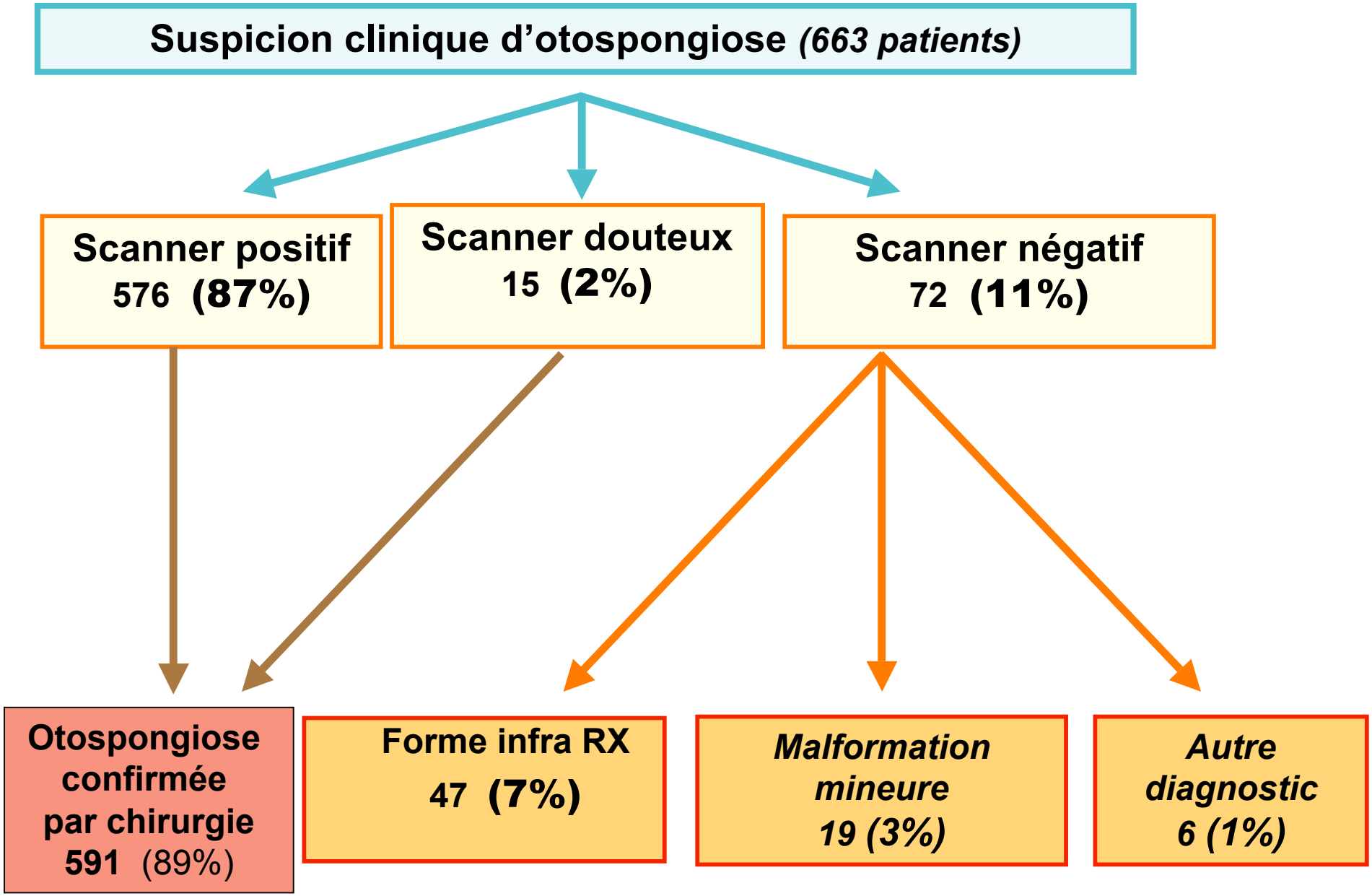

S. Lagleyre - Otol Neurotol

FIABILITE

	Série de 2001* ***(474 patients)***	**Série de 2006** ***(91 patients)***
Scanners positifs	84%	**92,5%**
Scanners douteux	-	**4.5%**
Scanners négatifs	16%	3%

**Shin et al. Acta Otolaryngol 2001; 121:200-204*

FORMES INFRARADIOLOGIQUES

47 patients

Définition

- **Scanner normal, mais présence d'un foyer révélé par la chirurgie**

Physiopathologie

- Forme récente avec une fixation incomplète de la platine

→ Plus grande possibilité d'être confronté une platine mobile au cours de la chirurgie *(p=0.04)*

AUTRES DIAGNOSTICS

6 patients

- **Définition :**
  - **Scanner normal sans foyer chirurgical et chaîne mobile**

Physiopathologie :
Possible surdité de transmission de l'oreille interne

- Large aqueduc du vestibule
- Large foramen cochléaire
- Déhiscence du canal supérieur

SURDITE DE TRANSMISSION DE L'OREILLE INTERNE

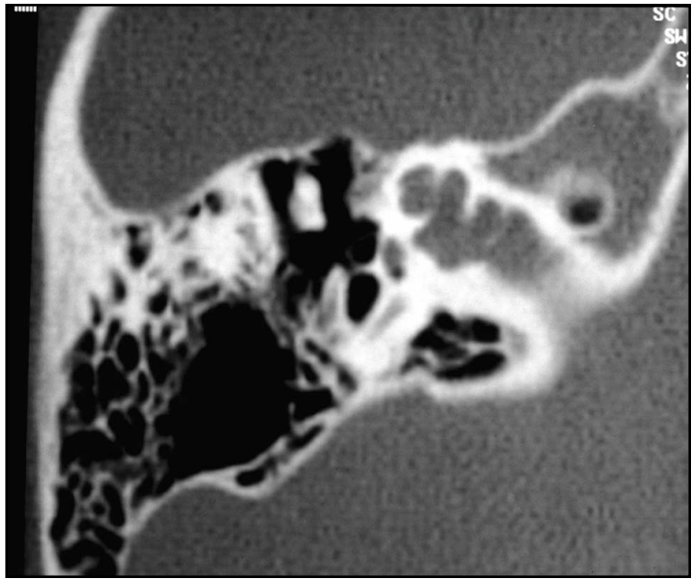

▲ Large foramen cochléaire ▲

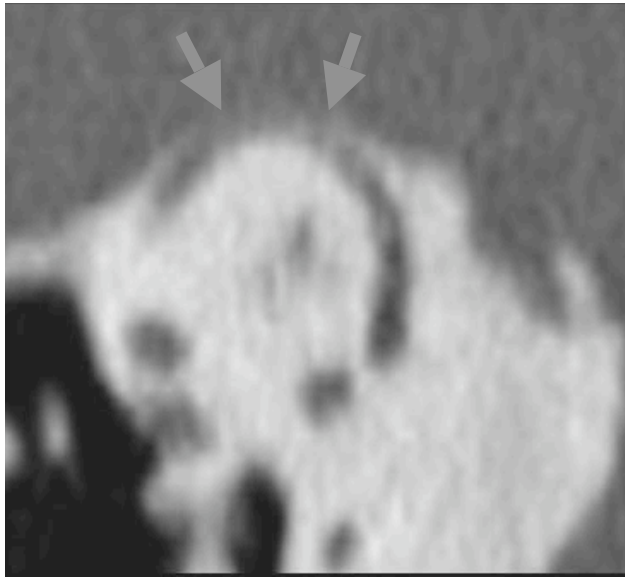

▲ Déhiscence ▲
du canal supérieur

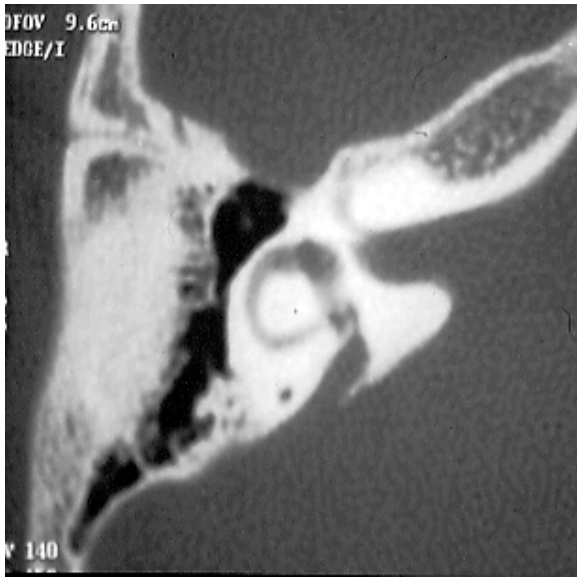

▲ Large aqueduc ▲
vestibulaire

INTÊRET DU SCANNER

- Confirmer le diagnostic
- **Préciser la localisation des lésions**
- Evaluer les conditions anatomiques
- Evaluer l'état de l'oreille controlatérale
- Confirmer la cause d'un échec chirurgical

Localisation classique

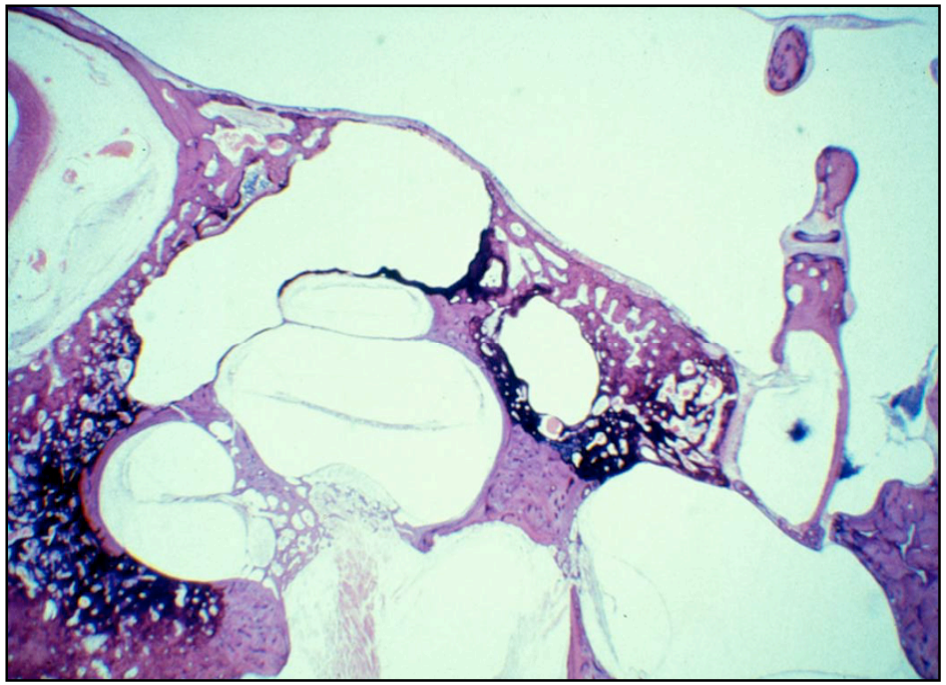

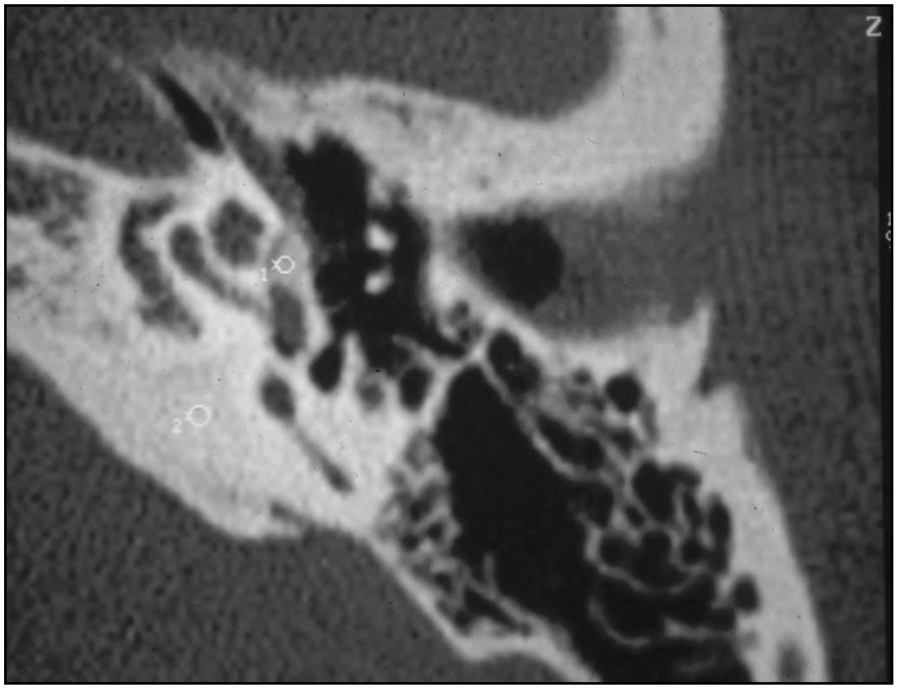

Foyers péri-cochléaires

Acta Otolaryngol 2001; 121: 200–204

Sensorineural Hearing Loss and Otosclerosis: A Clinical and Radiologic Survey of 437 Cases

YOUNG JE SHIN[1], BERNARD FRAYSSE[1], OLIVIER DEGUINE[1], CHRISTOPHE COGNARD[2], JEAN-PAUL CHARLET[3] and ANNICK SÉVELY[2]

From the [1]Departments of Otolaryngology and [2]Neuroradiology, Purpan Hospital, Toulouse, France and [3]Department of Epidemiology, Hôtel-Dieu Saint Jacques, Toulouse, France

Extension à l'endoste ou oblitération de la fenêtre ronde

- Responsable d'une atteinte préopératoire plus importante de la conduction osseuse *($p < 0.05$)*
- Risques de surdité neurosensorielle postopératoire sont plus élevés *($p < 0.09$)*

Types d'atteinte

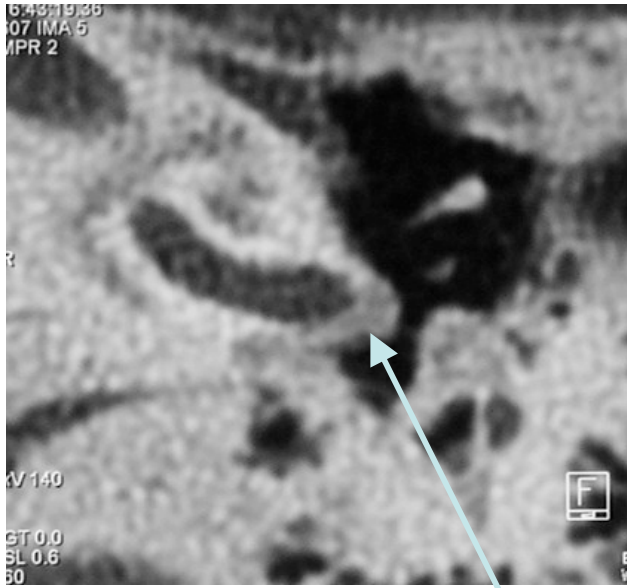

Hypodensité du mur de la FR

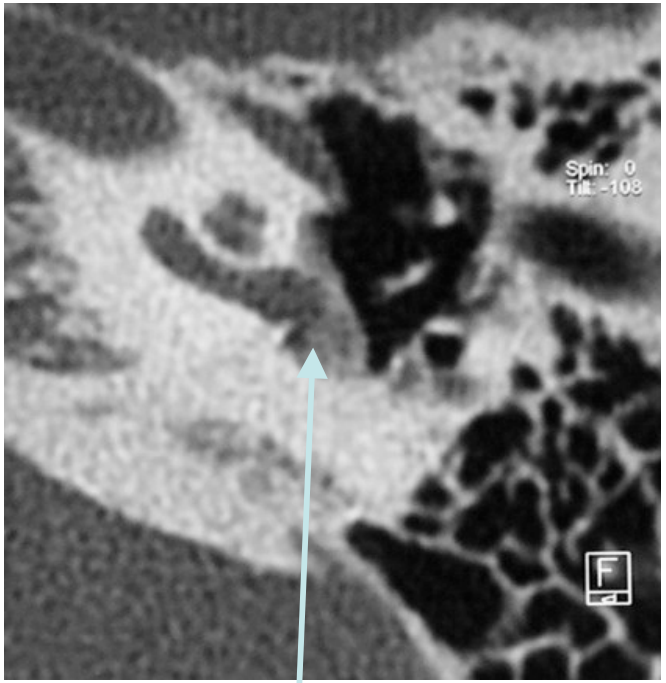

Obstruction complète

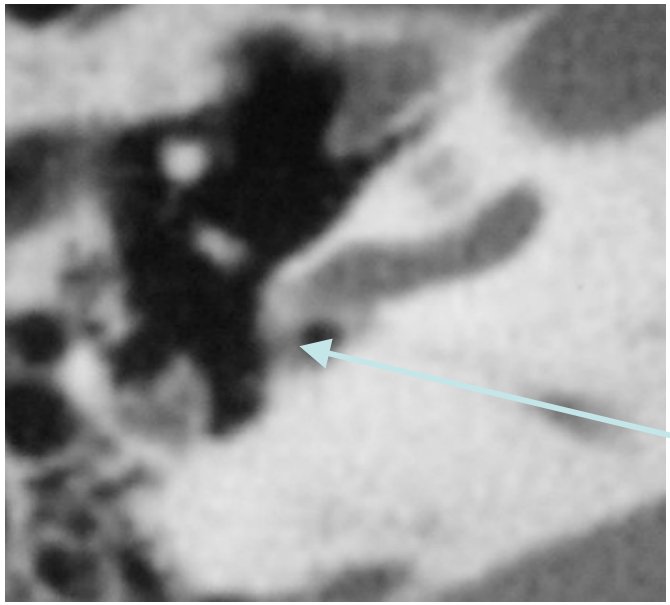

Pont otospongieux

INTÊRET DU SCANNER

- Confirmer le diagnostic
- Préciser la localisation des lésions
- **Evaluer les conditions anatomiques**
- Evaluer l'état de l'oreille controlatérale
- Confirmer la cause d'un échec chirurgical

Rechercher une anomalie anatomique

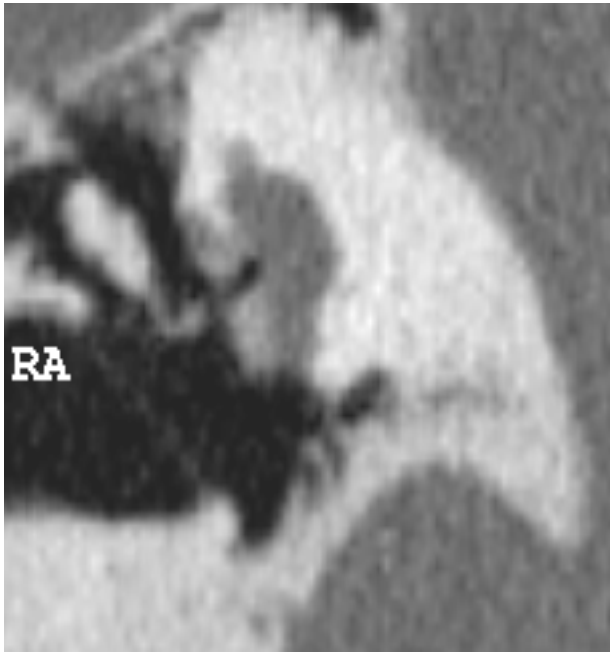

Fenêtre étroite

Facial déhiscent

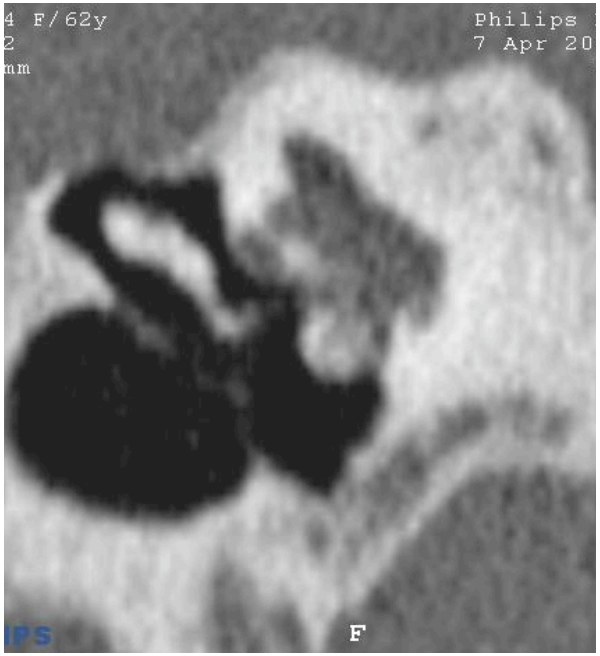

Oblitération platine

INTÊRET DU SCANNER

- Confirmer le diagnostic
- Préciser la localisation des lésions
- Evaluer les conditions anatomiques
- **Evaluer l'état de l'oreille controlatérale**
- Confirmer la cause d'un échec chirurgical

ETAT DE L'OREILLE CONTROLATERALE

200 CAS

AUDITION		SCANNER		
• Audition normale	▶ 69 cas	Foyer négatif	▶ 27 cas	13.5 %
		Foyer positif	▶ 32 cas	16 %
		Foyer douteux	▶ 10 cas	5 %
• Surdité de perception pure	▶ 51 cas	Foyer endostéal	▶ 16 cas	8 %
• Surdité de transmission	▶ 80 cas	Foyer stapédien	▶ 80 cas	40 %

INTÊRET DU SCANNER

- Confirmer le diagnostic
- Préciser la localisation des lésions
- Evaluer les conditions anatomiques
- Evaluer l'état de l'oreille controlatérale

▶ **Confirmer la cause d'un échec chirurgical**

ECHEC CHIRURGICAL

59 patients

Prothèse en place, pas de foyer	**18**	30%
Syndrome de latéralisation	**8**	14%
Déplacement de la prothèse	**20**	34%
Fixation du marteau	**4**	7%
Prothèse intra-vestibulaire	**4**	7%
Ré-ossification	**5**	8%

Prothèse en place; pas de foyer

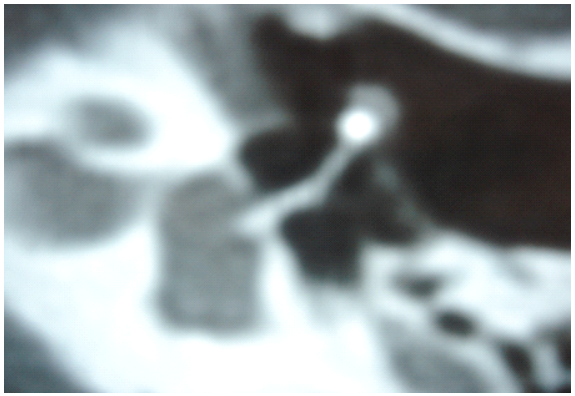

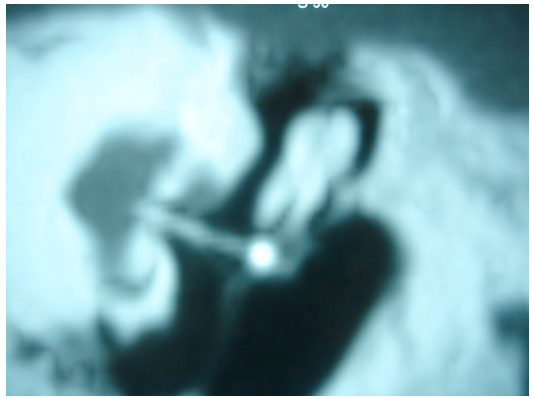

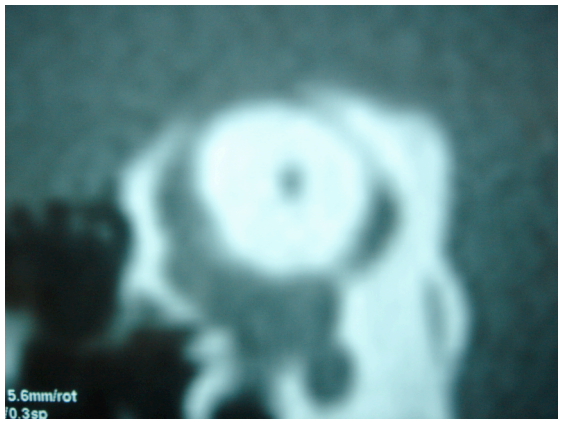

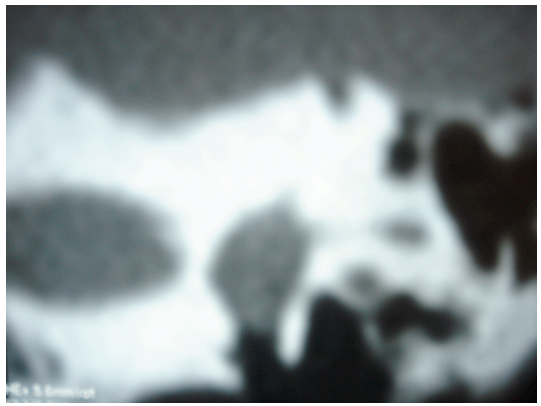

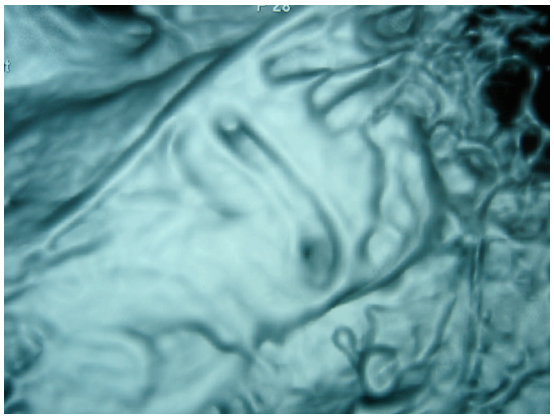

Syndrome de latéralisation

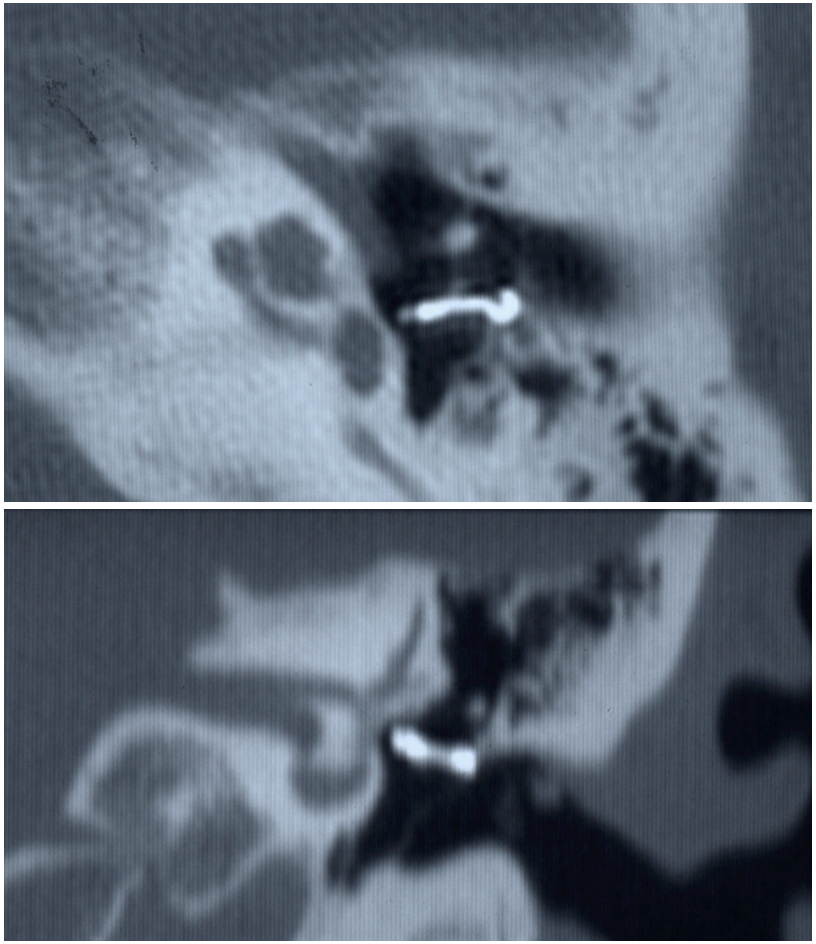

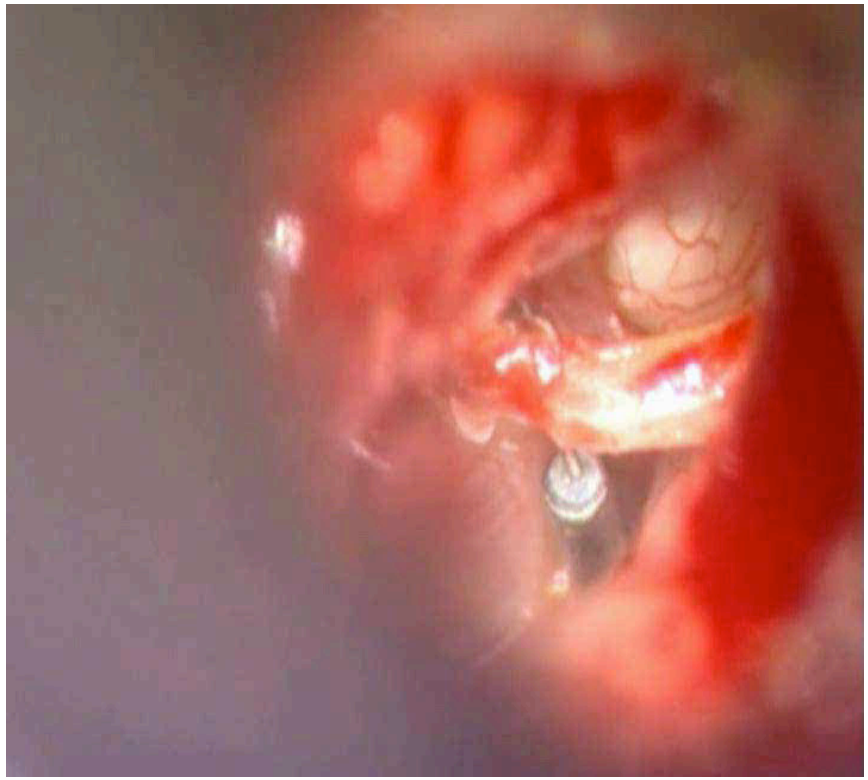

Ankylose de la tête du marteau

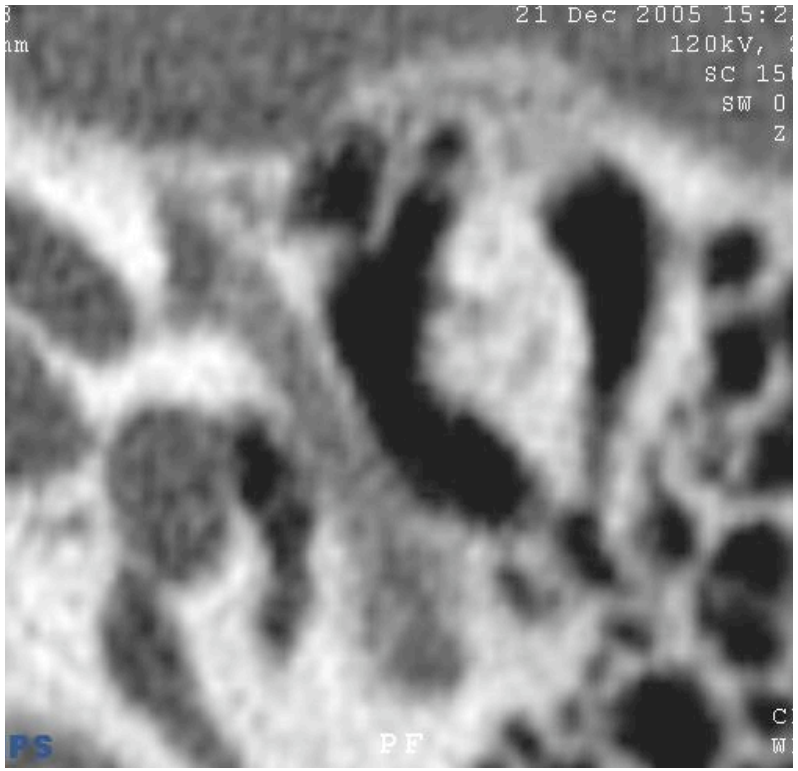

Fixation de l’enclume

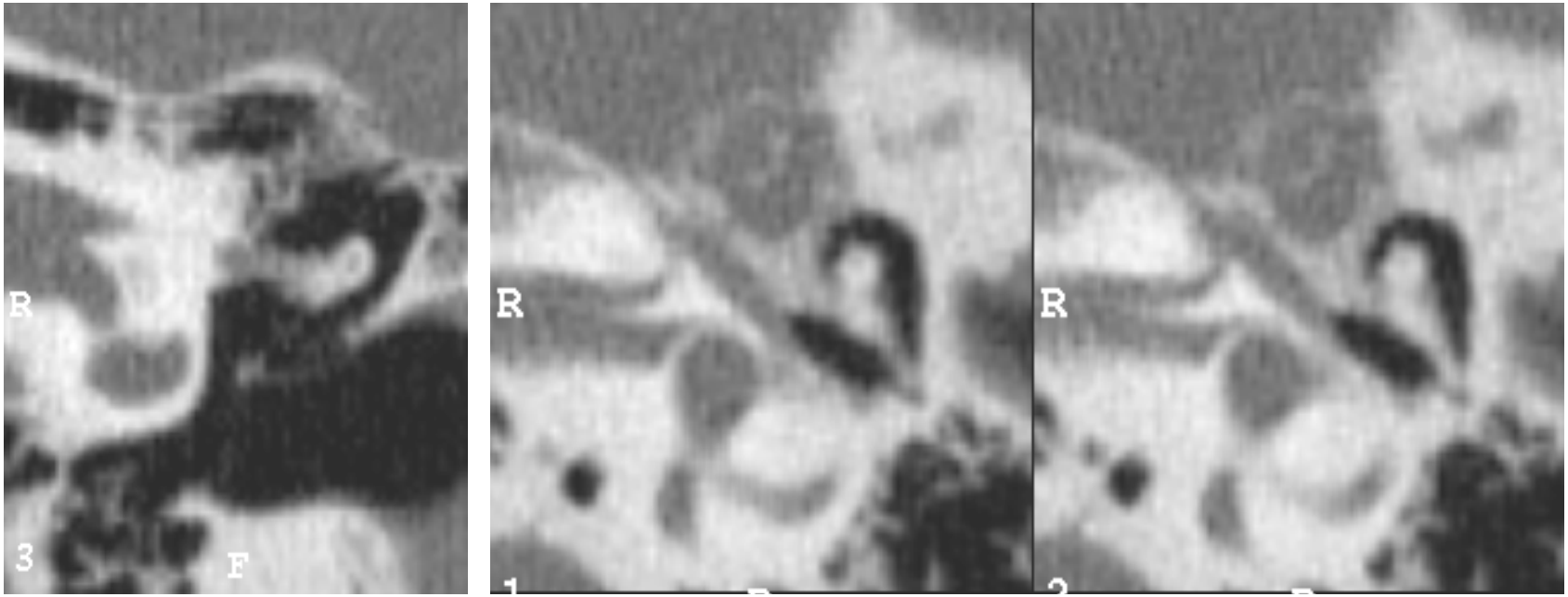

Prothèse intra-vestibulaire

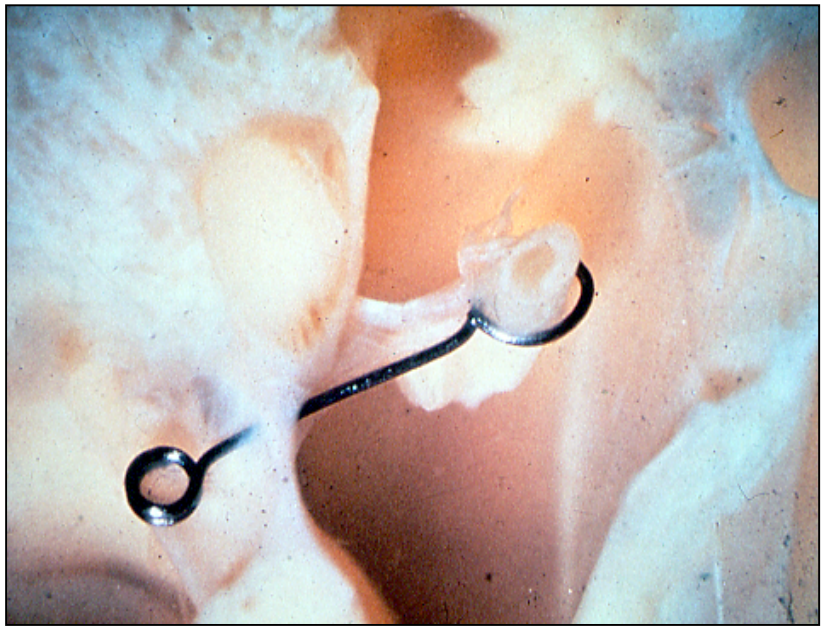

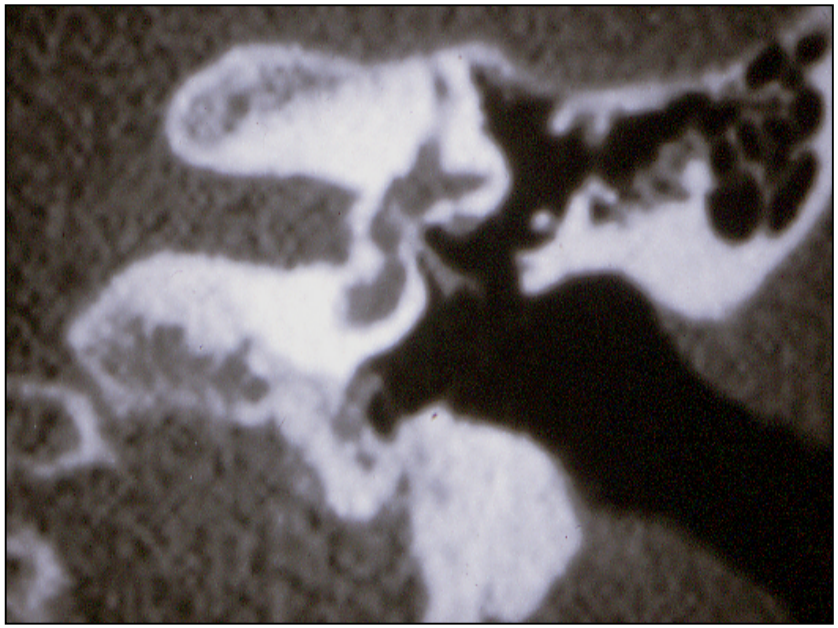

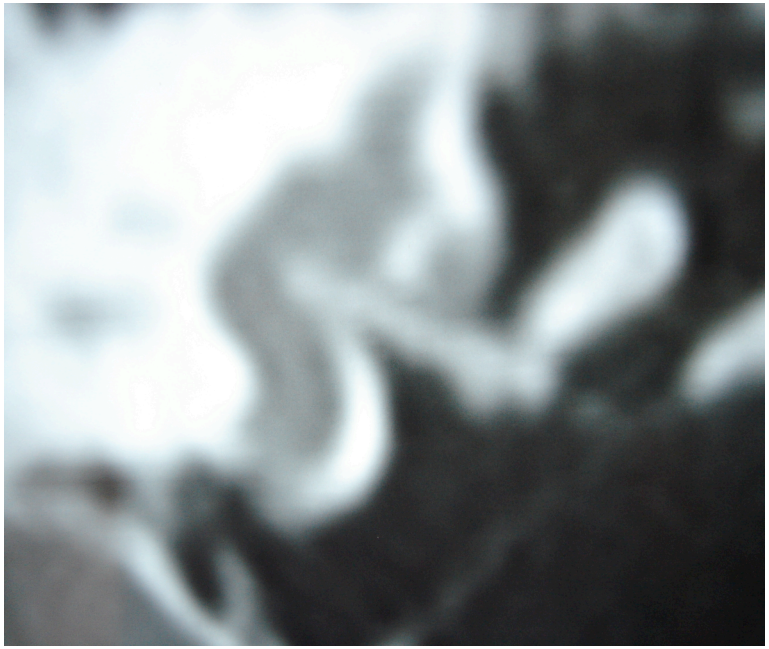

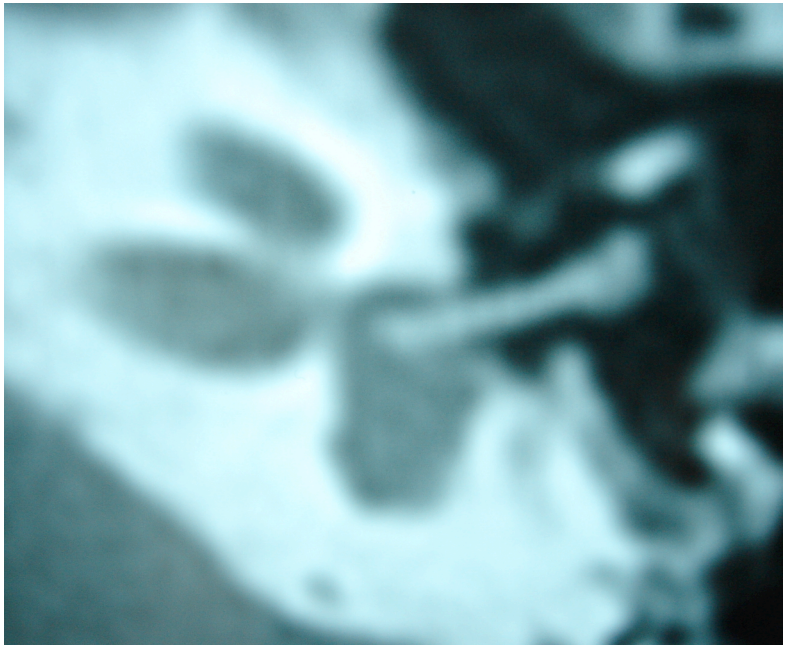

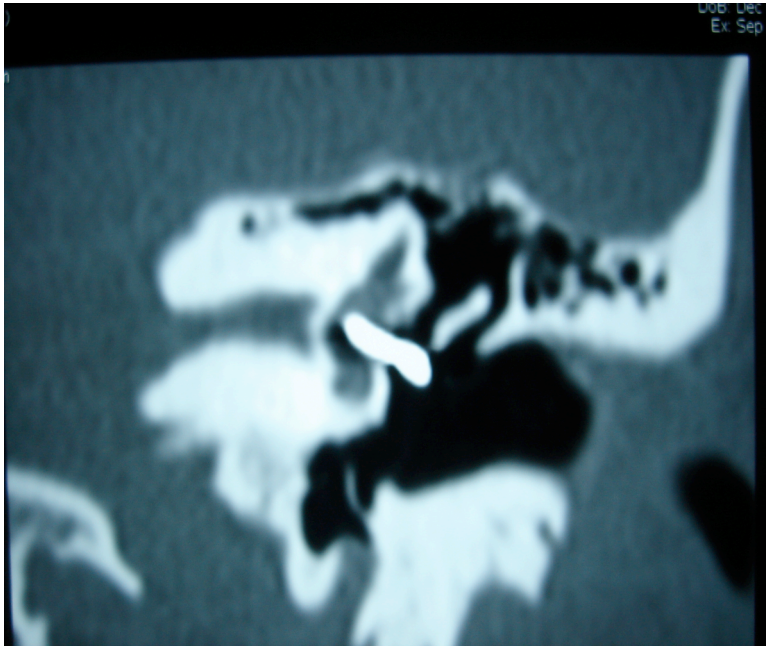
Ex: Sep

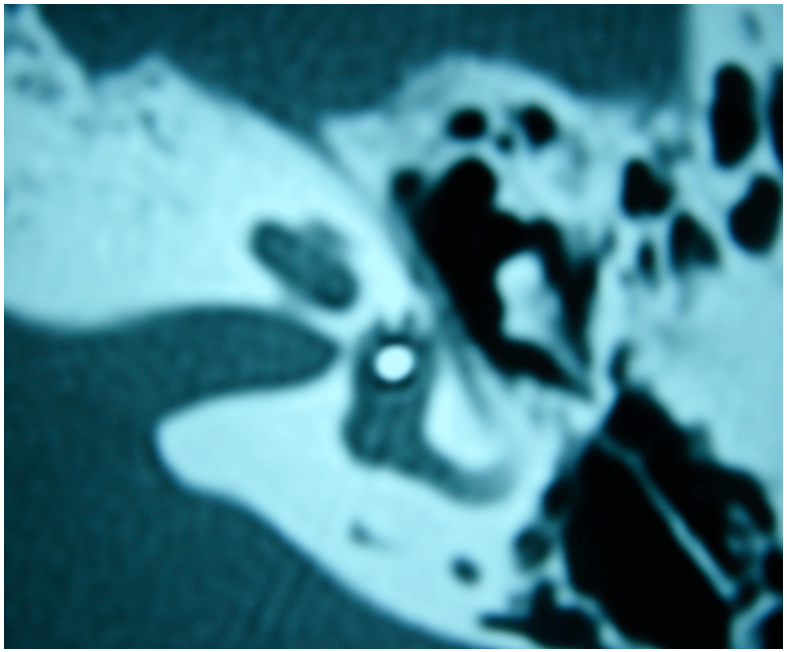

Réossification de la fenêtre ovale

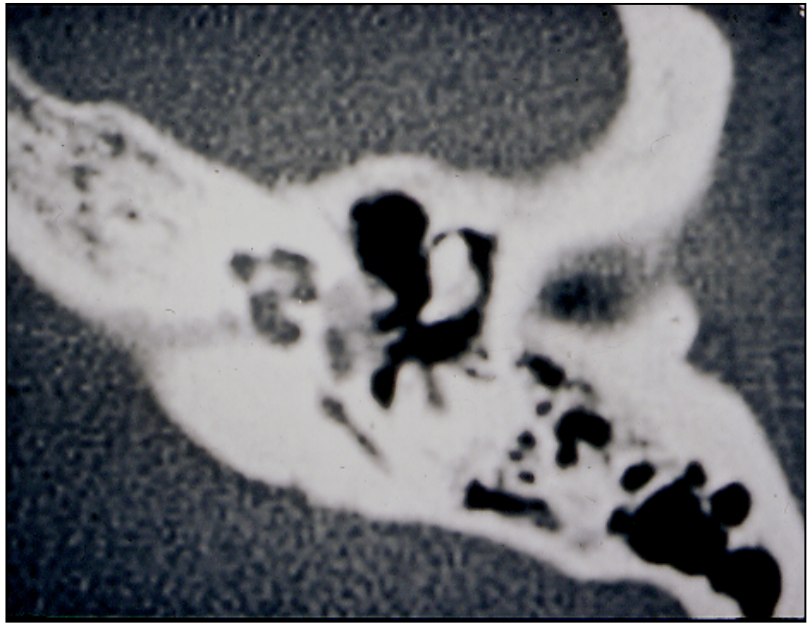

SCANNER SYNTHESE

1

- L'indication du scanner est systématique, sauf dans les formes cliniques complètes *(12 %)*

- La localisation du foyer a une répercussion sur les résultats chirurgicaux *(fenêtre ronde, extension à l'endoste)*

SCANNER SYNTHESE

2

è Quand le scanner est normal, la technique chirurgicale doit être particulièrement méticuleuse

è En cas d' échec chirurgical, le scanner confirme le diagnostic et la cause de l' échec

Recommandation:
Surdités de transmission à tympan normal
SF ORL 2007

Situation clinique	Imagerie systématique	Imagerie indiquée de façon sélective
ST de l'adulte	TDM en préopératoire	TDM en fonction du tableau clinique
Échec fonctionnel après chirurgie SV	TDM	

Merci de votre attention